

**DATE PRESENTING CLINICAL SIGNS**

8/10/22

Cat presented for incontinence. (on many meds for thyroid- kidneys and on amlodipine for BP) O reports p is drinking more water and urinating more. u/a- nsf except dilute urine and epi cells, bladder rads shows mineralization at bladder.

PATIENT

Malach Miller

Current Medications: amlodipine 2.5 mg- 1/4 tab sid, methimazole- 5 mg- 3/4 in am and 1 in pm, cerenia - 16mg- 1/2 sid, mirataz - 1/2 inch transdermal eod.

Date of Previous IntraPet Ultrasound: No previous.

Sedation: Not required to complete full diagnostic ultrasound.

Stat Report: Not requested.

Imaging Performed By: Andi Parkinson BS, RDMS

SPECIES

Feline

BREED

Domestic shorthair

ULTRASONOGRAPHIC EXAMINATION OF THE ABDOMEN**Urinary System**

The urinary bladder is moderately distended. An approximately 3.5 cm irregular heterogeneous mineralized mass is observed in the caudal aspect. The mass occupies approximately 50% of the bladder lumen in its current state of repletion. The remaining bladder wall is normal in thickness with a smooth mucosal surface. A small amount of suspended echogenic debris is observed within the lumen. No cystic calculi are observed. The proximal urethra appears normal to slightly thickened (up to 0.18 cm) and is not overtly dilated.

SEX

Male, neutered

AGE

6/14/2002

The left kidney is normal size (3.66 cm in length); normal shape and architecture with smooth peripheral margins. There is a normal 1:3 cortex to medulla ratio with moderate loss of corticomedullary distinction. Moderate pyelectasia is present (0.38 cm in the longitudinal plane). There is no evidence of nephroliths, infarcts or hydronephrosis.

WEIGHT

8.4 lbs.

The right kidney is normal in size (3.41 cm in length) with a normal shape, smooth peripheral margins and normal internal architecture. There is mild to moderate loss of corticomedullary distinction. Several hyperechoic shadowing diverticular foci are observed. There is no evidence of pyelectasia, infarcts or hydronephrosis.

INTERPRETED BY

Andrea Nicastro, DVM,
 Diplomate ACVIM
 (Small Animal Internal
 Medicine)

Adrenal Glands

The region of the adrenal glands is evaluated. No obvious pathology is observed.

HOSPITAL NAME

Pet Vet Clarksville

Spleen

The spleen is normal in size (0.74 cm in width at the level of the hilus) with a normal capsular contour. There is appropriate echogenicity and echotexture. No focal lesions are observed. Splenic vasculature is normal.

REFERRING VET

Dr. Martof

Liver

The liver is subjectively normal in size with normal contours and structure. There is appropriate echogenicity and echotexture. No overt structural evidence of inflammatory, infiltrative or regenerative pathology is evident. Vascular and biliary tracts are of normal volume with no evidence of congestion. No pathological hepatic lymphadenopathy observed. The gall bladder lumen is moderately distended. The wall is thin and smooth. A small amount of echogenic debris is observed within the lumen. The cystic and common bile ducts are normal.

INVOICE

13815

Gastrointestinal

The stomach and intestine are free of stasis and exhibit normal peristaltic activity. The gastric lumen is not distended. The gastric wall and pylorus are normal in thickness with a normal layering pattern. The pyloric outflow tract is patent. The small intestinal lumen is not dilated. The small intestinal wall is diffusely thickened (up to 0.4 cm) with retention of the normal layering pattern and appropriate mural detail. There is

disruption in the normal 1:3 muscularis: mucosal ratio with a >1:1 ratio in most segments. Discreet masses are not identified. The ileocecal colic junction and colonic wall are normal. No obstructive disease is noted.

Pancreas

The region of the pancreas is isoechoic relative to surrounding omental fat. No obvious parenchymal abnormalities are observed. There is no evidence of regional inflammation or effusion.

Free Abdomen

Trace free fluid is visualized. The mesentery in the mid-abdominal region is hyperechoic. The abdominal lymph nodes are normal/not visible.

ULTRASONOGRAPHIC FINDINGS

Primary Findings:

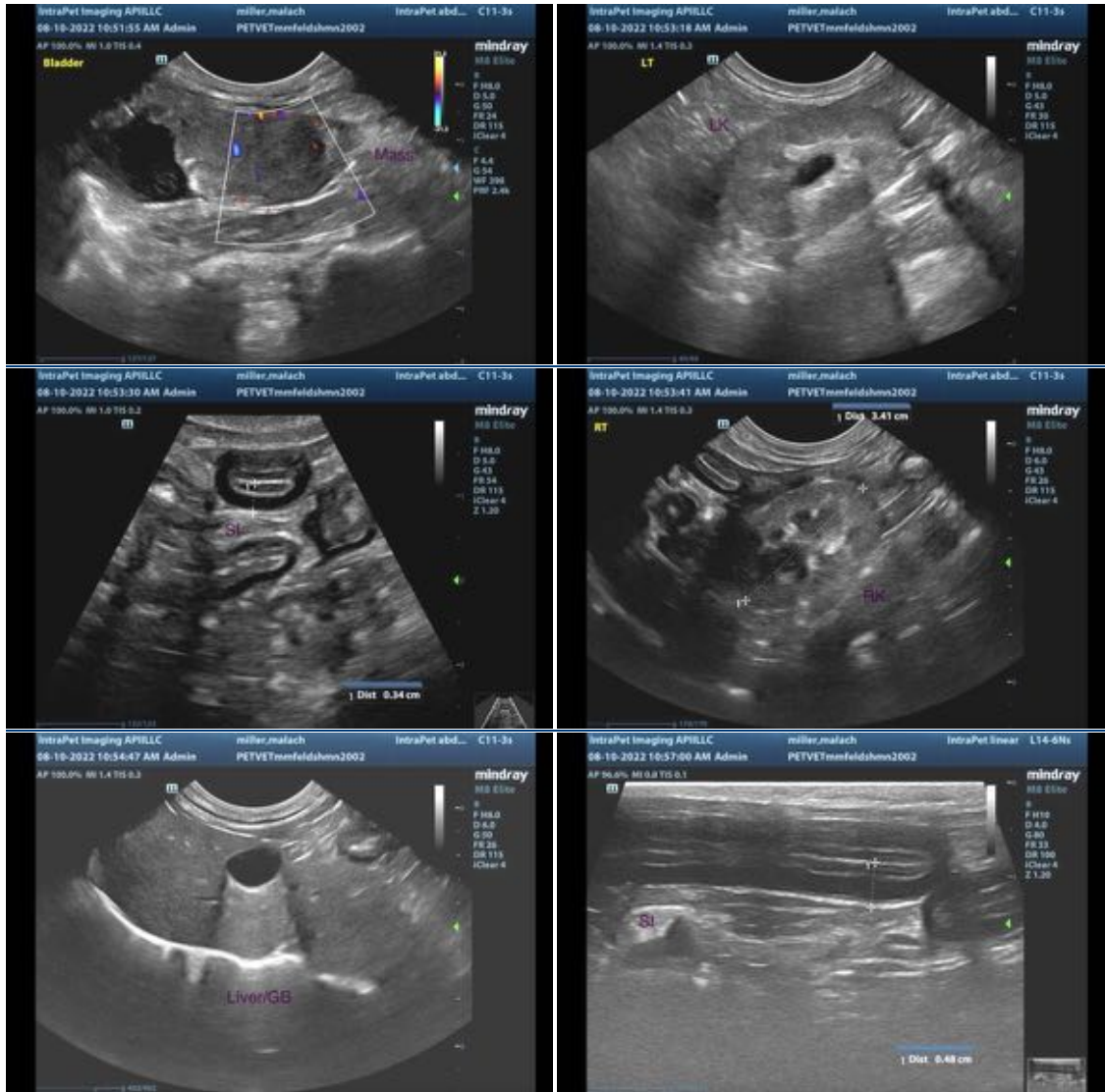
- Large caudal urinary bladder mass. Neoplasia (i.e., transitional cell carcinoma) is suspected with a low possibility of a benign inflammatory process. There is questionable extensive of pathology into the proximal urethra.

Secondary Findings:

- Bilateral chronic age-related renal changes. The left pyelectasia may be secondary to pyelonephritis, age-related remodeling, partial distal ureteral obstruction (due to the mass effect at the trigone), or some combination thereof.
- The small intestinal wall changes could be consistent with emerging lymphoma or inflammatory bowel disease.
- The trace ascites is likely secondary to bowel and/or urinary bladder pathology.

INTERPRETATION OF THE FINDINGS & FURTHER RECOMMENDATIONS

- A urine BRAF test is recommended to further evaluate for lower urinary tract neoplasia.
- Also consider three-view thoracic radiographs to assess for pulmonary metastatic disease.
- Regarding the small intestinal wall changes, a fecal evaluation for ova and Giardia and a malabsorption panel including serum cobalamin, folate, TLI and PLI can be considered.



The information and recommendations provided are based on the images presented by the referring veterinarian. No evaluation can be communicated regarding pathology that was not visible in the image/video clips provided.

Thank you for this referral. If the clinical or image interpretation does not parallel your findings or if I can be of any further assistance please contact me.

Andrea Nicastro, MPH, DVM, Diplomate DACVIM (Small Animal Internal Medicine)
 info@SonoPath.com