

PATIENT PRESENTING CLINICAL SIGNS

Gracie Ertel

History: History of PLN and renal disease since 11/2021. History of UTI and was treated with 3 weeks of Clavamox in 6/2022 for E.coli and B-hemolytic strep. The B-hemolytic strep resolved however the e.coli has not. Imaging to check for structural disease of the kidneys and bladder that would cause no reponse to antibiotics for E.coli. Also had pancreatitis 6/2022. Treated with diet and pain medication. cPL is now normal.

SPECIES

Canine

BREED

Cocker Spaniel

Abnormal PE/Chem/CBC/UA Results: June 2022 HCT=29.7% (37.3-61.7) Hgb=10.3 (13.1-20.5) BUN=57 (7-27) Creat=WNL July 23.2022 cPL=50 (0-200) urine culture= E.coli >100,000

ULTRASONOGRAPHIC EXAMINATION OF THE ABDOMEN

Urinary System

SEX

Spayed Female

The **urinary bladder** wall is normal in thickness and the mucosal surface is smooth. The bladder lumen is moderately distended with anechoic urine. No masses, inflammatory changes or calculi are observed. The region of the trigone and the visualized portion of the proximal urethra are normal.

AGE

11 years, 7 mos

The **left kidney** is normal size (4.39 cm in length); with a slightly irregular shape. The cortex is variably thickened. There is moderate loss of corticomedullary distinction. Moderate pyelectasia is present (0.32 cm in the longitudinal plane). There is no evidence of nephroliths, infarcts or hydroureter.

WEIGHT

13.4 lbs

The **right kidney** is normal size (4.21 cm in length); normal shape and architecture with smooth peripheral margins. There is a normal 1:3 cortex to medulla ratio with mild loss of corticomedullary distinction. Moderate pyelectasia is present (0.33 cm in the longitudinal plane). Echogenic debris is observed within the renal pelvis. There is no evidence of nephroliths, infarcts or hydroureter.

Adrenal Glands

INTERPRETED BY

Andrea Nicastro,
DVM, Diplomate
ACVIM (Small Animal
Internal Medicine)

The **left adrenal gland** is upper limits of normal size (0.54 cm at cranial pole) (0.55 cm at caudal pole); normal shape; homogenous parenchyma. The glandular echogenicity and detail are unremarkable. Capsule, cortex, and medullary definition are normal. The phrenicoabdominal vein and surrounding vasculature are normal.

IMAGING PERFORMED BY

M. Kermendy, CVT

The **right adrenal gland** is normal size (0.46 cm at cranial pole) (0.49 cm at caudal pole); normal shape; homogenous parenchyma. The glandular echogenicity and detail are unremarkable. Capsule, cortex, and medullary definition are normal. The phrenicoabdominal vein and surrounding vasculature are normal.

HOSPITAL NAME

Wauwatosa Vet

Spleen

The **spleen** is normal in size (0.92 cm in width at the level of the hilus) with a normal capsular contour. There is appropriate echogenicity and echotexture. No focal lesions are observed. Splenic vasculature is normal.

REFERRING VET

Elaine Binor, DVM

Liver

The **liver** is subjectively normal in size with normal contours and structure. There is appropriate echogenicity and echotexture. No overt structural evidence of inflammatory, infiltrative, or regenerative pathology is evident. Vascular and biliary tracts are of normal volume with no evidence of congestion. No pathological hepatic lymphadenopathy observed. The portal vein to caudal vena cava ratio is approximately 1: 1.

INVOICE

11385

The **gall bladder** is distended. The wall is normal in thickness. A moderate amount of aggregated/organized, echogenic partially dependent sludge is observed within the lumen. The cystic and common bile ducts are normal/not seen.

DATE

8.10.22

Gastrointestinal

The **stomach and intestine** are free of stasis and exhibit normal peristaltic activity. The gastric lumen is minimally fluid distended. The gastric wall and pylorus are normal in thickness with a normal layering pattern. The pyloric outflow tract is patent. The small intestinal lumen is not dilated. The small intestinal wall thickness is normal with a normal layering pattern and appropriate mural detail. Discreet masses are not identified. The colonic wall is normal. There is no evidence of an obstructive pattern.

Pancreas

The left limb of the pancreas is visible with normal curvilinear peripheral contours. The parenchyma is largely hypoechoic relative to surrounding omental fat and slightly mottled in appearance. The pancreatic duct is visible but not overtly dilated (0.22 cm in diameter). There is no evidence of peripancreatic inflammation or effusion.

Free Abdomen

The **peritoneal cavity** is normal. There is no evidence of inflammation or effusion. The abdominal **lymph nodes** are normal/not visible.

ULTRASONOGRAPHIC FINDINGS

Primary Findings

- Bilateral age-related regenerative renal changes. The bilateral pyelectasia may be secondary to pyelonephritis, age-related remodeling, PU/PD (if applicable), of some combination thereof.
- The gall bladder changes are consistent with a developing mucocele.

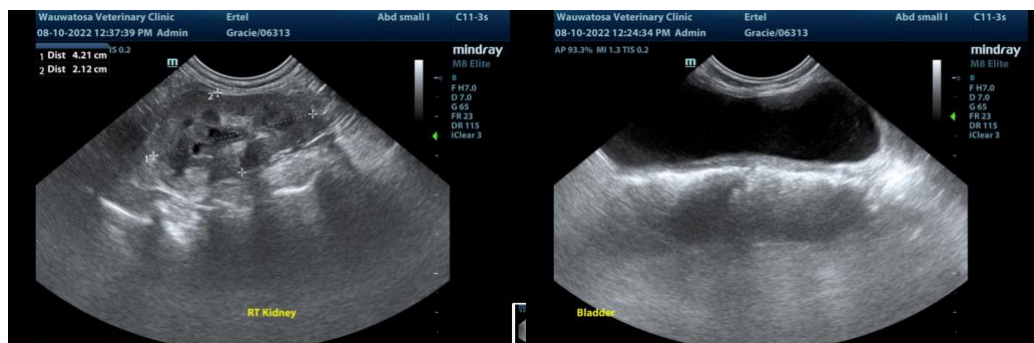
Secondary Findings

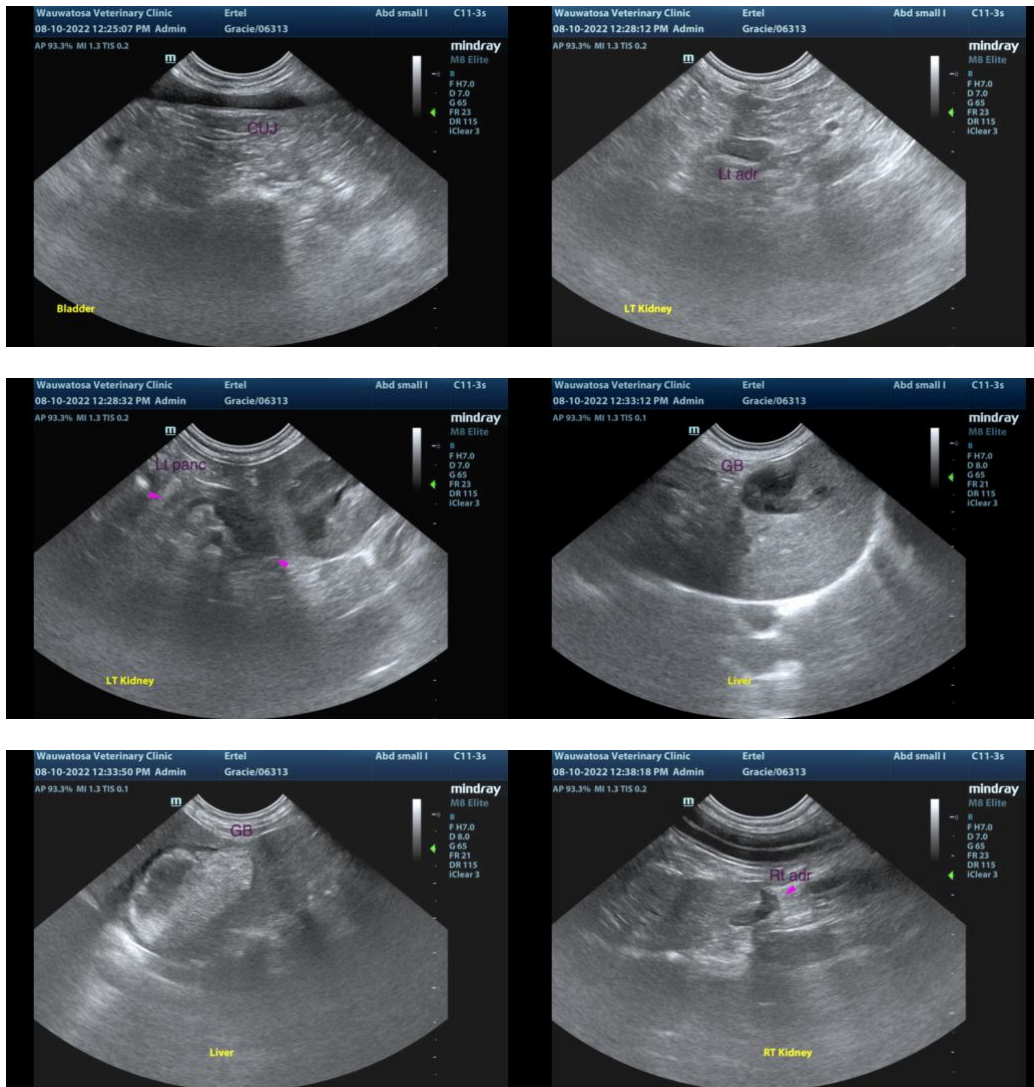
- The pancreatic changes are most consistent with age-related parenchymal remodeling, potentially secondary to a prior inflammatory episode, early fibrosis or chronic pancreatitis.

INTERPRETATION OF THE FINDINGS & FURTHER RECOMMENDATIONS

Consider a repeat urine culture and sensitivity and a more prolonged antibiotic course (i.e., 4-6 weeks), potentially, with a fluoroquinolone, if the infection is sensitive to this class of antibiotics. Fluoroquinolones have good renal tissue penetration. Ideally, a urine culture would be performed halfway through the antibiotic course to determine if resistance has developed, and then again 5-7 days after the last dose.

Given the gall bladder changes, Ursodeoxycholic acid (Ursodiol) at 10-15 mg/kg once a day is recommended. Serial sonographic monitoring (e.g., every 6-8 weeks) of the gall bladder is recommended to assess for progression to a fully-formed mucocele.





The information and recommendations provided are based on the images presented by the referring veterinarian/sonographer. No evaluation can be communicated regarding pathology that was not visible in the image/video clips provided.

Thank you for this referral. If the clinical or image interpretation does not parallel your findings or if I can be of any further assistance, please contact me.

Andrea Nicastro, MPH, DVM, Diplomate DACVIM (Small Animal Internal Medicine)
info@SonoPath.com