



PATIENT

Duke Baehr

PRESENTING CLINICAL SIGNS

History: history stones, checking to make sure none seen. No urinary signs currently. UA in house negative.

SPECIES

Canine

ULTRASONOGRAPHIC EXAMINATION OF THE ABDOMEN

**This study was limited to the urinary system. There is a potential for pathology in organs that were not visualized.

BREED

Chihuahua

Urinary System

SEX

Male, neutered

The urinary bladder wall is normal in thickness and the mucosal surface is smooth. The bladder lumen is moderately distended with mostly anechoic urine. No masses, inflammatory changes or calculi are observed. Ureteral papillae and visualized portion of the proximal urethra, visible to a depth of 2 cm, are normal.

AGE

3 Yrs.

The prostate is normal in size (0.56 cm in width) and shape. Parenchyma is homogenous. The prostatic urethra appears normal without evidence of dilation or obstruction.

WEIGHT

7.49 lbs.

The left kidney is normal size (3.90 cm in length); normal shape and architecture with smooth peripheral margins. There is a normal 1:3 cortex to medulla ratio with normal corticomedullary distinction. There is no evidence of pyelectasia, nephroliths, infarcts or hydroureter. Renal vasculature is normal.

The right kidney is normal size (4.30 cm in length); normal shape and architecture with smooth peripheral margins. There is a normal 1:3 cortex to medulla ratio with normal corticomedullary distinction. There is no evidence of pyelectasia, nephroliths, infarcts or hydroureter. Renal vasculature is normal.

INTERPRETED BY

Andrea Nicastro, DVM,
Diplomate ACVIM
(Small Animal Internal
Medicine)

ULTRASONOGRAPHIC FINDINGS

There was no evidence of stones within the urinary tract.

IMAGING PERFORMED BY

Dr. Brittany Gardner

INTERPRETATION OF THE FINDINGS & FURTHER RECOMMENDATIONS

HOSPITAL NAME

Wilvet Salem

Consider periodic sonographic monitoring (i.e., every 3-4 months) to assess for recurrence of the bladder stones.

REFERRING VET

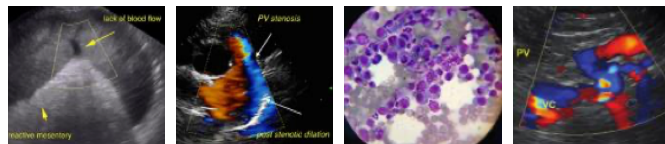
Dr. Brittany Gardner

INVOICE

13812

DATE

8/10/22



PATIENT

Duke Baehr

SPECIES

Canine

BREED

Chihuahua

SEX

Male, neutered

AGE

3 Yrs.

WEIGHT

7.49 lbs.

INTERPRETED BY

Andrea Nicastro, DVM,
Diplomate ACVIM
(Small Animal Internal
Medicine)

**IMAGING
PERFORMED BY**

Dr. Brittany Gardner

HOSPITAL NAME

Wilvet Salem

REFERRING VET

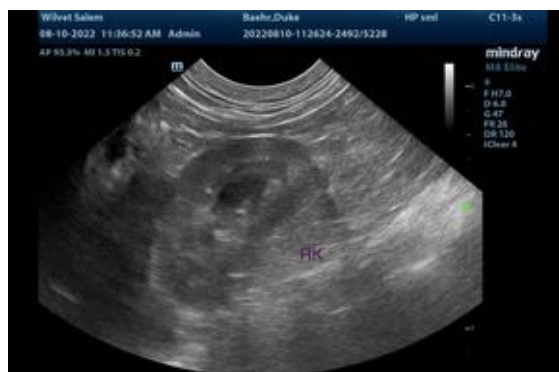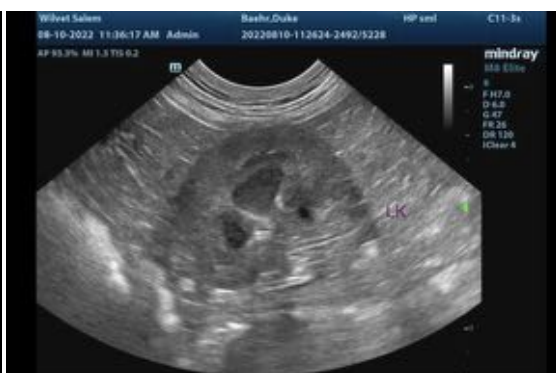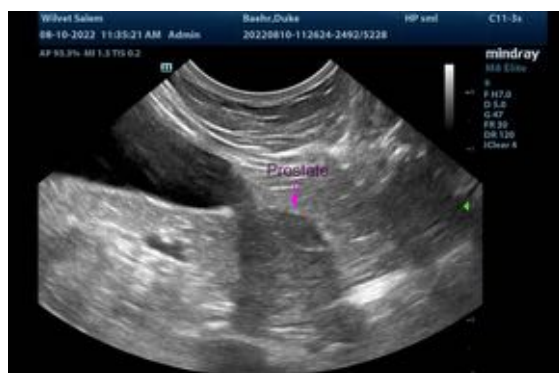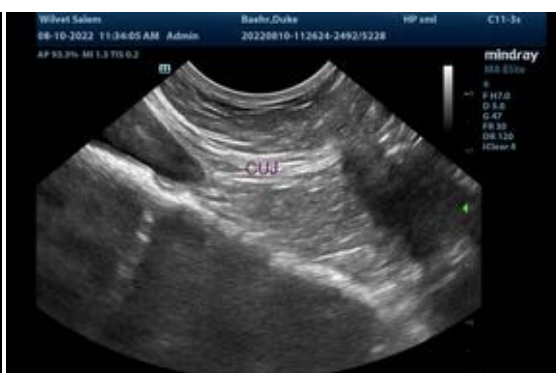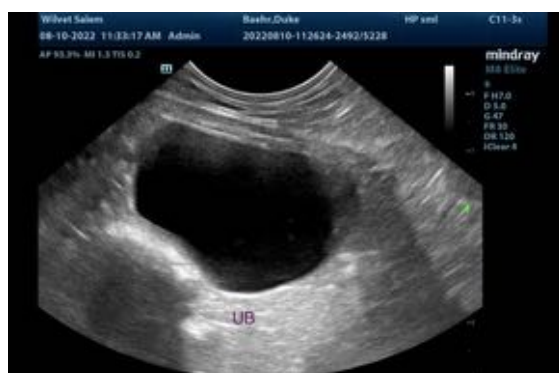Dr. Brittany Gardner

INVOICE

13812

DATE

8/10/22



The information and recommendations provided are based on the images presented by the referring veterinarian/sonographer. No evaluation can be communicated regarding pathology that was not visible in the image/video clips provided.

Thank you for this referral. If the clinical or image interpretation does not parallel your findings or if I can be of any further assistance please contact me.

Andrea Nicastro, MPH, DVM, Diplomate DACVIM (Small Animal Internal Medicine)
info@SonoPath.com