

**DATE PRESENTING CLINICAL SIGNS**

8/10/21

History: Bloody diarrhea, blood in urine.
 Date of Previous IntraPet Ultrasound: No previous.
 Sedation: Not needed.
 Stat Report: Not requested.

PATIENT

Precious Mass

SPECIES

Canine

BREED

Shih Tzu

SEX

Female, spayed

AGE

2007

WEIGHT

17.5 lbs.

INTERPRETED BY

Andrea Nicastro, DVM,
 Diplomate ACVIM
 (Small Animal Internal
 Medicine)

HOSPITAL NAME

Creswell Vet Clinic

REFERRING VET

Dr. Cullum

INVOICE

11860

ULTRASONOGRAPHIC EXAMINATION OF THE ABDOMEN**Urinary System**

The urinary bladder is minimally distended with anechoic urine. The wall is concentrically thickened up to 1.10 cm with an irregular mucosal surface. No cystic calculi are observed. The visible portion of the proximal urethra is normal.

The left kidney is borderline small (3.55 cm in length) with an irregular shape. The cortex is hyperechoic and variably thickened and there is poor corticomedullary distinction. Several cortical cysts are present. There is mild pyelectasia (0.36 cm in the transverse plane). There is no evidence of nephroliths or hydroureter. Renal vasculature is normal.

The right kidney is normal size (4.84 cm in length); normal shape and architecture with smooth peripheral contours. The parenchyma is thickened and hyperechoic and there is moderate loss of corticomedullary distinction. Several cortical cysts are visualized. There is no evidence of pyelectasia, nephroliths, infarcts or hydroureter. Renal vasculature is normal.

Adrenal Glands

The left adrenal gland is mildly enlarged (0.45 cm at cranial pole) (0.66 cm at caudal pole) (2.25 cm in length); normal shape; homogenous parenchyma. The glandular echogenicity and detail are unremarkable. Capsule, cortex, and medullary definition are normal. The phrenicoabdominal vein and surrounding vasculature are normal.

The right adrenal gland is normal size (0.83 cm at cranial pole) (0.51 cm at caudal pole) (1.89 cm in length); normal shape; homogenous parenchyma. The glandular echogenicity and detail are unremarkable. Capsule, cortex, and medullary definition are normal. The phrenicoabdominal vein and surrounding vasculature are normal.

Spleen

The spleen is overall normal in size with an irregular shape. A 2.24 x 1.85 cm hypoechoic to slightly heterogeneous vascular mass/nodule is observed at the caudal aspect. In addition, a 1.43 x 1.28 cm hyperechoic nodule is observed in the region of the hilus. Both lesions cause capsular expansion. The remaining parenchyma is homogeneous. Splenic vasculature appears normal with no evidence of thrombosis.

Liver

The liver is subjectively enlarged with rounded peripheral contours. The parenchyma is isoechoic relative to the spleen and diffusely mottled with numerous varying sized ill-defined hypoechoic nodules/areas throughout the organ. A 2.24 x 1.85 cm irregular hypoechoic to heterogeneous nodule/mass is observed deep left to mid liver. Vascular and biliary tracts are of normal volume with no evidence of congestion. The gall bladder lumen is moderately distended. The wall is normal in thickness. A few polypoid like lesions are arising from the luminal surface. A small to moderate amount of partially dependent echogenic debris is observed within the lumen. The cystic and common bile ducts are normal/not seen.

Gastrointestinal

The gastric lumen is moderately distended with ingesta and chyme. The gastric wall and pylorus are normal in thickness with a normal layering pattern. The small intestinal lumen is segmentally dilated with fluid and chyme. The small intestinal wall thickness is normal with a normal layering pattern and appropriate mural

detail. Discreet masses are not identified. The colonic wall is normal. The lumen of the descending colon contains soft shadowing fecal material. No obstructive disease is noted.

Pancreas

The right limb of the pancreas is visible with normal curvilinear peripheral contours. The parenchyma is largely isoechoic relative to surrounding omental fat and slightly mottled in appearance. The pancreatic duct is visible but not overtly dilated (0.26 cm in diameter). There is no evidence of peripancreatic inflammation or effusion.

Free Abdomen

The peritoneal cavity is normal. There is no evidence of inflammation or effusion. The abdominal lymph nodes are normal/not visible.

Other

A brief echocardiogram reveals no evidence of pericardial effusion or obvious right atrial/auricular mass.

ULTRASONOGRAPHIC FINDINGS

Primary Findings:

- The hypoechoic splenic mass is concerning for infiltrative neoplasia (i.e., sarcoma, round cell tumor). The hyperechoic splenic nodule trends toward the benign (i.e., myelolipoma) with lower potential for neoplastic process.
- The larger hepatic nodule/mass is also concerning for a neoplastic process although benign pathology (i.e., regenerative nodular hyperplasia) is possible. The diffuse hepatic parenchymal changes are non-specific and could be secondary to regenerative nodular hyperplasia, age-related remodeling, vacuolar hepatopathy, infiltrative neoplasia, inflammatory disease or other hepatopathy.
- The urinary bladder wall changes could be consistent with cystitis or infiltrative neoplasia (i.e., transitional cell carcinoma). The wall thickening may be somewhat artifactual due to lack of full repletion.

Secondary Findings:

- The pancreatic changes are most consistent with age-related parenchymal remodeling, potentially secondary to a prior inflammatory episode, early fibrosis or chronic pancreatitis.
- Borderline left adrenomegaly.
- The bilateral renal changes are consistent with chronic interstitial nephrosis/nephritis with cortical cysts.

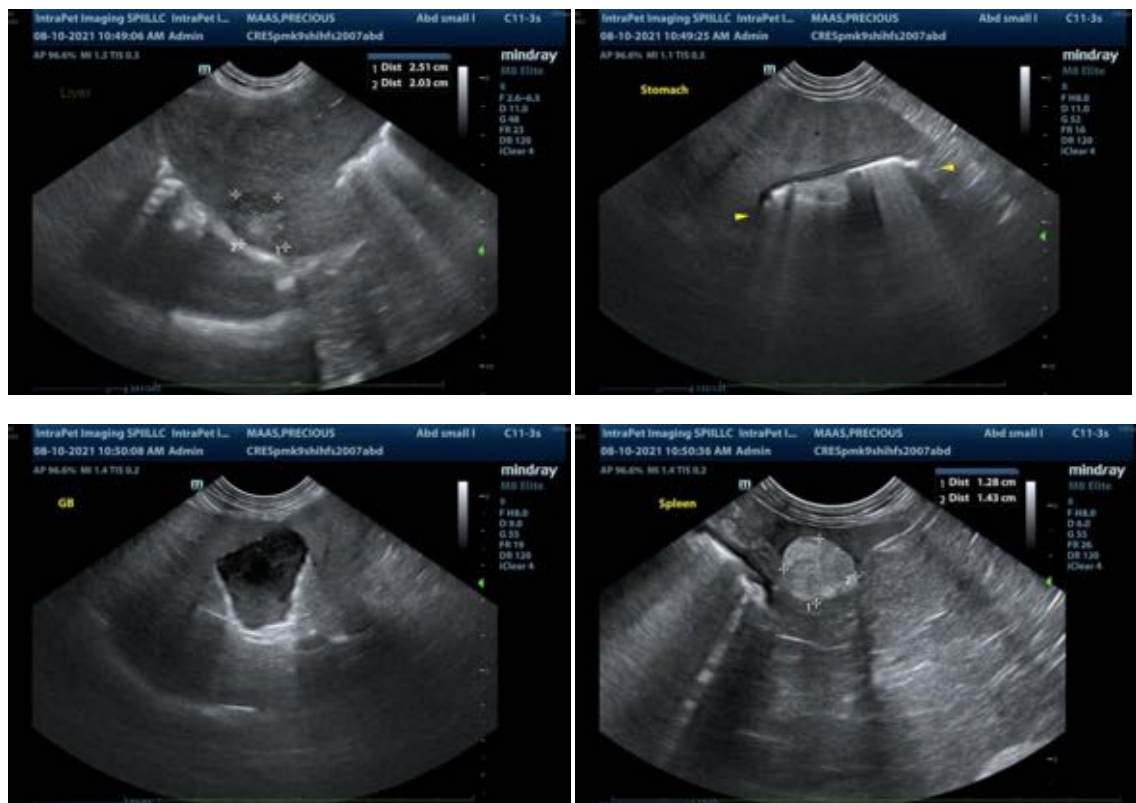
*An obvious cause for the patient's gastrointestinal signs is not definitively identified in this study.

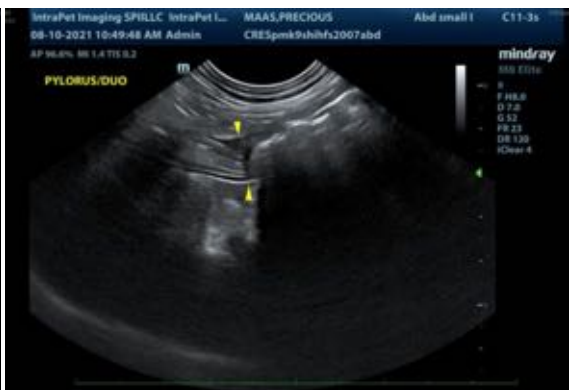
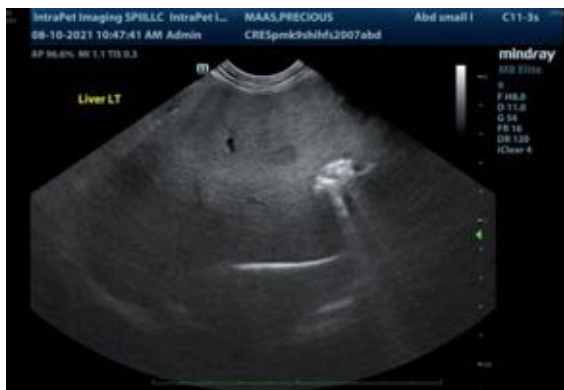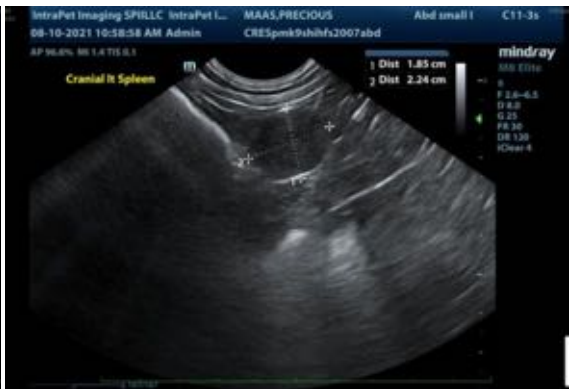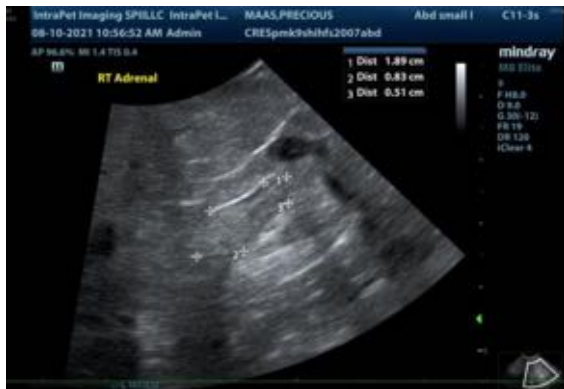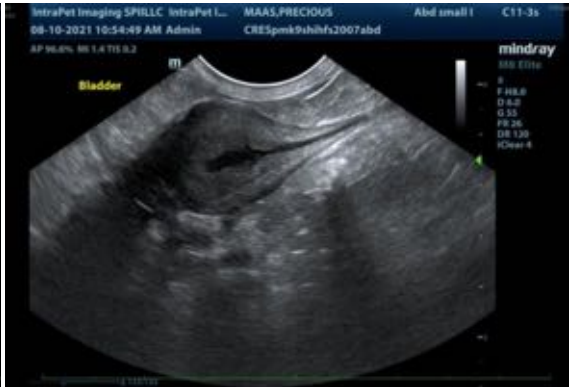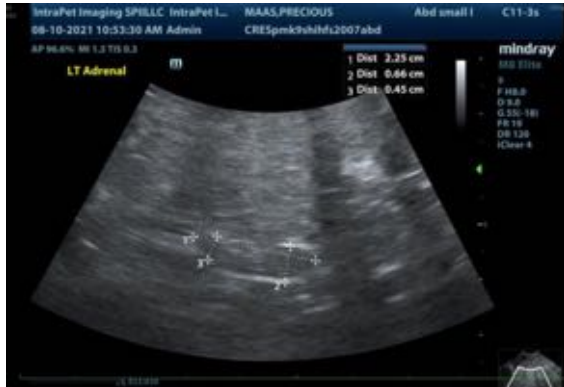INTERPRETATION OF THE FINDINGS & FURTHER RECOMMENDATIONS

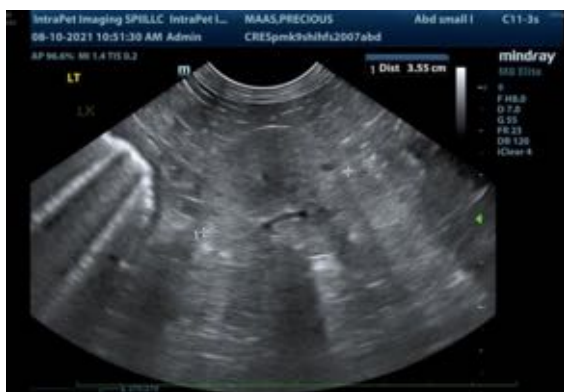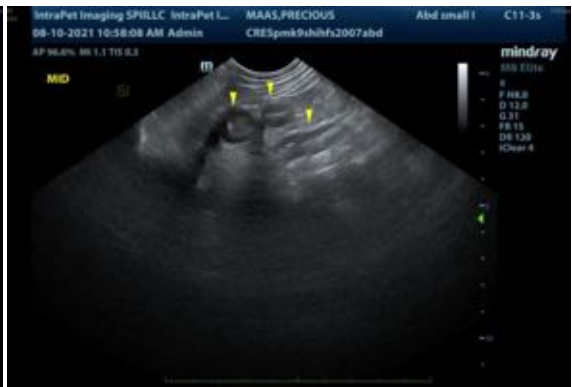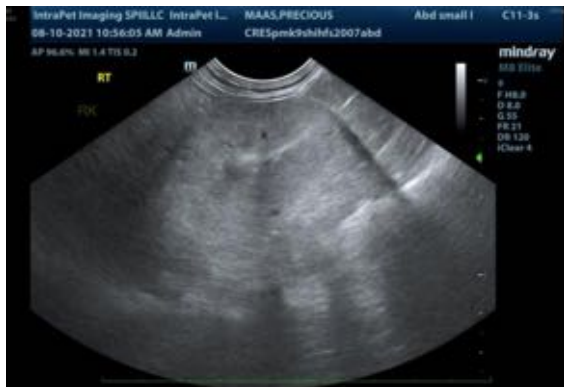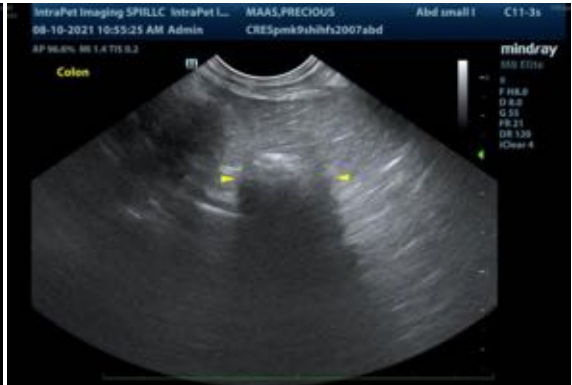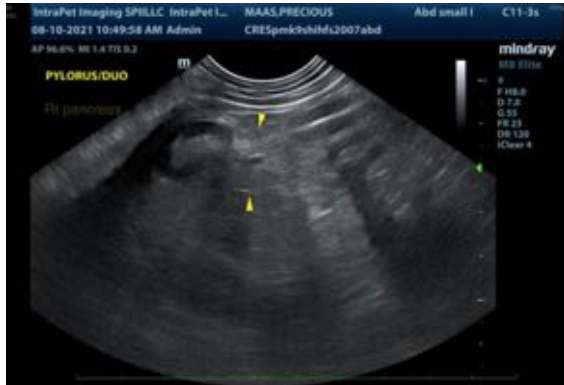- Three-view thoracic radiographs are recommended to assess for pulmonary metastases.
- Regarding the splenic masses, fine needle aspirates are recommended (if clotting status is normal). 25-gauge needles should be used. If cytologic evaluations are inconclusive, a splenectomy with

surgical biopsies may be necessary to get a definitive diagnosis. If surgery is pursued, liver biopsies, particularly the larger hepatic nodule, should also be obtained.

- Regarding the hematuria, a urinalysis and urine culture and sensitivity are recommended.
- Baseline bloodwork including a CBC chemistry panel and T4 are also recommended if not already performed.
- Regarding the gastrointestinal signs, consider the following:
 1. A fecal evaluation for ova/Giardia
 2. Prophylactic deworming with Fenbendazole at 50 mg/kg once a day for 5 days is recommended. Repeat above protocol in 3 weeks.
 3. +/- fecal GI PCR infectious panel.
 4. Supplementation with a probiotic with a high colony count (i.e., Visbiome or Provable Forte).







The information and recommendations provided are based on the images presented by the referring veterinarian. No evaluation can be communicated regarding pathology that was not visible in the image/video clips provided.

Thank you for this referral. If the clinical or image interpretation does not parallel your findings or if I can be of any further assistance please contact me.

Andrea Nicastro, DVM, Diplomate ACVIM (*Small Animal Internal Medicine*)
Andrea.nicastro@sonopath.com