

PATIENT PRESENTING CLINICAL SIGNS

PATIENT Sparky Favell
History: Not himself, increased frequency of urination again, return of hematuria; past history of hematuria (previous ultrasound one), was treated successfully previously with oral abx; this time urine culture was neg and no abx treatment was done.

SPECIES Canine
Meds: Tramadol 100mg BID. Gabapentin 200mg BID. Aventi Omega 3 Complete

ULTRASONOGRAPHIC EXAMINATION OF THE ABDOMEN

BREED *Urinary System*

Lab
The **urinary bladder** wall is normal in thickness and the mucosal surface is smooth. The bladder lumen is moderately distended with anechoic urine. No masses, inflammatory changes or calculi are observed. Ureteral papillae and visualized portion of the proximal urethra, visible to a depth of 2 cm, are normal.

SEX Neutered Male
The **prostate** is not definitively visualized due to its pelvic location.

AGE 12 years
The **left kidney** is normal size (7.03 cm in length); normal shape and architecture with smooth peripheral margins. There is a normal 1:3 cortex to medulla ratio with moderate loss of corticomedullary distinction. There is no evidence of pyelectasia, nephroliths, infarcts or hydroureter. Renal vasculature is normal.

WEIGHT 86 lbs
The **right kidney** is normal size (6.92 cm in length); normal shape and architecture with smooth peripheral margins. There is a normal 1:3 cortex to medulla ratio with mild to moderate loss of corticomedullary distinction. There is no evidence of pyelectasia, nephroliths, infarcts or hydroureter. Renal vasculature is normal.

Adrenal Glands

The **left adrenal gland** is normal size (0.66 cm at cranial pole) (0.69 cm at caudal pole) (2.45 cm in length); normal shape; homogenous parenchyma. The glandular echogenicity and detail are unremarkable. Capsule, cortex, and medullary definition are normal. The phrenicoabdominal vein and surrounding vasculature are normal.

The **right adrenal gland** is normal size (2.25 cm at cranial pole) (0.67 cm at caudal pole) (3.18 cm in length); normal shape; homogenous parenchyma. The glandular echogenicity and detail are unremarkable. Capsule, cortex, and medullary definition are normal. The phrenicoabdominal vein and surrounding vasculature are normal.

Spleen

The **spleen** is subjectively normal in size (0.37 cm in width at the level of the hilus) with normal curvilinear peripheral contours. The parenchyma is subtly mottled in appearance. Several, small, ill-defined hyperechoic areas are observed throughout the organ. A 1.40 cm hypoechoic nodule is also observed. Splenic vasculature is normal with no evidence of thrombosis.

Liver

The **liver** is subjectively normal in size with normal curvilinear peripheral contours. The parenchyma is hypoechoic relative to the spleen with minor changes consistent with age-related remodeling. No focal lesions are observed. Hepatic vasculature and biliary tracts are of normal volume with no evidence of congestion.

INTERPRETED BY

Andrea Nicastro, DVM,
Diplomate ACVIM
(Small Animal Internal
Medicine)

IMAGING PERFORMED BY

Kelly Reschny

HOSPITAL NAME

South Side PH

REFERRING VET

Dr. Hughes

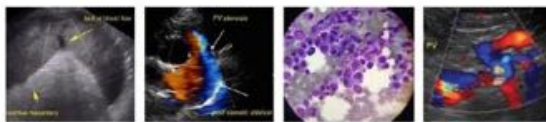
INVOICE

11207

DATE

7.7.22

The **gall bladder** lumen is moderately distended. The wall is thin and smooth. A moderate amount of aggregated, echogenic gravity dependent sludge is observed within the lumen. The cystic and common bile ducts are normal/not seen.


PATIENT

Sparky Favell

SPECIES

Canine

BREED

Lab

SEX

Neutered Male

AGE

12 years

WEIGHT

86 lbs

INTERPRETED BY

 Andrea Nicastro, DVM,
 Diplomate ACVIM
 (Small Animal Internal
 Medicine)

**IMAGING
 PERFORMED BY**

Kelly Reschny

HOSPITAL NAME

South Side PH

REFERRING VET

Dr. Hughes

INVOICE

11207

DATE

7.7.22

Gastrointestinal

The **stomach and intestine** are free of stasis and exhibit normal peristaltic activity. The gastric lumen is not distended. The gastric wall and pylorus are normal in thickness with a normal layering pattern. The pyloric outflow tract is patent. The small intestinal lumen is not dilated. The small intestinal wall thickness is normal with a normal layering pattern and appropriate mural detail. Discreet masses are not identified. The colonic wall is normal. There is no evidence of an obstructive pattern.

Pancreas

The region of the **pancreas** is isoechoic relative to surrounding omental fat. No obvious parenchymal abnormalities are observed. There is no evidence of regional inflammation or effusion.

Free Abdomen

The **peritoneal cavity** is normal. There is no evidence of inflammation or effusion. The abdominal **lymph nodes** are normal/not visible.

ULTRASONOGRAPHIC FINDINGS
Primary Findings

- Bilateral, chronic, nonspecific, age-related renal changes

Secondary Findings

- The hepatic changes are consistent with age-related parenchymal remodeling and are not considered clinically significant at this time.
- Gall bladder sludge, non-mucocele
- The hypoechoic splenic nodule trends toward the benign (i.e., focus of lymphoid hyperplasia, extramedullary hematopoiesis, or similar). However, an emerging tumor cannot be completely excluded. The hyperechoic areas within the spleen are likely benign (i.e., myelolipomas) with a low possibility of emerging neoplasia.

*An obvious cause for the patient's hematuria is not identified in this study. Considerations include microscopic urethral or prostatic neoplasia (i.e., transitional cell carcinoma), occult urinary tract infection, distal urethroliths, benign renal hematuria, other.

INTERPRETATION OF THE FINDINGS & FURTHER RECOMMENDATIONS

Baseline lab work, including a CBC Chemistry panel and T4 is recommended to assess overall metabolic function (if not already performed).

Caudal abdominal/pelvic radiographs are recommended (if not already performed) to assess for distal urethroliths.

Consider a urine BRAF test to further assess for lower urinary tract neoplasia. It should be noted however, that a negative BRAF test does not completely rule out the possibility of cancer. Therefore, if the clinical suspicion is high, additional diagnostics may be necessary to get a definitive diagnosis.

Also consider three-view thoracic radiographs to assess cardiopulmonary status.

If the above diagnostics are inconclusive, consider empirical treatment for occult urinary tract infection with a broad-spectrum antibiotic.



PATIENT

Sparky Favell

SPECIES

Canine

BREED

Lab

SEX

Neutered Male

AGE

12 years

WEIGHT

86 lbs

INTERPRETED BY

Andrea Nicastro, DVM,
Diplomate ACVIM
(Small Animal Internal
Medicine)

**IMAGING
PERFORMED BY**

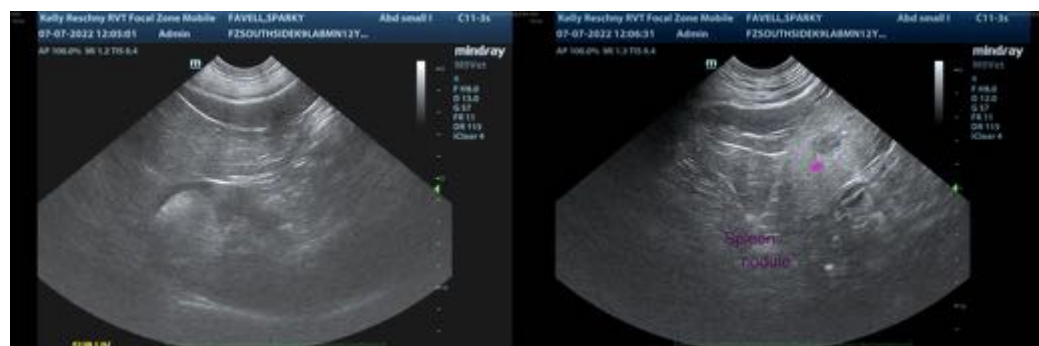
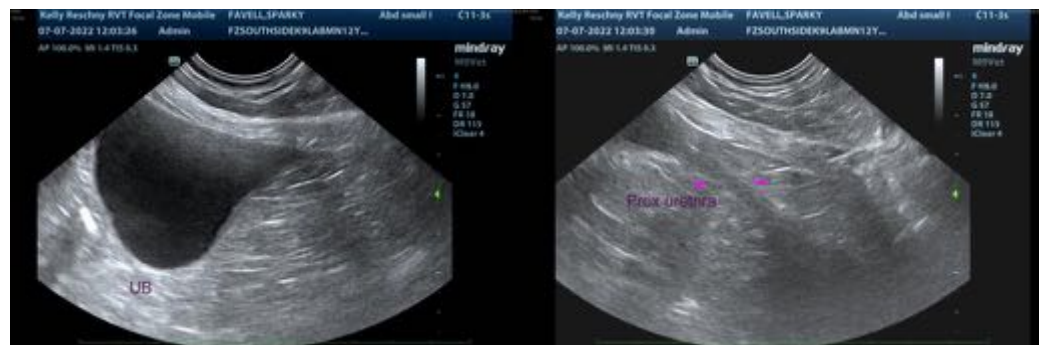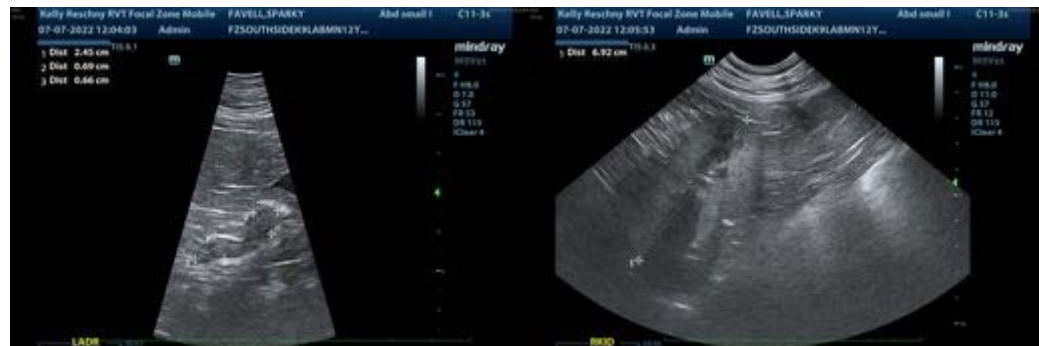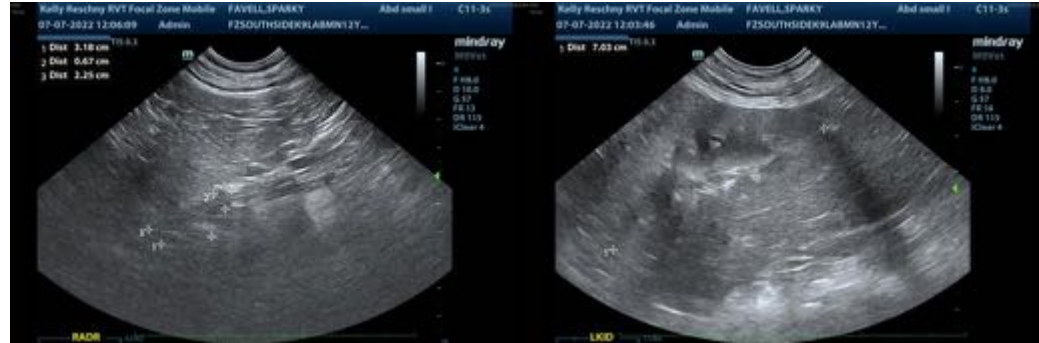Kelly Reschny

HOSPITAL NAME

South Side PH

REFERRING VET

Dr. Hughes



INVOICE

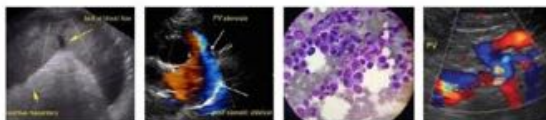
11207

DATE

7.7.22

The information and recommendations provided are based on the images presented by the referring veterinarian/sonographer. No evaluation can be communicated regarding pathology that was not visible in the image/video clips provided.

Thank you for this referral. If the clinical or image interpretation does not parallel your findings or if I can be of any further assistance, please contact me.



PATIENT

Andrea Nicastro, DVM, Diplomate DACVIM (Small Animal Internal Medicine)
info@SonoPath.com

Sparky Favell

SPECIES

Canine

BREED

Lab

SEX

Neutered Male

AGE

12 years

WEIGHT

86 lbs

INTERPRETED BY

Andrea Nicastro, DVM,
Diplomate ACVIM
(Small Animal Internal
Medicine)

**IMAGING
PERFORMED BY**

Kelly Reschny

HOSPITAL NAME

South Side PH

REFERRING VET

Dr. Hughes

INVOICE

11207

DATE

7.7.22