



PATIENT PRESENTING CLINICAL SIGNS

Rex Taylor Elevated liver enzymes. History of subcutaneous mast cell tumor (Grade 2, completely excised). Has had at least one collapsing episode.

SPECIES

Canine

BREED

Fr Bulldog

SEX

Neutered Male

AGE

11 years, 7 mos

WEIGHT

26.60 lbs

INTERPRETED BY

Andrea Nicastro, DVM,
Diplomate ACVIM (*Small
Animal Internal Medicine*)

IMAGING PERFORMED BY

Andrea Nicastro, DVM,
Diplomate ACVIM (*Small
Animal Internal Medicine*)

HOSPITAL NAME

Park West Vet Assoc

REFERRING VET

Dr. Butler

INVOICE

13577

DATE

6.7.23

ULTRASONOGRAPHIC EXAMINATION OF THE ABDOMEN

Urinary System

The urinary bladder is mildly distended. The wall in the region of the apex is thickened (up to 0.51 cm) and irregular. The wall tapers to a normal thickness as it extends towards the cystourethral junction. Several cystic calculi are visualized (the largest measuring 0.39 cm in diameter). A small amount of echogenic debris is suspended within the lumen. The region of the trigone and the proximal urethra, visible to a depth of 2 cm, are normal.

The prostate is normal in size (0.62 cm in width) and shape. Parenchyma is homogenous. The prostatic urethra appears normal without evidence of dilation or obstruction.

The left kidney is normal in size (4.88 cm in length) with a normal shape, smooth peripheral margins, and normal internal architecture. There is mild loss of corticomedullary distinction. Several hyperechoic shadowing diverticular foci are observed. Several nonobstructive nephroliths are visualized. There is no evidence of pyelectasia, infarcts or hydroureter. Renal vasculature is normal.

The right kidney is normal in size (4.61 cm in length) with a normal shape, smooth peripheral margins, and normal internal architecture. There is mild loss of corticomedullary distinction. Several hyperechoic shadowing diverticular foci are observed. Several nonobstructive nephroliths are visualized. There is no evidence of pyelectasia, infarcts or hydroureter. Renal vasculature is normal.

Adrenal Glands

The left adrenal gland is borderline enlarged (0.75 cm at cranial pole) (0.67 cm at caudal pole) with a normal shape and homogenous parenchyma. The glandular echogenicity and detail are unremarkable. Capsule, cortex, and medullary definition are normal. The phrenicoabdominal vein and surrounding vasculature are normal.

The right adrenal gland is borderline enlarged (0.59 cm at cranial pole) (0.74 cm at caudal pole) with a normal shape and homogenous parenchyma. The glandular echogenicity and detail are unremarkable. Capsule, cortex, and medullary definition are normal. The phrenicoabdominal vein and surrounding vasculature are normal.

Spleen

The spleen is normal in size (1.07 cm in width at the level of the hilus) with a normal capsular contour. There is appropriate echogenicity and echotexture. No focal lesions are observed. Splenic vasculature is normal.

Liver

The liver is prominent in size with normal curvilinear peripheral contours. The parenchyma is hypoechoic relative to the spleen and slightly mottled in appearance. No distinct focal lesions are observed. Hepatic vasculature is subjectively mildly dilated. Intrahepatic biliary tracts are normal.

The gall bladder is distended. The wall is normal in thickness. Numerous polypoid-like lesions are arising from the luminal surface. A small to moderate amount of suspended echogenic debris is also seen. The cystic and common bile ducts are normal/not seen.

Gastrointestinal



PATIENT

Rex Taylor

SPECIES

Canine

BREED

Fr Bulldog

SEX

Neutered Male

AGE

11 years, 7 mos

WEIGHT

26.60 lbs

INTERPRETED BY

Andrea Nicastro, DVM,
Diplomate ACVIM (*Small
Animal Internal Medicine*)

**IMAGING
PERFORMED BY**

Andrea Nicastro, DVM,
Diplomate ACVIM (*Small
Animal Internal Medicine*)

HOSPITAL NAME

Park West Vet Assoc

REFERRING VET

Dr. Butler

INVOICE

13577

DATE

6.7.23

The stomach and intestine are free of stasis and exhibit normal peristaltic activity. The gastric lumen is not distended. The gastric wall and pylorus are normal in thickness with a normal layering pattern. The pyloric outflow tract is patent. The small intestinal lumen is not dilated. The small intestinal wall is normal in thickness with a normal layering pattern and appropriate mural detail. Discreet masses are not identified. The ileocecolic junction and colonic wall are normal. There is no evidence of an obstructive pattern.

Pancreas

The right limb of the pancreas is visible with normal curvilinear peripheral contours. The parenchyma is largely hyperechoic relative to surrounding omental fat and slightly mottled in appearance. The pancreatic duct is visible but not overtly dilated. There is no evidence of peripancreatic inflammation or effusion.

Free Abdomen

The peritoneal cavity is normal. There is no evidence of inflammation or effusion. The abdominal lymph nodes are normal/not visible.

Other

The caudal vena cava is subjectively dilated. A brief echocardiogram reveals a heart-based mass.

ULTRASONOGRAPHIC FINDINGS

Primary Findings

- Suspected heart-based mass (see echocardiogram report for further details). The subjective dilation of the caudal vena cava and hepatic venous dilation are thought to be secondary to increased hydrostatic pressure resulting from the heart-based mass.
- Cystic calculi. The urinary bladder wall changes are suggestive cystitis.
- The hepatic parenchymal changes could be consistent with age-related remodeling, regenerative nodular hyperplasia, passive congestion or some combination thereof. Inflammatory disease and infiltrative neoplasia are considered less likely.

Secondary Findings

- Mild bilateral chronic renal changes with nonobstructive nephrolithiasis
- Borderline bilateral adrenomegaly
- The pancreatic changes are most consistent with age-related parenchymal remodeling, potentially secondary to a prior inflammatory episode, early fibrosis or chronic pancreatitis.

INTERPRETATION OF THE FINDINGS & FURTHER RECOMMENDATIONS

- Three-view thoracic radiographs are recommended to assess for pulmonary metastases.
- Further recommendations should be based on the echocardiogram report.



PATIENT

Rex Taylor

SPECIES

Canine

BREED

Fr Bulldog

SEX

Neutered Male

AGE

11 years, 7 mos

WEIGHT

26.60 lbs

INTERPRETED BY

Andrea Nicastro, DVM,
Diplomate ACVIM (*Small Animal Internal Medicine*)

IMAGING PERFORMED BY

Andrea Nicastro, DVM,
Diplomate ACVIM (*Small Animal Internal Medicine*)

HOSPITAL NAME

Park West Vet Assoc

REFERRING VET

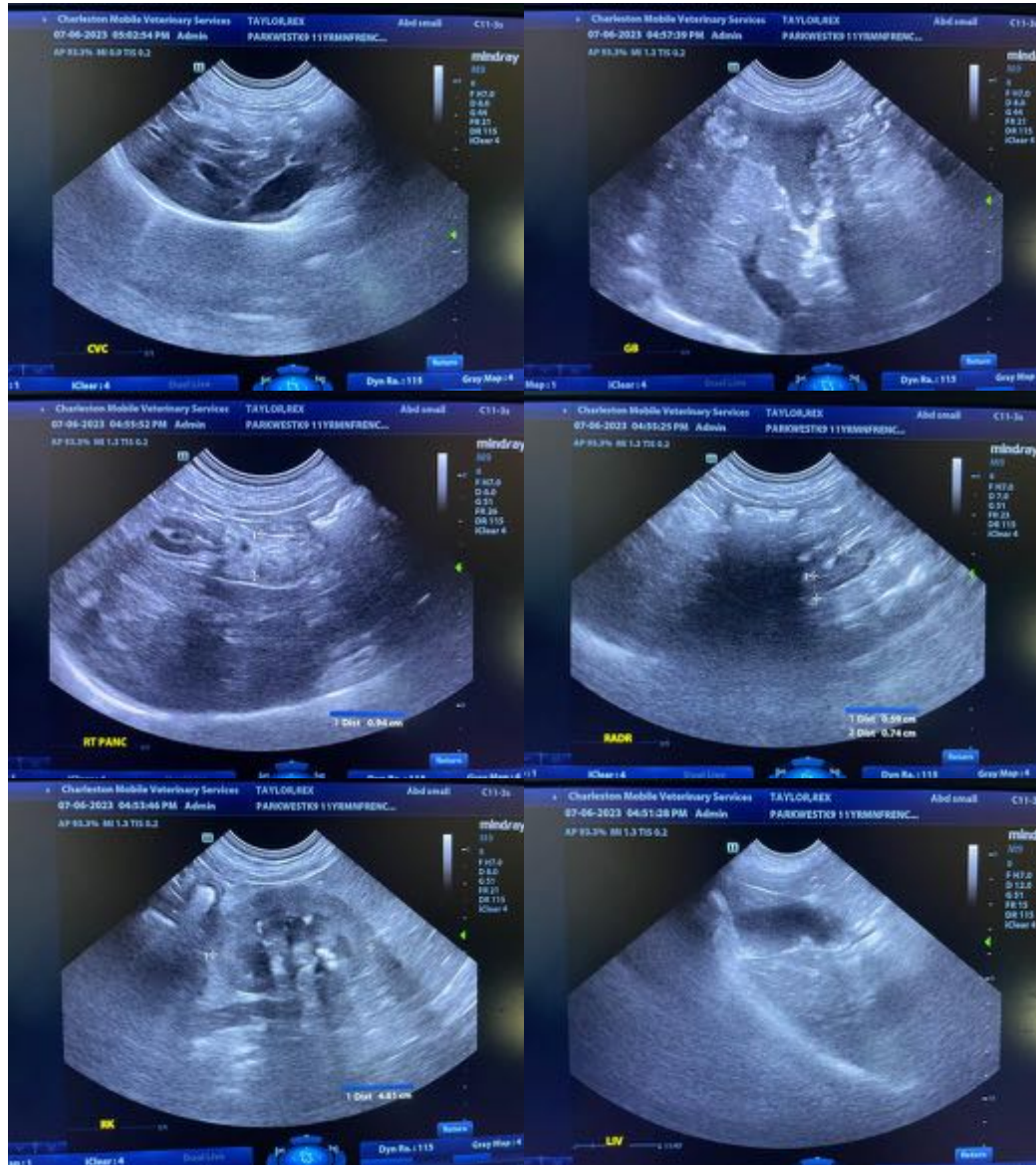
Dr. Butler

INVOICE

13577

DATE

6.7.23





PATIENT

Rex Taylor

SPECIES

Canine

BREED

Fr Bulldog

SEX

Neutered Male

AGE

11 years, 7 mos

WEIGHT

26.60 lbs

INTERPRETED BY

Andrea Nicastro, DVM,
Diplomate ACVIM (*Small
Animal Internal Medicine*)

**IMAGING
PERFORMED BY**

Andrea Nicastro, DVM,
Diplomate ACVIM (*Small
Animal Internal Medicine*)

HOSPITAL NAME

Park West Vet Assoc

REFERRING VET

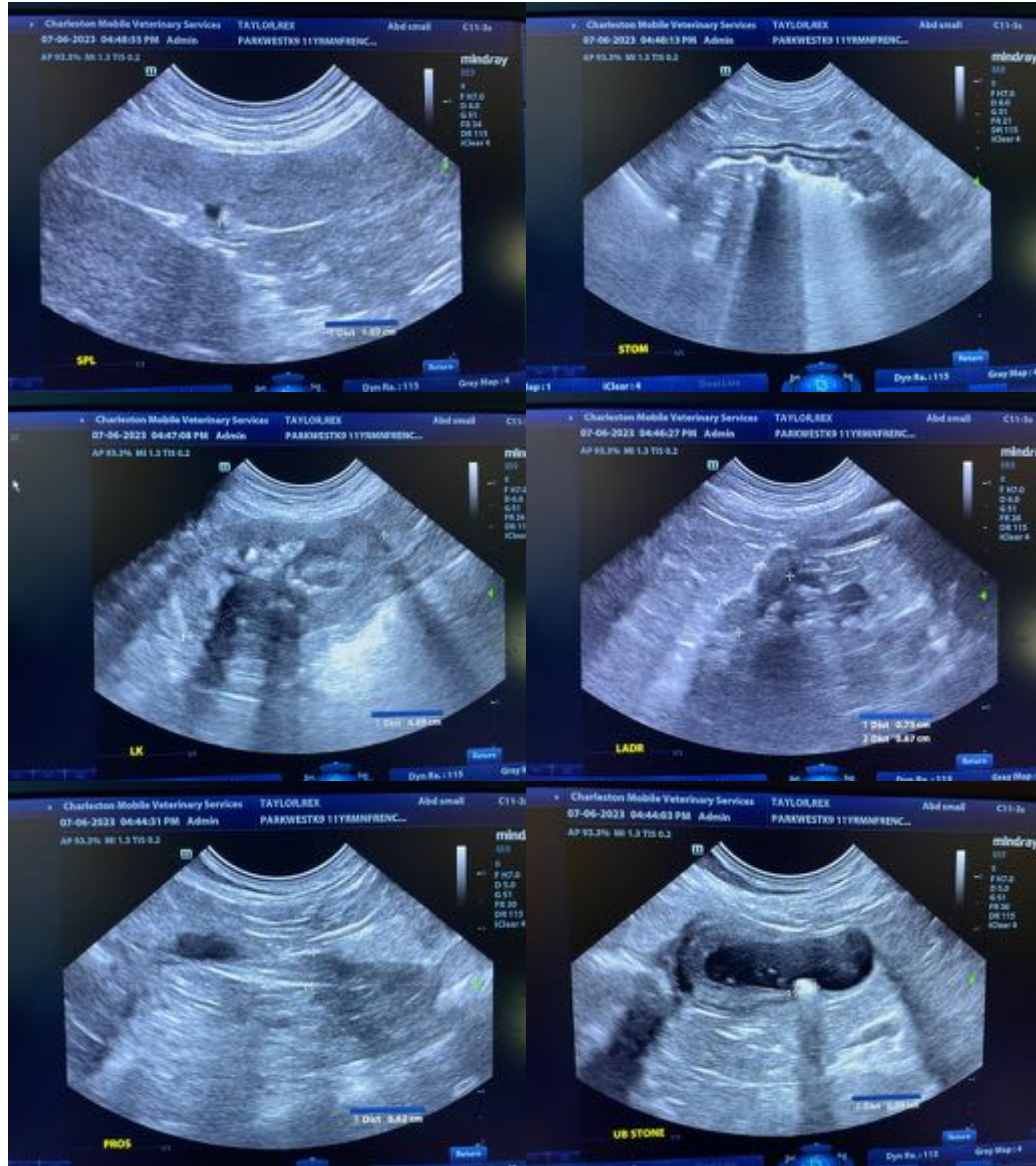
Dr. Butler

INVOICE

13577

DATE

6.7.23



The information and recommendations provided are based on the images presented by the referring veterinarian/sonographer. No evaluation can be communicated regarding pathology that was not visible in the image/video clips provided.

Thank you for this referral. If the clinical or image interpretation does not parallel your findings or if I can be of any further assistance, please contact me.

Andrea Nicastro, MPH, DVM, Diplomate DACVIM (Small Animal Internal Medicine)
info@SonoPath.com