**PATIENT PRESENTING CLINICAL SIGNS**

Jack Domagala History: Presented for coughing and an x-ray was taken and DVM noticed possible issues with liver due to appearance.

SPECIES

Canine

BREED

Maltese Mix

SEX

Neutered Male

AGE

13 years, 10 mos

WEIGHT

24.6 lbs

INTERPRETED BY

Andrea Nicastro,
DVM, Diplomate
ACVIM (Small Animal
Internal Medicine)

IMAGING PERFORMED BY

Carri Underwood

HOSPITAL NAME

SVS Imaging MI-2

REFERRING VET

Alsager Animal
Care Center

INVOICE

13891

DATE

7.28.23

Abnormal PE/Chem/CBC/UA Results: CBC- r. Hgb 22.7, Plt 563 Chem- Ca 13.9, CI 105, ALT 265, ALP 1408, GGT 38, CK 222 T4- 1.0 increased liver values, consistent with large, rounded appearance to liver on chest films taken yesterday for cough. Concern for neoplasia, liver dz Neoplasia, liver disease

ULTRASONOGRAPHIC EXAMINATION OF THE ABDOMEN**Urinary System**

The urinary bladder is moderately distended. The wall is normal in thickness. A small amount of gravity-dependent mineralized sand +/- tiny calculi is observed within the lumen. The region of the trigone and visible portion of the proximal urethra are normal.

The prostate is normal in size (0.63 cm in width) and shape. Parenchyma is homogenous. The prostatic urethra appears normal without evidence of dilation or obstruction.

The left kidney is normal in size (4.97 cm in length) with a normal shape, and smooth peripheral contours. The cortex is isoechoic relative to the spleen is thickened with a few pinpoint mineralized foci and at least one small cortical cyst. There is moderate loss of corticomedullary distinction. Hyperechoic shadowing diverticular foci are visualized. Several, small, nonobstructive nephroliths are seen. There is no evidence of pyelectasia, infarcts or hydroureter.

The right kidney is normal in size (4.51 cm in length) with a normal shape, and smooth peripheral contours. The cortex is isoechoic relative to the spleen is thickened with numerous pinpoint mineralized foci and at least one small cortical cyst. There is poor corticomedullary distinction. Hyperechoic shadowing diverticular foci are visualized. Several, small, nonobstructive nephroliths are seen. There is no evidence of pyelectasia, infarcts or hydroureter.

Adrenal Glands

The left adrenal gland is mildly enlarged (0.71 cm at cranial pole) (0.75 cm at caudal pole) with a slightly irregular shape. The parenchyma is subtly heterogenous with some loss of glandular detail. Surrounding vasculature appears normal.

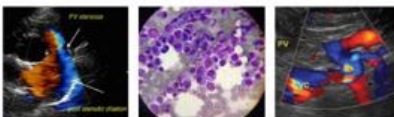
The right adrenal gland is enlarged (0.78 cm at cranial pole) (0.73 cm at caudal pole) with a slightly irregular shape. The parenchyma is subtly heterogenous with some loss of glandular detail. Surrounding vasculature appears normal.

Spleen

The spleen is normal in size (1.21 cm in width at the level of the hilus) with a normal capsular contour. There is appropriate echogenicity and echotexture. A 0.55 cm hyperechoic nodule is observed at the medial aspect adjacent to the hilus. Splenic vasculature is normal.

Liver

The liver is subjectively enlarged with swollen/irregular peripheral contours. The parenchyma is hyperechoic relative to the spleen and diffusely mottled, with numerous, varying-sized hypoechoic nodules/areas throughout the organ. In the region of the caudate process, a >8.00 cm ill-defined heterogenous mass effect with cavitations is seen. Hepatic vasculature and intrahepatic biliary tracts are of normal volume with no evidence of congestion.

**PATIENT**

Jack Domagala

The gall bladder lumen is moderately distended. The wall is thin and smooth. A moderate amount of echogenic debris is observed within the lumen (most of which is partially-dependent and some of which is suspended). The cystic and common bile ducts are normal/not seen.

SPECIES

Canine

Gastrointestinal

The stomach and intestine are free of stasis and exhibit normal peristaltic activity. The gastric lumen is not distended. The gastric wall and pylorus are normal in thickness with a normal layering pattern. The pyloric outflow tract is patent. The small intestinal lumen is not dilated. The small intestinal wall is normal in thickness with a normal layering pattern and appropriate mural detail. Discreet masses are not identified. The ileocecolic junction and colonic wall are normal. There is no evidence of an obstructive pattern.

BREED

Maltese Mix

SEX

Neutered Male

Pancreas

The pancreas is prominent in size with slightly irregular peripheral contours. The parenchyma is mildly hypoechoic relative to surrounding omental fat and subtly mottled in appearance. No distinct focal lesions are observed. The pancreatic duct is not overtly dilated.

AGE

13 years, 10 mos

Free Abdomen

There is no obvious evidence of free fluid. A 0.80 x 0.55 cm oval lymph node is observed in the right cranial quadrant.

WEIGHT

24.6 lbs

ULTRASONOGRAPHIC FINDINGS**INTERPRETED BY**

Andrea Nicastro,
DVM, Diplomate
ACVIM (Small Animal
Internal Medicine)

Primary Findings

- The hepatic changes, particularly in the region of the caudate process are concerning for a infiltrative neoplasia. Round cell neoplasia is the top differential. However, other neoplastic processes (i.e., adenocarcinoma, sarcoma) should also be considered. Other differentials include severe inflammatory disease, hepatotoxicosis (i.e., copper), vacuolar hepatopathy, regenerative nodular hyperplasia or some combination thereof.
- The prominent lymph node in the right cranial quadrant may represent reactive change or emerging neoplasia.

IMAGING PERFORMED BY

Carri Underwood

HOSPITAL NAME

SVS Imaging MI-2

Secondary Findings

- Gall bladder debris, non-mucocele
- The bilateral renal changes are consistent with chronic interstitial nephrosis/nephritis with nonobstructive nephrocalcinosis and cortical cysts.
- Bilateral adrenomegaly
- The hyperechoic splenic nodule is most consistent with a benign process (i.e., myelolipoma) with a low possibility of emerging neoplasia.
- The pancreatic changes are most consistent with age-related parenchymal remodeling, potentially secondary to a prior inflammatory episode, early fibrosis or chronic pancreatitis.
- Urinary bladder sand +/- tiny cystic calculi

REFERRING VET

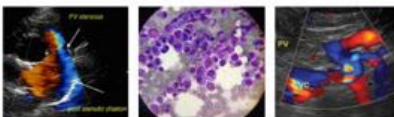
Alsager Animal
Care Center

INVOICE

13891

DATE

7.28.23



PATIENT INTERPRETATION OF THE FINDINGS & FURTHER RECOMMENDATIONS

Jack Domagala

SPECIES

Canine

BREED

Maltese Mix

SEX

Neutered Male

AGE

13 years, 10 mos

WEIGHT

24.6 lbs

INTERPRETED BY

Andrea Nicastro,
DVM, Diplomate
ACVIM (Small Animal
Internal Medicine)

IMAGING PERFORMED BY

Carri Underwood

HOSPITAL NAME

SVS Imaging MI-2

REFERRING VET

Alsager Animal
Care Center

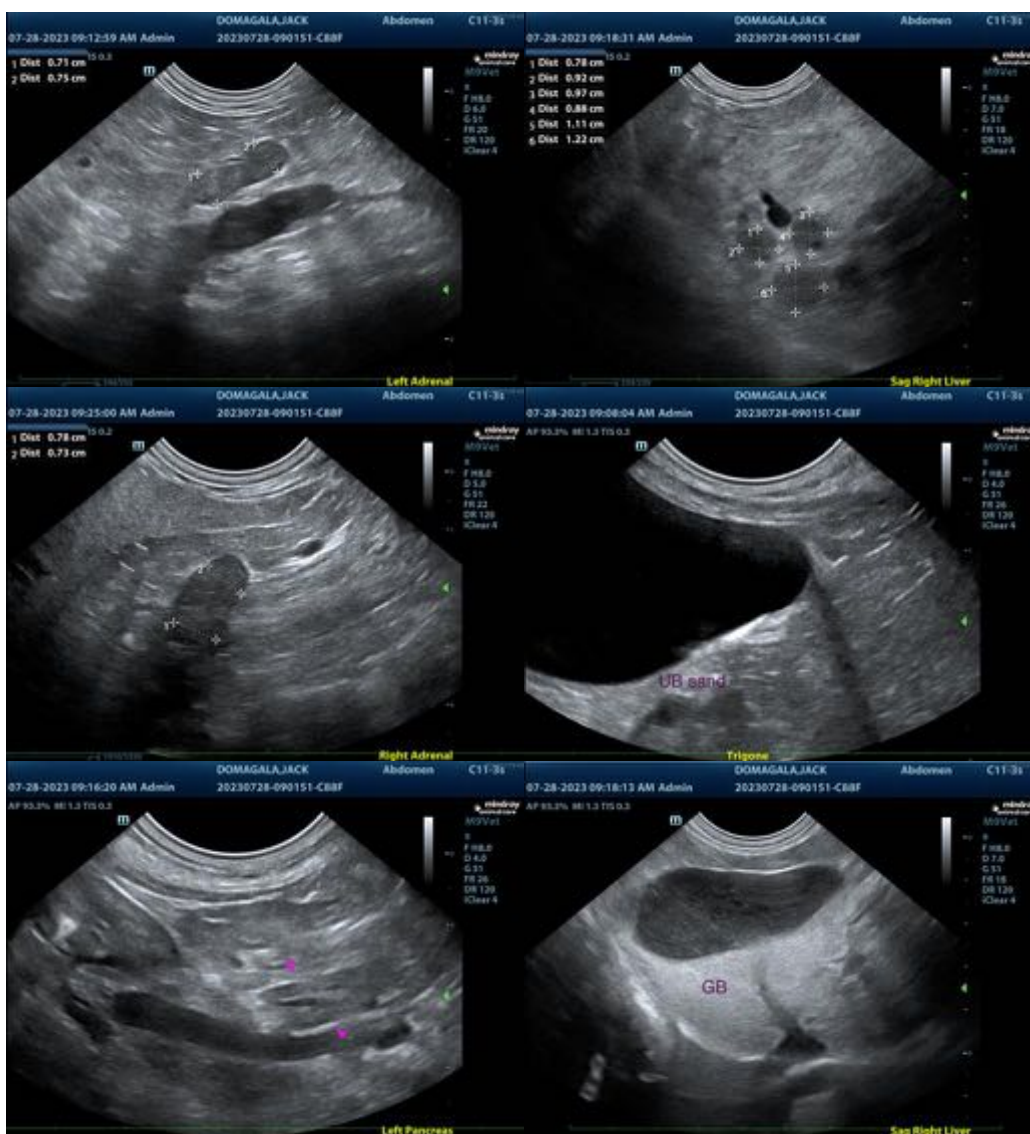
INVOICE

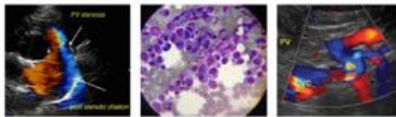
13891

DATE

7.28.23

- Fine-needle aspirates of the liver with particular attention to the caudate process are recommended (if clotting status is appropriate). Twenty-five gauge-needles should be used. If the cytology results are inconclusive, laparoscopic, or surgical GI biopsies may be necessary to get a definitive diagnosis.
- Given the hypercalcemia, consider a PTH/PTHrP/ionized calcium.





PATIENT

Jack Domagala

SPECIES

Canine

BREED

Maltese Mix

SEX

Neutered Male

AGE

13 years, 10 mos

WEIGHT

24.6 lbs

INTERPRETED BY

Andrea Nicastro,
DVM, Diplomate
ACVIM (Small Animal
Internal Medicine)

**IMAGING
PERFORMED BY**

Carri Underwood

HOSPITAL NAME

SVS Imaging MI-2

REFERRING VET

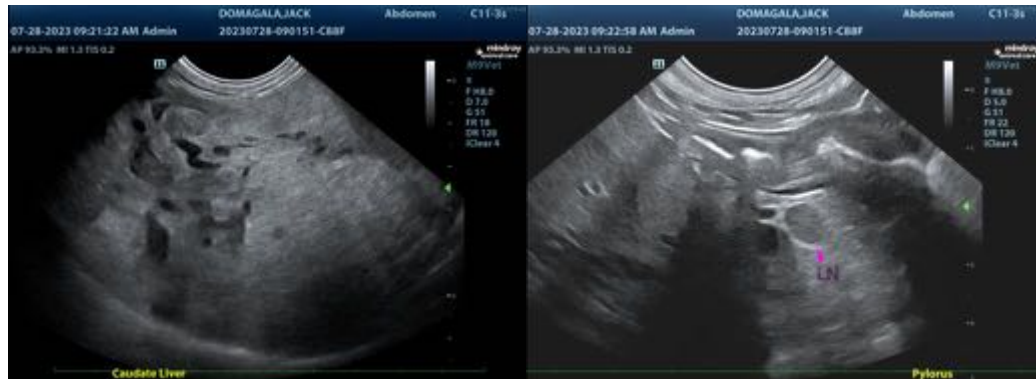Alsager Animal
Care Center

INVOICE

13891

DATE

7.28.23



The information and recommendations provided are based on the images presented by the referring veterinarian/sonographer. No evaluation can be communicated regarding pathology that was not visible in the image/video clips provided.

Thank you for this referral. If the clinical or image interpretation does not parallel your findings or if I can be of any further assistance, please contact me.

Andrea Nicastro, MPH, DVM, Diplomate DACVIM (Small Animal Internal Medicine)
info@SonoPath.com