

**DATE PRESENTING CLINICAL SIGNS**

7.27.23 P presents for decreased appetite, vomiting and weight loss.

PATIENT

Kato Eichhammer

Current Medications: Dep inj 20mg, Cerenia inj, Fluids SQ, Mirataz ointment.
 Date of Previous IntraPet Ultrasound: No previous.
 Sedation: Not required to complete full diagnostic ultrasound.
 Stat Report: Not requested.
 Imaging Performed By: Stephanie Warga RDCS, RVT.

SPECIES

Feline

BREED

Siamese

SEX

Neutered Male

AGE

12/17/2014

WEIGHT

9.4 lbs

INTERPRETED BY

Andrea Nicastro, DMV,
 Diplomate DACVIM
 (Small Animal
 Internal Medicine)

HOSPITAL NAME

Northwind AH

REFERRING VET

Dr. Cross

INVOICE

13864

ULTRASONOGRAPHIC EXAMINATION OF THE ABDOMEN**Urinary System**

The urinary bladder wall is normal in thickness and the mucosal surface is smooth. The bladder is mildly distended. A scant amount of suspended echogenic debris is observed within the lumen. No cystic calculi are observed. The region of the trigone and visible portion of the proximal urethra are normal.

The left kidney is normal in size (4.25 cm in length) with a normal shape, architecture and smooth peripheral margins. The cortex is isoechoic relative to the spleen. There is a normal 1:3 cortex to medulla ratio with minimal to mild loss of corticomedullary distinction. There is no evidence of pyelectasia, nephroliths, infarcts or hydronephrosis. Renal vasculature is normal.

The right kidney is normal in size (4.14 cm in length) with a normal shape, architecture and smooth peripheral margins. The cortex is isoechoic relative to the spleen. There is a normal 1:3 cortex to medulla ratio with minimal to mild loss of corticomedullary distinction. There is no evidence of pyelectasia, nephroliths, infarcts or hydronephrosis. Renal vasculature is normal.

Adrenal Glands

The left adrenal gland is normal size (0.32 cm width). Normal shape and glandular echogenicity. The phrenicoabdominal vein and surrounding vasculature are normal.

The right adrenal gland is normal size (0.32 cm width). Normal shape and glandular echogenicity. The phrenicoabdominal vein and surrounding vasculature are normal.

Spleen

The spleen is normal in size (0.81 cm in width at the level of the hilus) with a normal capsular contour. There is appropriate echogenicity and echotexture. No focal lesions are observed. Splenic vasculature is normal.

Liver

The liver is subjectively normal in size with normal contours and structure. There is appropriate echogenicity and echotexture. No overt structural evidence of inflammatory, infiltrative, or regenerative pathology is evident. Vascular and biliary tracts are of normal volume with no evidence of congestion. No pathological hepatic lymphadenopathy observed. The portal vein to caudal vena cava ratio is approximately 1: 1.

The gall bladder lumen is moderately distended. The wall is thin and smooth. A moderate amount of partially dependent, echogenic debris is observed within the lumen. The cystic and common bile ducts are visible/tortuous, but not overtly dilated. The common bile duct measures 0.28 cm in diameter at its distal aspect. The duodenal papilla is normal in size (0.41 cm in width). There is no obvious evidence of an intraluminal obstruction.

Gastrointestinal

The gastric lumen is not distended. The gastric wall and pylorus are normal in thickness with a normal layering pattern. The pyloric outflow tract is patent. The small intestinal wall is diffusely thickened (up to 0.29 cm). There is disruption in the normal 1:3 muscularis: mucosal ratio, with a 1:1 ratio in several segments. An approximately 1.50-2.00 cm focal bowel mass is observed in the jejunum. The wall in this region is severely thickened (up to 0.80 cm) and hypoechoic with loss of the normal layering pattern. The lumen appears strictured in this area. The mesentery effacing the serosal surface of the mass is mildly hyperechoic. Orad to the mass, the small intestinal lumen is moderate distended with chyme. Distal to the lesion, the lumen is empty. The ileocecolic junction and colonic wall are normal.

Pancreas

The region of the pancreas is isoechoic relative to surrounding omental fat. No obvious parenchymal abnormalities are observed. There is no evidence of regional inflammation or effusion.

Free Abdomen

The mesentery in the cranial- to midabdominal is mildly hyperechoic. Trace free fluid is observed. A 1.46 x 0.43 cm lymph node is observed adjacent to the small intestinal mass.

ULTRASONOGRAPHIC FINDINGS

Primary Findings

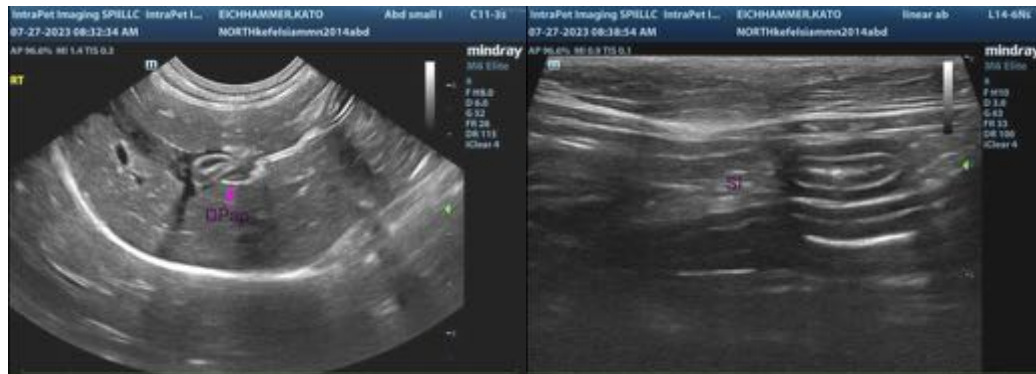
- Focal small intestinal mass with suspected stricture and partial luminal obstruction. Neoplasia (i.e., lymphoma, adenocarcinoma) is suspected with a lower possibility of a focal inflammatory process (i.e., pyogranulomatous). Adjacent peritonitis is present. The prominent regional lymph node may represent metastatic disease or reactive change. The diffuse small intestinal wall changes could be consistent with emerging lymphoma or inflammatory bowel disease.

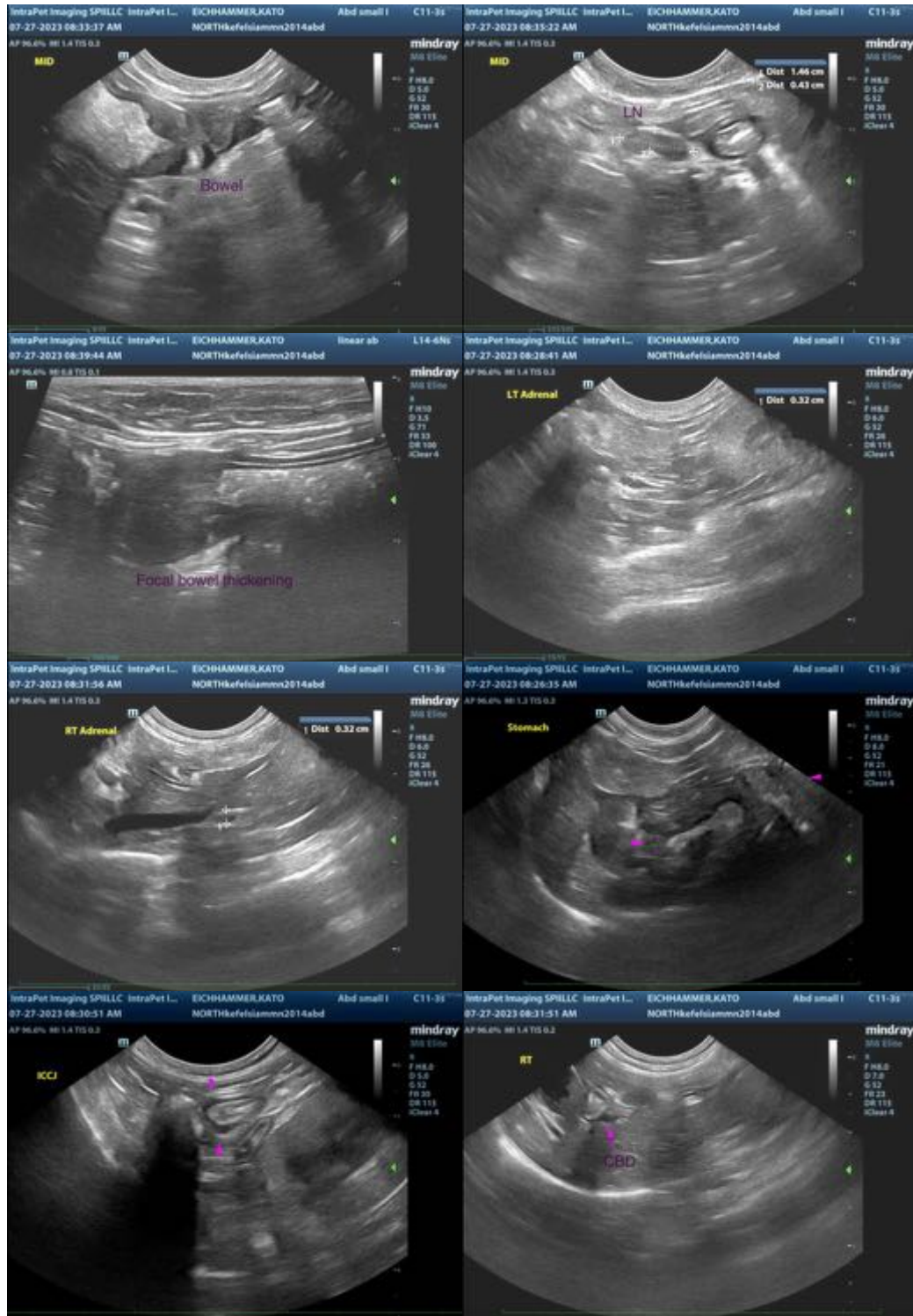
Secondary Findings

- Bilateral chronic age-related renal changes

INTERPRETATION OF THE FINDINGS & FURTHER RECOMMENDATIONS

- Three-view thoracic radiographs are recommended to assess for pulmonary metastases.
- Consider fine-needle aspiration of the focal small intestinal mass (if clotting status is appropriate). However, surgical resection of the mass with anastomosis may be the preferred option due to the likelihood of at least partial luminal obstruction. The mass and associated lymph node should be submitted for histopathology.





The information and recommendations provided are based on the images presented by the referring veterinarian/sonographer. No evaluation can be communicated regarding pathology that was not visible in the image/video clips provided.

Thank you for this referral. If the clinical or image interpretation does not parallel your findings or if I can be of any further assistance, please contact me.

Andrea Nicastro, MPH, DVM, Diplomate DACVIM (Small Animal Internal Medicine)
info@SonoPath.com