



PATIENT PRESENTING CLINICAL SIGNS

Negri Abreu

History: Presented for an abdominal ultrasound to evaluate the bladder. Patient presented for evaluation as noticed anxious, going to litter box often, but no urine was seen, urinated once outside litter box no blood appreciated. PT cont with good behavior eating well eats urinary SO sibling had bladder stones sx . Pt does not have any previous Urinary condition. previous quick scan hyperechoic structure attached to bladder wall R/O blood clot vs calculi vs mass

SPECIES

Feline

Abnormal PE/Chem/CBC/UA Results: Diagnostics done: 6-3-22 CBC: WNL CHEM:WNL Urinalysis: normal usg: 1.040 Radiograph: no stone or dilation noted

BREED

DSH

ULTRASONOGRAPHIC EXAMINATION OF THE ABDOMEN

Urinary System

The **urinary bladder** is moderately distended. The wall is normal in thickness with a smooth mucosal surface. A small to moderate amount of suspended echogenic debris is observed within the lumen, as well as a small amount of gravity dependent, mineralized sand. No distinct calculi are observed. The cystourethral junction and the visible portion of the proximal urethra are normal.

AGE

14 years

The **left kidney** is normal size (3.52 cm in length); normal shape and architecture with smooth peripheral margins. There is a normal 1:3 cortex to medulla ratio with mild loss of corticomedullary distinction. There is no evidence of pyelectasia, nephroliths, infarcts or hydroureter.

WEIGHT

10.5 lbs

The **right kidney** is normal size (3.85 cm in length); normal shape and architecture with smooth peripheral margins. There is a normal 1:3 cortex to medulla ratio with mild loss of corticomedullary distinction. There is no evidence of pyelectasia, nephroliths, infarcts or hydroureter.

Adrenal Glands

The **left adrenal gland** is normal size (0.28 cm width). Normal shape and glandular echogenicity. The phrenicoabdominal vein and surrounding vasculature are normal.

The **right adrenal gland** is normal size (0.26 cm width). Normal shape and glandular echogenicity. The phrenicoabdominal vein and surrounding vasculature are normal.

Spleen

The **spleen** is prominent in size (1.01 cm in width at the level of the hilus) with normal curvilinear peripheral contours. There is appropriate echogenicity and echotexture. No focal lesions are observed. Splenic vasculature is normal.

Liver

The **liver** is subjectively normal in size with normal contours and is isoechoic relative to the spleen. There is appropriate echogenicity and echotexture. No overt structural evidence of inflammatory, infiltrative, or regenerative pathology is evident. Vascular and biliary tracts are of normal volume with no evidence of congestion. No pathological hepatic lymphadenopathy observed.

The **gall bladder** is moderately distended. The wall is normal in thickness. A small amount of aggregated, echogenic, partially dependent debris/sludge is observed within the lumen. Luminal contents are anechoic. The cystic and common bile ducts are normal/not seen. The cystic and common bile ducts are visible/tortuous, but not overtly dilated.

INVOICE Gastrointestinal

11269

The **stomach and intestine** are free of stasis and exhibit normal peristaltic activity. The gastric lumen is not distended. The gastric wall and pylorus are normal in thickness with a normal layering pattern. The pyloric outflow tract is patent. The small intestinal lumen is not dilated. The small intestinal wall thickness is normal to borderline thickened (up to 0.26 cm) with a normal layering pattern and appropriate mural detail. There is disruption in the normal 1:3 muscularis: mucosal ratio in

DATE

7.27.22

INTERPRETED BY

Andrea Nicastro, DVM,
Diplomate ACVIM
(Small Animal Internal
Medicine)

IMAGING PERFORMED BY

Dr. G. Ferrer DVM

HOSPITAL NAME

Paseos VC

REFERRING VET

Dr. Jenniffer Walker
Diaz DVM



PATIENT

Negri Abreu

most segments. Discreet masses are not identified. The ileocecal colic junction and colonic wall are normal. No obstructive disease is noted.

SPECIES

Feline

Pancreas

The region of the **pancreas** is isoechoic relative to surrounding omental fat. No obvious parenchymal abnormalities are observed. There is no evidence of regional inflammation or effusion.

BREED

DSH

Free Abdomen

There is no evidence of free fluid. A 1.60 cm medial iliac lymph node is visualized. One to two prominent mesenteric lymph nodes are also seen, the largest measuring 2.05 cm in length.

ULTRASONOGRAPHIC FINDINGS

Primary Findings

- Urinary bladder sand/debris

Secondary Findings

- Bilateral, nonspecific age-related renal changes
- The small intestinal wall changes are consistent with inflammatory bowel disease, with some potential for emerging lymphoma. However, correlation with clinical history is recommended.
- The lymph node changes are most consistent with reactive lymphadenitis or lymphoid hyperplasia.
- Hepatic changes are non-specific and could be consistent with hepatic lipidosis, inflammatory/infectious disease, infiltrative neoplasia, other hepatopathy or normal variant.
- The mild splenomegaly may be a normal variant for this patient or may be secondary to lymphoid hyperplasia, extramedullary hematopoiesis, splenitis, antigenic stimulation, or less likely, emerging neoplasia (i.e., lymphoma).

AGE

14 years

WEIGHT

10.5 lbs

INTERPRETED BY

Andrea Nicastro, DVM,
Diplomate ACVIM
(Small Animal Internal
Medicine)

IMAGING PERFORMED BY

Dr. G. Ferrer DVM

HOSPITAL NAME

Paseos VC

REFERRING VET

Dr. Jenniffer Walker
Diaz DVM

INVOICE

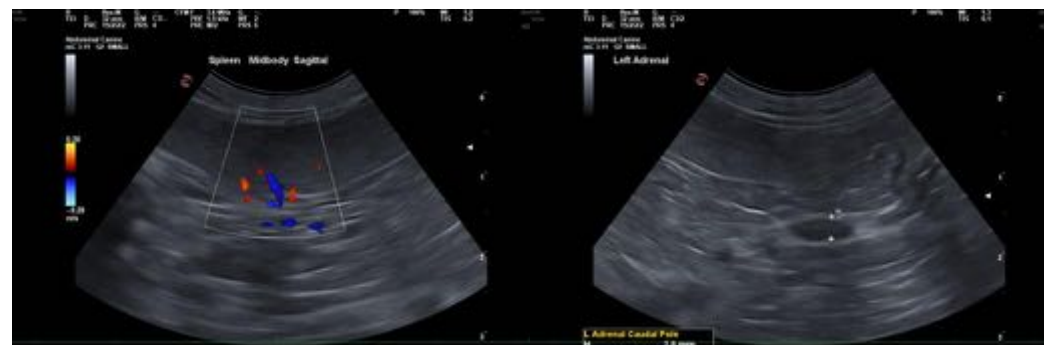11269

DATE

7.27.22

INTERPRETATION OF THE FINDINGS & FURTHER RECOMMENDATIONS

A urine culture and sensitivity is recommended. If the culture is negative, consider empirical treatment for feline idiopathic cystitis.





PATIENT

Negri Abreu

SPECIES

Feline

BREED

DSH

SEX

Spayed Female

AGE

14 years

WEIGHT

10.5 lbs

INTERPRETED BY

Andrea Nicastro, DVM,
Diplomate ACVIM
(Small Animal Internal
Medicine)

**IMAGING
PERFORMED BY**

Dr. G. Ferrer DVM

HOSPITAL NAME

Paseos VC

REFERRING VET

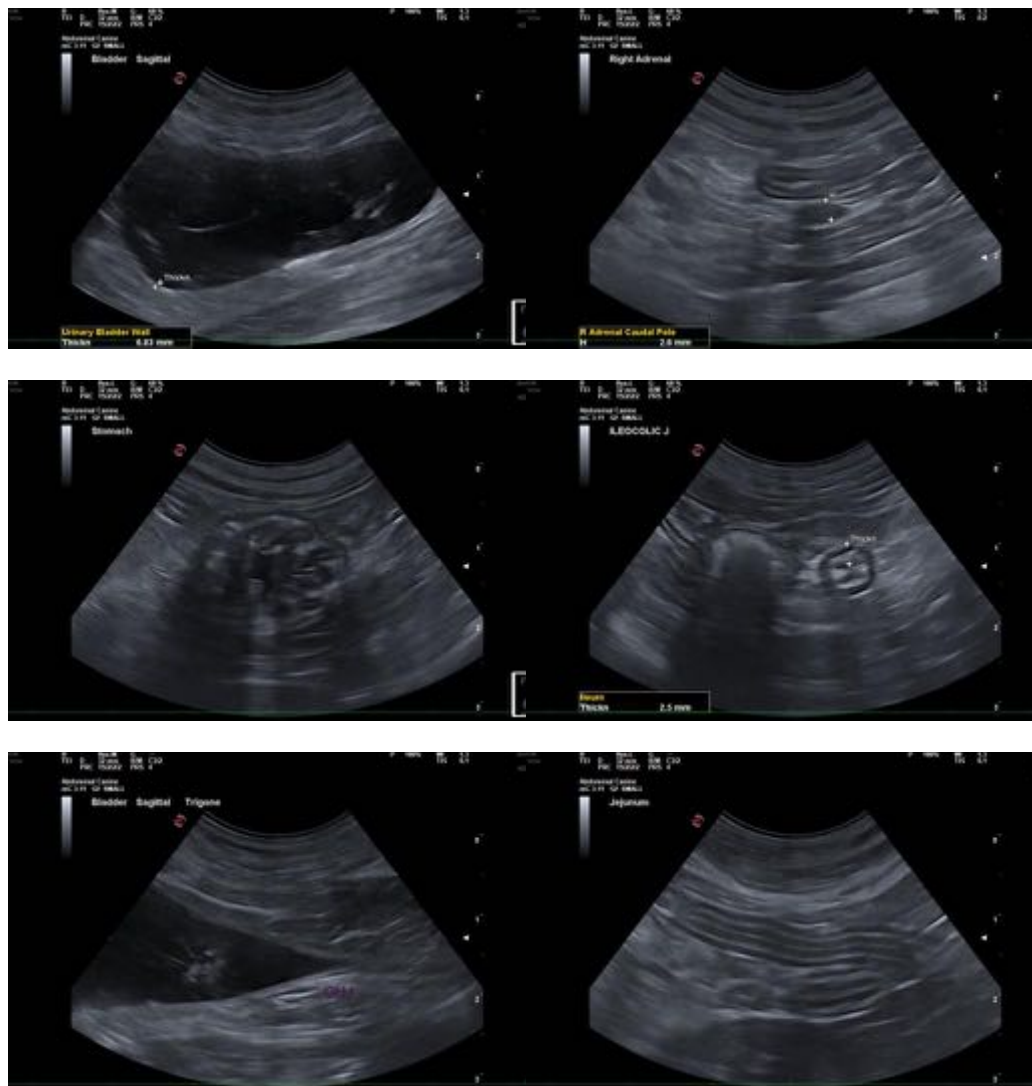
Dr. Jenniffer Walker
Diaz DVM

INVOICE

11269

DATE

7.27.22



The information and recommendations provided are based on the images presented by the referring veterinarian/sonographer. No evaluation can be communicated regarding pathology that was not visible in the image/video clips provided.

Thank you for this referral. If the clinical or image interpretation does not parallel your findings or if I can be of any further assistance, please contact me.

Andrea Nicastro, MPH, DVM, Diplomate DACVIM (Small Animal Internal Medicine)
info@SonoPath.com