**PATIENT**Bella Wiedmer  
51305A**SPECIES**

Canine

**BREED**

Goldendoodle

**SEX**

Spayed Female

**AGE**

10 years

**WEIGHT**

31.5 kg

**INTERPRETED BY**Andrea Nicastro,  
DVM, Diplomate  
ACVIM (*Small Animal  
Internal Medicine*)**IMAGING  
PERFORMED BY**

Tom McNeill

**HOSPITAL NAME**

SVS Imaging CT

**REFERRING VET**Madison Veterinary  
Specialists-Dr.  
Silbernagel**INVOICE**

11291

**DATE**

7.26.22

**PRESENTING CLINICAL SIGNS**

History: Hypercalcemia incidentally noted on routine blood work at pcDVM about 1 year ago.

Abnormal PE/Chem/CBC/UA Results: Michigan State hypercalcemia panel: High Parathyroid Hormone (CLIA) 23.30, elevated Ionized Calcium 1.69, Normal Parathormone Related Protein

CBC &amp; Chem: Calcium 14.9 (8.9-11.4), Chol 373 (92-324), otherwise NSF

**ULTRASONOGRAPHIC EXAMINATION OF THE CERVIX****Cervical region**

Left thyroid gland (2.98 x .047 cm): 0.60 x 0.52 cm hypoechoic nodule cranially (enlarged parathyroid gland); 0.12 x 0.15 hypoechoic nodule mid-gland)

Right thyroid gland (2.54 x 0.38 cm): 0.33 x 0.12 cm hypoechoic nodule mid-gland

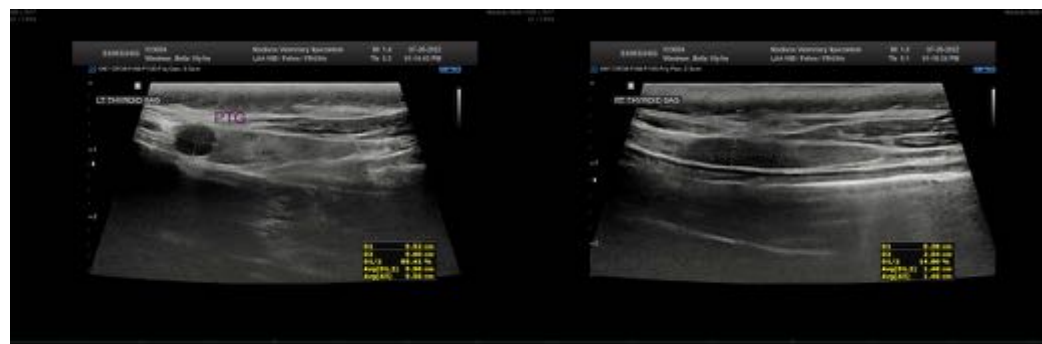Still images of the mandibular salivary glands, mandibular/retropharyngeal lymph nodes are unremarkable

**ASSESSMENT****Primary Findings**

Primary hyperparathyroidism with an enlarged left parathyroid gland/nodule (differentials include adenoma, adenocarcinoma, hyperplasia) at cranial aspect of left thyroid lobe

**INTERPRETATION OF THE FINDINGS & FURTHER RECOMMENDATIONS**

A left parathyroidectomy is recommended. Three-view chest radiographs are recommended prior to surgery.



IMAGING PERFORMED BY

svsimagingqc.net 309-737-3070



Clinical Sonography & Telectology

EDUCATIONAL TELECONSULTATION SERVICES™

1-800-838-4268 info@sonopath.com SonoPath.com

**PATIENT**

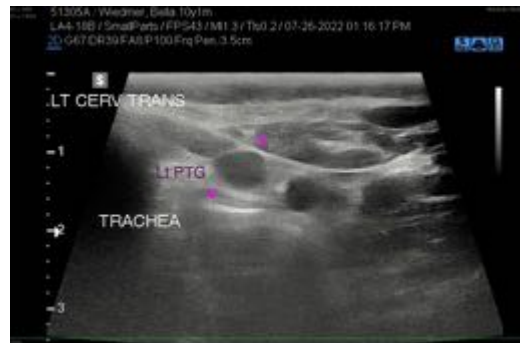
Bella Wiedmer  
51305A

**SPECIES**

Canine

**BREED**

Goldendoodle



**SEX**

Spayed Female

**AGE**

10 years

**WEIGHT**

31.5 kg

**INTERPRETED BY**

Andrea Nicastro,  
DVM, Diplomate  
ACVIM (Small Animal  
Internal Medicine)

**IMAGING  
PERFORMED BY**

Tom McNeill

**HOSPITAL NAME**

SVS Imaging CT

**REFERRING VET**

Madison Veterinary  
Specialists-Dr.  
Silbernagel

**INVOICE**

11291

**DATE**

7.26.22

The information and recommendations provided are based on the images presented by the referring veterinarian/sonographer. No evaluation can be communicated regarding pathology that was not visible in the image/video clips provided.

Thank you for this referral. If the clinical or image interpretation does not parallel your findings or if I can be of any further assistance, please contact me.

**Andrea Nicastro, DVM, Diplomate DACVIM (Small Animal Internal Medicine)**  
info@SonoPath.com