



PATIENT PRESENTING CLINICAL SIGNS

Hazel Torres Decreased appetite starting 2 days ago. Vomiting and diarrhea starting yesterday. Lethargic, trembling and panting.

SPECIES Abnormal PE/Chem/CBC/UA Results: Elevated WBC (neutrophils, Lymphs, Mono, Eos); Elevated SDMA, creatinine, BUN, phos, Globulin, ALT, ALP, decreased chloride

Canine

ULTRASONOGRAPHIC EXAMINATION OF THE ABDOMEN

BREED *Urinary System*

Pharaoh Hound Mix

The **urinary bladder** wall is normal in thickness and the mucosal surface is smooth. The bladder lumen is moderately distended with anechoic urine. No masses, inflammatory changes or calculi are observed. The region of the trigone is normal.

SEX

Spayed Female

The **left kidney** is normal size (6.20 cm in length); normal shape and architecture with smooth peripheral margins. There is a normal 1:3 cortex to medulla ratio with minimal to mild loss of corticomedullary distinction. There is no evidence of pyelectasia, nephroliths, infarcts or hydroureter.

AGE

13 years 5 mos

The **right kidney** is normal size (6.92 cm in length); normal shape and architecture with smooth peripheral margins. There is a normal 1:3 cortex to medulla ratio with mild loss of corticomedullary distinction. There is no evidence of pyelectasia, nephroliths, infarcts or hydroureter.

Adrenal Glands

WEIGHT

47.5 lbs

The **left adrenal gland** is upper limits of normal size (0.70 cm at cranial pole) (0.80 cm at caudal pole); normal shape; homogenous parenchyma. The glandular echogenicity and detail are unremarkable. Capsule, cortex, and medullary definition are normal. The phrenicoabdominal vein and surrounding vasculature are normal.

INTERPRETED BY

Andrea Nicastro,
DVM, Diplomate
ACVIM (*Small Animal
Internal Medicine*)

The region of the **right adrenal gland** is evaluated. No obvious pathology is observed.

Spleen

The **spleen** is normal in size (2.09 cm in width at the level of the hilus) with a normal capsular contour. There is appropriate echogenicity and echotexture. No focal lesions are observed. Splenic vasculature is normal.

IMAGING PERFORMED BY

Samantha L Hudgins,
DVM

Liver

The **liver** is subjectively normal in size with normal contours and structure. There is appropriate echogenicity and echotexture. No overt structural evidence of inflammatory, infiltrative, or regenerative pathology is evident. Vascular and biliary tracts are of normal volume with no evidence of congestion. No pathological hepatic lymphadenopathy observed.

HOSPITAL NAME

Petvacx AH

The **gall bladder** lumen is moderately distended. The wall is thin and smooth. Luminal contents are anechoic. The cystic and common bile ducts are normal/not seen.

REFERRING VET

Dr. Anna Jacob, DVM

Gastrointestinal

The **gastric lumen** is mildly fluid-distended and hypomotile. The gastric wall and pylorus are normal in thickness with a normal layering pattern. The pyloric outflow tract appears patent. The small intestinal lumen is segmentally dilated with chyme (mild). The small intestinal wall is normal in thickness with a normal layering pattern and appropriate mural detail. Discreet masses are not identified. The lumen of the descending colon is moderate to severely distended with fluid. There is no obvious evidence of an obstructive pattern.

INVOICE

11254

DATE

7.21.22

Pancreas

The region of the **pancreas** is isoechoic relative to surrounding omental fat. No obvious parenchymal abnormalities are observed. There is no evidence of regional inflammation or effusion.

Free Abdomen

The **peritoneal cavity** is normal. There is no evidence of inflammation or effusion. The abdominal **lymph nodes** are normal/not visible.

ULTRASONOGRAPHIC FINDINGS

Primary Findings

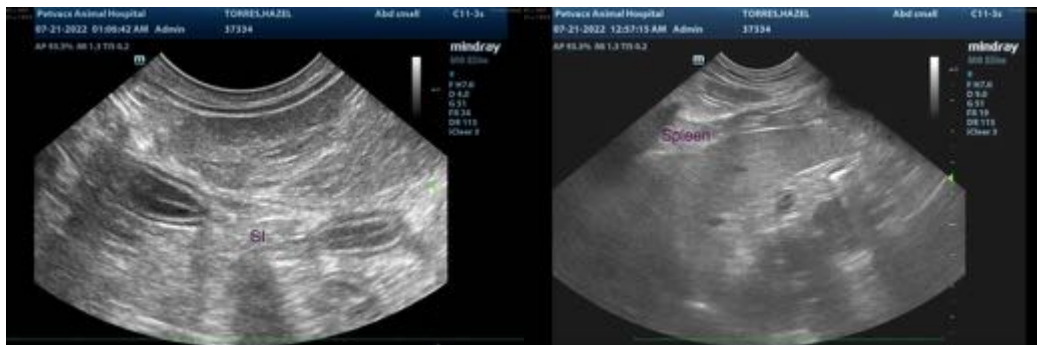
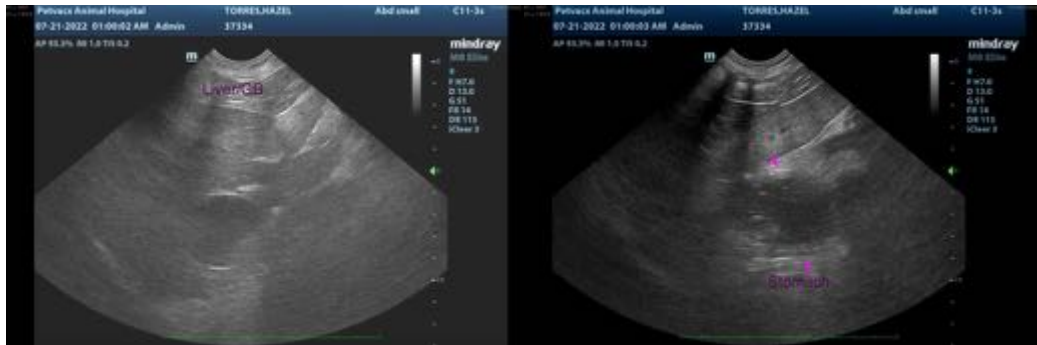
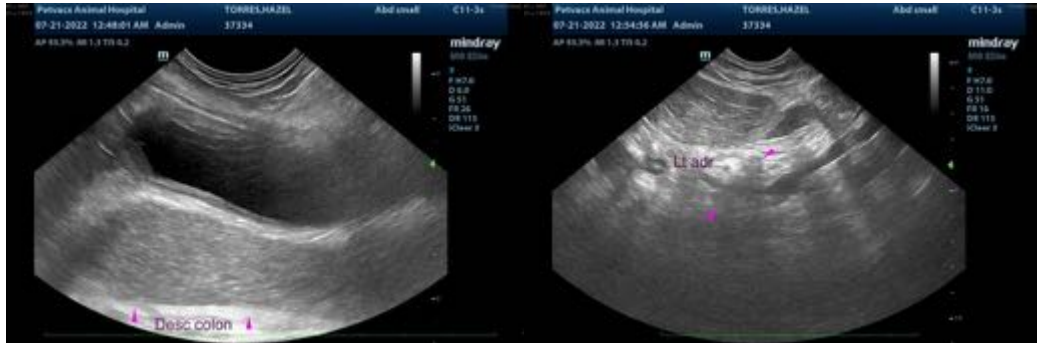
- Mild gastrointestinal ileus with fluid-distended colon

Secondary Findings

- Minor age-related renal changes

INTERPRETATION OF THE FINDINGS & FURTHER RECOMMENDATIONS

- Given the azotemia and elevated liver enzymes, consider Leptospirosis testing (i.e., blood and urine PCR, serology).
- Regarding the azotemia, consider the following:
 1. Urinalysis
 2. Urine culture and sensitivity
 3. UPC (if proteinuria is present)
 4. Baseline blood pressure measurement
 5. Transition to a prescription renal diet when the patient is stabilized (if tolerated)
- Depending on the liver enzyme pattern, the following diagnostics can be considered:
 1. Pre-and postprandial serum bile acids
 2. Hepatic tissue sampling (i.e., fine-needle aspirate or surgical biopsy). Surgical biopsies are more likely to yield a definitive diagnosis. If pursued, aerobic and anaerobic bile cultures, as well as acquisition of additional hepatic tissue samples for potential copper quantitation are recommended.
 3. If a conservative approach is desired, consider empirical treatment for bacterial cholangiohepatitis (amoxicillin-clavulanic acid, +/-metronidazole, Denamarin). If no improvement in the liver values is seen within 7-10 days of initiating therapy, antibiotics should be discontinued, and hepatic tissue sampling reconsidered. If liver values improve, continue therapy for at least 4-6 weeks and 1 week beyond normalization of the liver values.
- Given the patient's age and history of vomiting, thoracic radiographs are recommended to assess for occult aspiration pneumonia.



The information and recommendations provided are based on the images presented by the referring veterinarian/sonographer. No evaluation can be communicated regarding pathology that was not visible in the image/video clips provided.

Thank you for this referral. If the clinical or image interpretation does not parallel your findings or if I can be of any further assistance, please contact me.

Andrea Nicastro, DVM, Diplomate DACVIM (Small Animal Internal Medicine)
info@SonoPath.com