



PATIENT PRESENTING CLINICAL SIGNS

Edgrr Britts History: trachea collapse and recent onset of dyspnea. Chronic cough. Is currently oxygendependent.

SPECIES ULTRASONOGRAPHIC EXAMINATION OF THE ABDOMEN

Canine **Urinary System**

BREED The urinary bladder wall is normal in thickness and the mucosal surface is smooth. The bladder is distended. A scant amount of suspended echogenic debris is observed within the lumen. No cystic calculi are observed. The region of the trigone and visible portion of the proximal urethra are normal.

Yorkshire Terrier

SEX The prostate is enlarged (2.47 cm in width) with smooth curvilinear peripheral contours. The parenchyma is mildly hyperechoic relative to surrounding omental fat and subtly mottled in appearance. No distinct focal lesions are observed. The prostatic urethra is not overtly dilated.

Neutered Male

AGE The left kidney is normal in size (3.62 cm in length) with a normal shape, smooth peripheral margins, and normal internal architecture. There is mild loss of corticomedullary distinction. Several hyperechoic shadowing diverticular foci are observed. There is no evidence of pyelectasia, infarcts or hydronephrosis. Renal vasculature is normal.

6.7.2009

WEIGHT The right kidney is normal in size (3.05 cm in length) with a normal shape, smooth peripheral margins, and normal internal architecture. There is mild loss of corticomedullary distinction. Several hyperechoic shadowing diverticular foci are observed. There is no evidence of pyelectasia, infarcts or hydronephrosis. Renal vasculature is normal.

2.48 kg

INTERPRETED BY

Andrea Nicastro, DVM,
Diplomate ACVIM (*Small Animal Internal Medicine*)

IMAGING PERFORMED BY

Andrea Nicastro, DVM,
Diplomate ACVIM (*Small Animal Internal Medicine*)

HOSPITAL NAME

Blue Pearl MP ER

REFERRING VET

Dr. Shannon Graham

INVOICE

13759

DATE

7.20.23

Adrenal Glands

The left adrenal gland is normal in size (0.39 cm at cranial pole) (0.39 cm at caudal pole) with a normal shape and homogenous parenchyma. The glandular echogenicity and detail are unremarkable. Capsule, cortex, and medullary definition are normal. The phrenicoabdominal vein and surrounding vasculature are normal.

The right adrenal gland is in normal size (0.76 cm at cranial pole) (0.50 cm at caudal pole) with a normal shape and homogenous parenchyma. The glandular echogenicity and detail are unremarkable. Capsule, cortex, and medullary definition are normal. The phrenicoabdominal vein and surrounding vasculature are normal.

Spleen

The spleen is normal in size (0.80 cm in width at the level of the hilus) with a normal capsular contour. There is appropriate echogenicity and echotexture. No focal lesions are observed. Splenic vasculature is normal.

Liver

The liver is subjectively enlarged with swollen peripheral contours. The parenchyma is hyperechoic relative to the spleen. Several, varying-sized hypoechoic-to-heterogenous nodules are observed throughout the organ (the largest measuring 1.19 cm in its longest dimension). Hepatic vasculature is dilated. Intrahepatic biliary tracts are normal.

The gall bladder is distended. The wall is thickened (up to 0.31 cm) and hypoechoic ("halo" sign). A moderate amount of aggregated, echogenic debris is observed within the lumen (most of which is partially dependent, and some of which is suspended). The cystic and common bile ducts are normal/not seen.

Gastrointestinal

The stomach and intestine are free of stasis and exhibit normal peristaltic activity. The gastric lumen is not distended. The gastric wall and pylorus are normal in thickness with a normal layering pattern. The pyloric



PATIENT

Edgrr Britts

SPECIES

Canine

BREED

Yorkshire Terrier

SEX

Neutered Male

AGE

6.7.2009

WEIGHT

2.48 kg

INTERPRETED BY

Andrea Nicastro, DVM,
Diplomate ACVIM (*Small
Animal Internal Medicine*)

**IMAGING
PERFORMED BY**

Andrea Nicastro, DVM,
Diplomate ACVIM (*Small
Animal Internal Medicine*)

HOSPITAL NAME

Blue Pearl MP ER

REFERRING VET

Dr. Shannon Graham

INVOICE

13759

DATE

7.20.23

outflow tract is patent. The small intestinal lumen is not dilated. The small intestinal wall is normal in thickness with a normal layering pattern and appropriate mural detail. Discreet masses are not identified. The ileocecolic junction and colonic wall are normal. There is no evidence of an obstructive pattern.

Pancreas

The region of the pancreas is isoechoic relative to surrounding omental fat. No obvious parenchymal abnormalities are observed. There is no evidence of regional inflammation or effusion.

Free Abdomen

The peritoneal cavity is normal. There is no evidence of inflammation or effusion. The abdominal lymph nodes are normal/not visible.

Other

The caudal vena cava is subjectively dilated. B-lines are observed within the thorax.

ULTRASONOGRAPHIC FINDINGS

Primary Findings

- The dilation of the hepatic vessels and caudal vena cava are more concerning for increased hydrostatic pressure (i.e., secondary to right-sided heart disease). However, other causes (i.e., clot in the cranial aspect of the caudal vena cava) cannot be excluded.
- The gallbladder wall changes may be secondary to increased hydrostatic pressure, low oncotic pressure, cholecystitis, anaphylaxis, immune-mediated disease, other. Increased hydrostatic pressure is favored.
- The hepatic parenchymal changes could be consistent with regenerative nodular hyperplasia, vacuolar hepatopathy, infiltrative neoplasia, inflammatory disease, hepatotoxicosis (i.e., copper), other hepatopathy or some combination thereof. Correlation with the patient's liver values is recommended.
- The B-lines in the thorax are consistent with pulmonary parenchymal disease.

Secondary Findings

- Bilateral chronic renal changes with dystrophic mineralization
- The prostate changes are most consistent with benign prostatic hyperplasia with a lower possibility of neoplasia or other prostatic pathology.

INTERPRETATION OF THE FINDINGS & FURTHER RECOMMENDATIONS

- Further recommendations should be based on the echocardiogram report.



PATIENT

Edgrr Britts

SPECIES

Canine

BREED

Yorkshire Terrier

SEX

Neutered Male

AGE

6.7.2009

WEIGHT

2.48 kg

INTERPRETED BY

Andrea Nicastro, DVM,
Diplomate ACVIM (*Small Animal Internal Medicine*)

IMAGING PERFORMED BY

Andrea Nicastro, DVM,
Diplomate ACVIM (*Small Animal Internal Medicine*)

HOSPITAL NAME

Blue Pearl MP ER

REFERRING VET

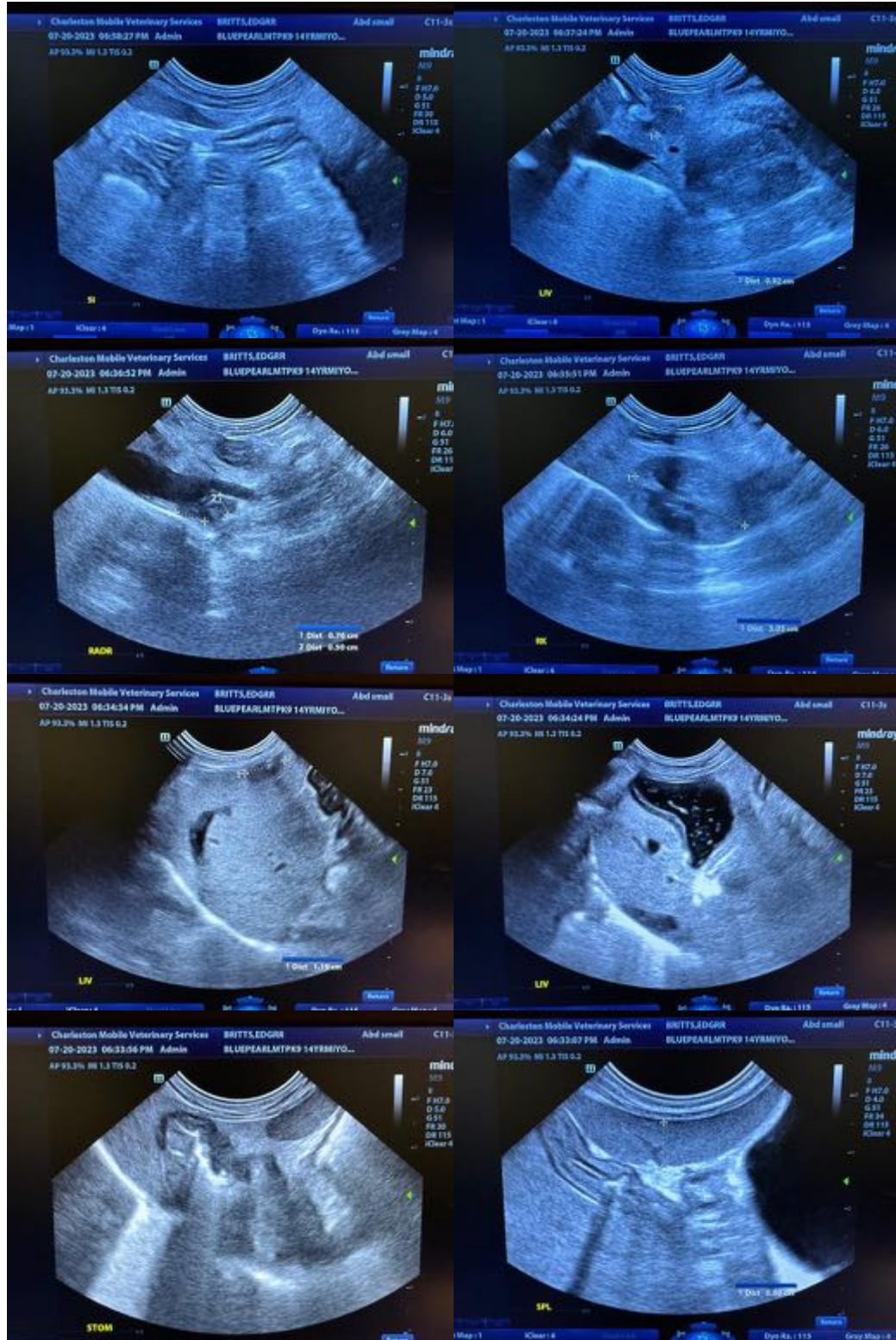
Dr. Shannon Graham

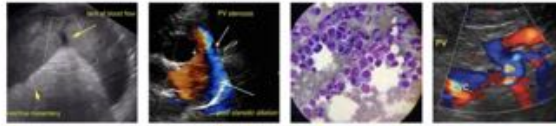
INVOICE

13759

DATE

7.20.23





PATIENT

Edgrr Britts

SPECIES

Canine

BREED

Yorkshire Terrier

SEX

Neutered Male

AGE

6.7.2009

WEIGHT

2.48 kg

INTERPRETED BY

Andrea Nicastro, DVM,
Diplomate ACVIM (*Small Animal Internal Medicine*)

IMAGING PERFORMED BY

Andrea Nicastro, DVM,
Diplomate ACVIM (*Small Animal Internal Medicine*)

HOSPITAL NAME

Blue Pearl MP ER

REFERRING VET

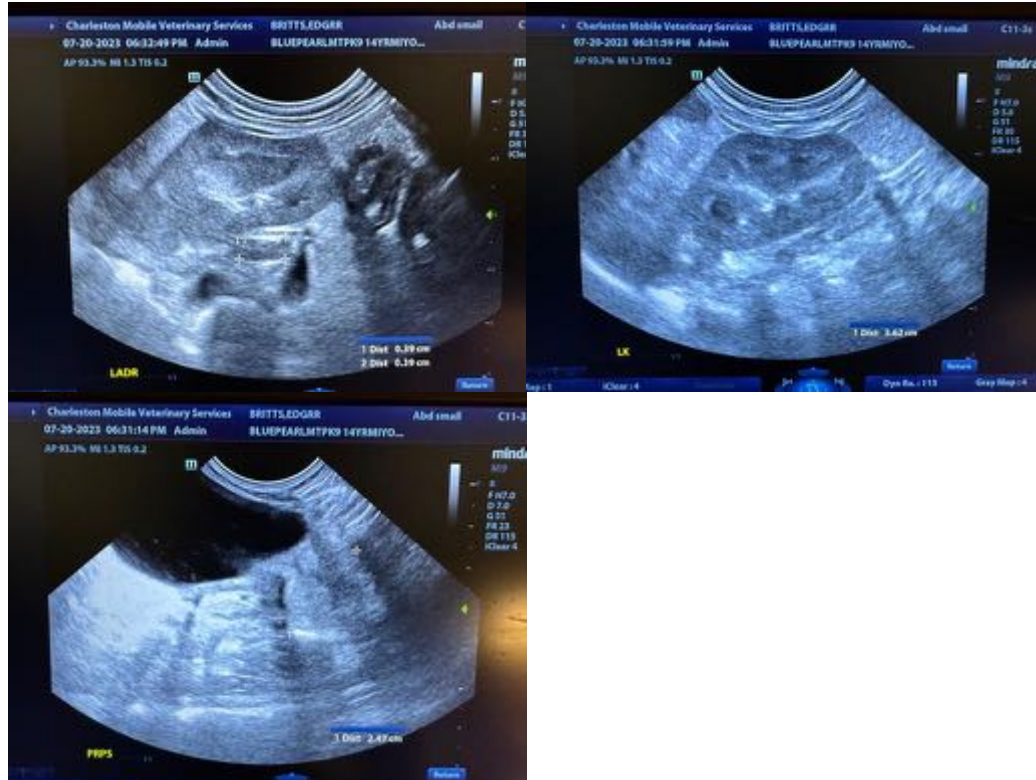
Dr. Shannon Graham

INVOICE

13759

DATE

7.20.23



The information and recommendations provided are based on the images presented by the referring veterinarian/sonographer. No evaluation can be communicated regarding pathology that was not visible in the image/video clips provided.

Thank you for this referral. If the clinical or image interpretation does not parallel your findings or if I can be of any further assistance, please contact me.

Andrea Nicastro, MPH, DVM, Diplomate DACVIM (Small Animal Internal Medicine)
info@SonoPath.com