

PATIENT PRESENTING CLINICAL SIGNS

Cole Blackburn

History: Patient presented for a wellness exam. Has a history of increase in appetite and gaining weight. Patient has arthritis but no other significant PE abnormalities. Wellness BW showed a very elevated ALP (125) and mild GGT (17) elevations. Anaplasma +.

SPECIES

Canine

ULTRASONOGRAPHIC EXAMINATION OF THE ABDOMEN

BREED

Bearded Collie

Urinary System

The urinary bladder wall is normal in thickness and the mucosal surface is smooth. The bladder is moderately distended. A scant amount of echogenic debris is observed within the lumen. No cystic calculi are observed. The region of the trigone and the proximal urethra, visible to a depth of 2 cm, are normal.

SEX

Neutered Male

The prostate is normal in size (1.10 cm in width) and shape. Parenchyma is homogenous. The prostatic urethra appears normal without evidence of dilation or obstruction.

AGE

12 years, 4 mos

The left kidney is normal in size (6.26 cm in length) with a normal shape, architecture and smooth peripheral margins. The cortex is isoechoic relative to the spleen. There is a normal 1:3 cortex to medulla ratio with moderate loss of corticomedullary distinction. There is no evidence of pyelectasia, nephroliths, infarcts or hydroureter.

WEIGHT

64.4 lbs

The right kidney is normal in size (7.86 cm in length) with a slightly irregular shape. A 3.93 x 2.89 cm irregular, septated cystic structure, containing suspended echogenic debris is observed at the craniomedial aspect. The lesion causes some distortion of the renal architecture as well as capsular expansion. In the remainder of the kidney, the cortex is isoechoic relative to the spleen. There is a normal 1:3 cortex to medulla ratio with moderate loss of corticomedullary distinction. Hyperechoic shadowing diverticular foci are visualized. There is no evidence of pyelectasia, infarcts or hydroureter.

INTERPRETED BY

Andrea Nicastro, DVM,
Diplomate ACVIM (Small
Animal Internal Medicine)

Adrenal Glands

The left adrenal gland is prominent at the cranial pole (1.02 cm) and normal in size at the caudal pole (0.69 cm) with smooth curvilinear peripheral contours. Glandular echogenicity and detail are normal. The phrenicoabdominal vein and surrounding vasculature are normal.

IMAGING PERFORMED BY

Pamela Harrigan, RDMS

HOSPITAL NAME

Anchor AH

The right adrenal gland is in normal size (0.82 cm at cranial pole) (0.69 cm at caudal pole) with a normal shape and homogenous parenchyma. The glandular echogenicity and detail are unremarkable. Capsule, cortex, and medullary definition are normal. The phrenicoabdominal vein and surrounding vasculature are normal.

REFERRING VET

Katherine Pietsch,
DVM

Spleen

The spleen is normal in size (2.12 cm in width at the level of the hilus) with a normal capsular contour. The parenchyma is subtly mottled in appearance. One-to-two small, ill-defined myelolipomas are visualized. Splenic vasculature is normal.

INVOICE

13758

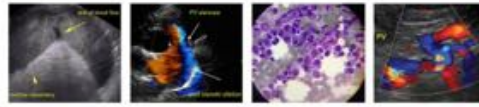
Liver

The liver is subjectively prominent in size with swollen curvilinear peripheral contours. The parenchyma is isoechoic relative to the spleen and exhibits mild heterogeneity. No distinct focal lesions are observed. Hepatic vasculature and biliary tracts are of normal volume with no evidence of congestion.

DATE

7.20.23

The gall bladder lumen is moderately distended. The wall is thin and smooth. A moderate-to-large amount of aggregated, echogenic, partially dependent sludge is observed within the lumen. The cystic and common bile ducts are normal/not seen.



PATIENT

Cole Blackburn

SPECIES

Canine

BREED

Bearded Collie

SEX

Neutered Male

AGE

12 years, 4 mos

WEIGHT

64.4 lbs

INTERPRETED BY

Andrea Nicastro, DVM,
 Diplomate ACVIM (Small
 Animal Internal Medicine)

IMAGING PERFORMED BY

Pamela Harrigan, RDMS

HOSPITAL NAME

Anchor AH

REFERRING VET

Katherine Pietsch,
 DVM

INVOICE

13758

DATE

7.20.23

Gastrointestinal

The lumen is not distended. The gastric wall is normal in thickness with a normal layering pattern. The small intestinal lumen is not dilated. The small intestinal wall thickness is normal with a normal layering pattern and appropriate mural detail. Discreet masses are not identified. The colonic wall is normal. There is no evidence of an obstructive pattern.

Pancreas

The region of the pancreas is isoechoic relative to surrounding omental fat. No obvious parenchymal abnormalities are observed. There is no evidence of regional inflammation or effusion.

Free Abdomen

The peritoneal cavity is normal. There is no evidence of inflammation or effusion. The abdominal lymph nodes are normal/not visible.

ULTRASONOGRAPHIC FINDINGS

Primary Findings

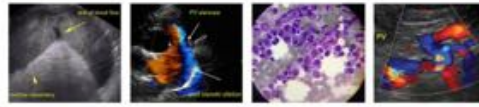
- The diffuse hepatic changes are non-specific and could be consistent with vacuolar hepatopathy, regenerative nodular hyperplasia, and/or age-related remodeling. Inflammatory and infiltrative disease are considered less likely, particularly in light of the liver enzyme pattern.
- The gall bladder sludge could be consistent with cholestasis, and emerging mucocele, or less likely, fasting.
- Prominent cranial pole of the left adrenal gland. This may be a normal variant for this patient or may represent early hyperplastic changes.

Secondary Findings

- The splenic parenchymal changes are most consistent with a benign process such as lymphoid hyperplasia, extramedullary hematopoiesis, splenitis or antigenic stimulation with a low possibility of infiltrative neoplasia (i.e., lymphoma, mast cell neoplasia).
- Bilateral chronic renal changes. The cystic lesion in the right kidney may represent a complex cortical cyst, abscess, or less likely, a necrotic tumor.

INTERPRETATION OF THE FINDINGS & FURTHER RECOMMENDATIONS

- Given the patient's clinical history, consider further testing for Cushing's disease (i.e., low-dose dexamethasone suppression test or ACTH stimulation test).
- A T4/free T4 by equilibrium dialysis is also recommended (if not already performed) given the history of weight gain.
- Serial monitoring (i.e., every 3-4 months) of the patient's liver values is recommended. If values continue to increase, a repeat abdomen ultrasound +/- a more advanced hepatic work-up (i.e., tissue sampling) may be warranted.
- Regarding the gallbladder changes, consider a recheck ultrasound (preferably 2 hours post-small meal). If gallbladder changes are similar to the current scan, consider initiation of Ursodiol therapy.
- Regarding the right renal lesion, a recheck ultrasound is recommended in 4-6 weeks to assess for progression.



PATIENT

Cole Blackburn

SPECIES

Canine

BREED

Bearded Collie

SEX

Neutered Male

AGE

12 years, 4 mos

WEIGHT

64.4 lbs

INTERPRETED BY

Andrea Nicastro, DVM,
 Diplomate ACVIM (Small
 Animal Internal Medicine)

IMAGING PERFORMED BY

Pamela Harrigan, RDCS

HOSPITAL NAME

Anchor AH

REFERRING VET

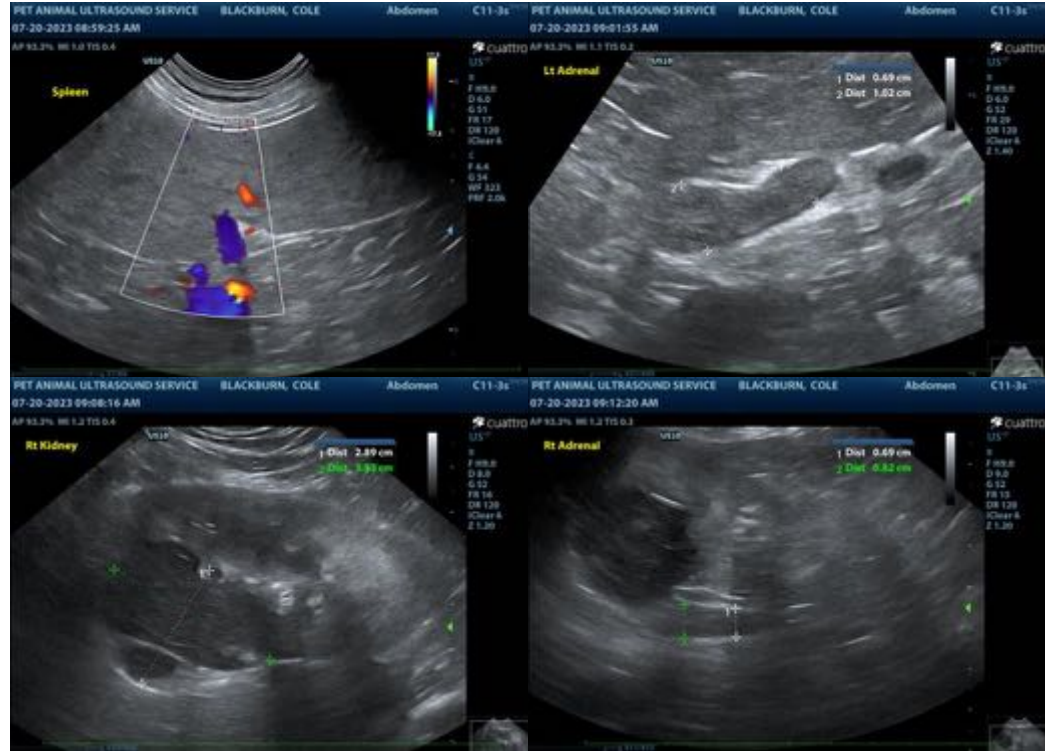
Katherine Pietsch,
 DVM

INVOICE

13758

DATE

7.20.23



The information and recommendations provided are based on the images presented by the referring veterinarian/sonographer. No evaluation can be communicated regarding pathology that was not visible in the image/video clips provided.

Thank you for this referral. If the clinical or image interpretation does not parallel your findings or if I can be of any further assistance, please contact me.

Andrea Nicastro, MPH, DVM, Diplomate DACVIM (Small Animal Internal Medicine)
info@SonoPath.com