

**DATE PRESENTING CLINICAL SIGNS**

7/19/22

Patient presented 7/18 for vomiting, lethargy and excessive panting.

**PATIENT**

Missy Pants Gallbraith

Current Medications: 0.17mL Buprenorphine 0.6mg/mL, 0.7mL Cerenia 10mg/mL, 1mL Ampicillin 100mg/mL IV given in hospital.

Lab Results: Elevated ALT at 346. Snap cPL normal.

Radiographs: Hepatomegaly.

Date of Previous IntraPet Ultrasound: 11/18/21. See attached.

Sedation: Not required to complete full diagnostic ultrasound.

Stat Report: Not requested.

Imaging Performed By: Rachel Brillhart, RDMS.

**SPECIES**

Canine

**BREED**

Yorkshire terrier

**SEX**

Female, spayed

**AGE**

8/1/2009

**WEIGHT**

14.8 lbs.

**INTERPRETED BY**Andrea Nicastro, DVM,  
Diplomate ACVIM  
(Small Animal Internal  
Medicine)**HOSPITAL NAME**

Festival VC

**REFERRING VET**

Dr. Cianelli

**INVOICE**

13751

**ULTRASONOGRAPHIC EXAMINATION OF THE ABDOMEN****Urinary System**

The urinary bladder and visible portion of the pelvic urethra are normal for the degree of luminal distension.

The urine is anechoic with no evidence of debris. Cystic calculi and discrete masses are not observed. The region of the trigone and the visible portion of the proximal urethra are normal.

The left kidney is normal size (5.11 cm in length); normal shape and architecture with smooth peripheral margins. There is a normal 1:3 cortex to medulla ratio with normal corticomedullary distinction. There is no evidence of pyelectasia, nephroliths, infarcts or hydronephrosis. Renal vasculature is normal.

The right kidney is normal size (4.67 cm in length); normal shape and architecture with smooth peripheral margins. There is a normal 1:3 cortex to medulla ratio with mild to moderate loss of corticomedullary distinction. 1-2 small cortical cysts are seen. There is no evidence of pyelectasia, nephroliths, infarcts or hydronephrosis. Renal vasculature is normal.

**Adrenal Glands**

The left adrenal gland is enlarged (0.65 cm at cranial pole) (0.84 cm at caudal pole) (1.86 cm in length) with a slightly irregular shape. The glandular echogenicity and detail are unremarkable. Capsule, cortex, and medullary definition are normal. The phrenicoabdominal vein and surrounding vasculature are normal.

The right adrenal gland is mildly enlarged (0.84 cm at cranial pole) (0.65 cm at caudal pole) (2.23 cm in length); normal shape; homogenous parenchyma. The glandular echogenicity and detail are unremarkable. Capsule, cortex, and medullary definition are normal. The phrenicoabdominal vein and surrounding vasculature are normal.

**Spleen**

The spleen is normal in size (1.24 cm in width at the level of the hilus) with a normal capsular contour. The parenchyma is subtly mottled in appearance. A 0.73 cm ill-defined hypoechoic nodule is observed at the medial aspect. Splenic vasculature is normal.

**Liver**

The liver is enlarged with swollen peripheral contours. The parenchyma is hypoechoic relative to the spleen and diffusely heterogeneous and mottled in appearance with numerous small ill-defined hyperechoic areas throughout the organ. Vascular and biliary tracts are of normal volume with no evidence of congestion. The portal vein: caudal vena cava ratio is approximately 1:1. No pathological hepatic lymphadenopathy observed. The gall bladder lumen is moderately distended. The wall is normal thickness. Several polypoid like lesions are arising from the luminal surface. A small amount of partially dependent echogenic debris/sludge was observed within the lumen. The cystic and common bile ducts are normal/not seen.

**Gastrointestinal**

The gastric lumen is not distended. The gastric wall and pylorus are normal in thickness with a normal layering pattern. The pyloric outflow tract is patent. The small intestinal lumen is not dilated. The small intestinal wall is diffusely thickened up to 0.47 cm with retention of the normal layering pattern. There is evidence of mucosal striations and speckling in several segments. In addition, there is thickening of the submucosal layer in some regions. Discreet masses are not identified. The colonic wall is normal. No obstructive disease is noted.

### ***Pancreas***

The right limb of the pancreas is visible with normal curvilinear peripheral contours. The parenchyma is largely isoechoic relative to surrounding omental fat and slightly mottled in appearance. The pancreatic duct is visible but not overtly dilated. There is no evidence of peripancreatic inflammation or effusion.

### ***Free Abdomen***

The mesentery throughout the mid-abdominal region is hyperechoic. Trace free fluid is observed. The abdominal lymph nodes are normal/not visible.

## **ULTRASONOGRAPHIC FINDINGS**

### **Primary Findings:**

- The small intestinal wall changes could be consistent with inflammatory bowel disease, lymphangiectasia, infectious/parasitic disease or less likely, infiltrative neoplasia (i.e., lymphoma).
- The diffuse peritonitis is likely secondary to bowel pathology.
- Non-specific diffuse hepatopathy. Differentials include inflammatory disease (i.e., chronic active hepatitis, bacterial cholangiohepatitis), reactive hepatopathy, hepatotoxicosis (i.e., copper), Leptospirosis or other hepatopathy +/- concurrent benign age-related change (i.e., regenerative nodular hyperplasia and/or vacuolar hepatopathy).
- Gallbladder debris/sludge, non-mucocele.

### **Secondary Findings:**

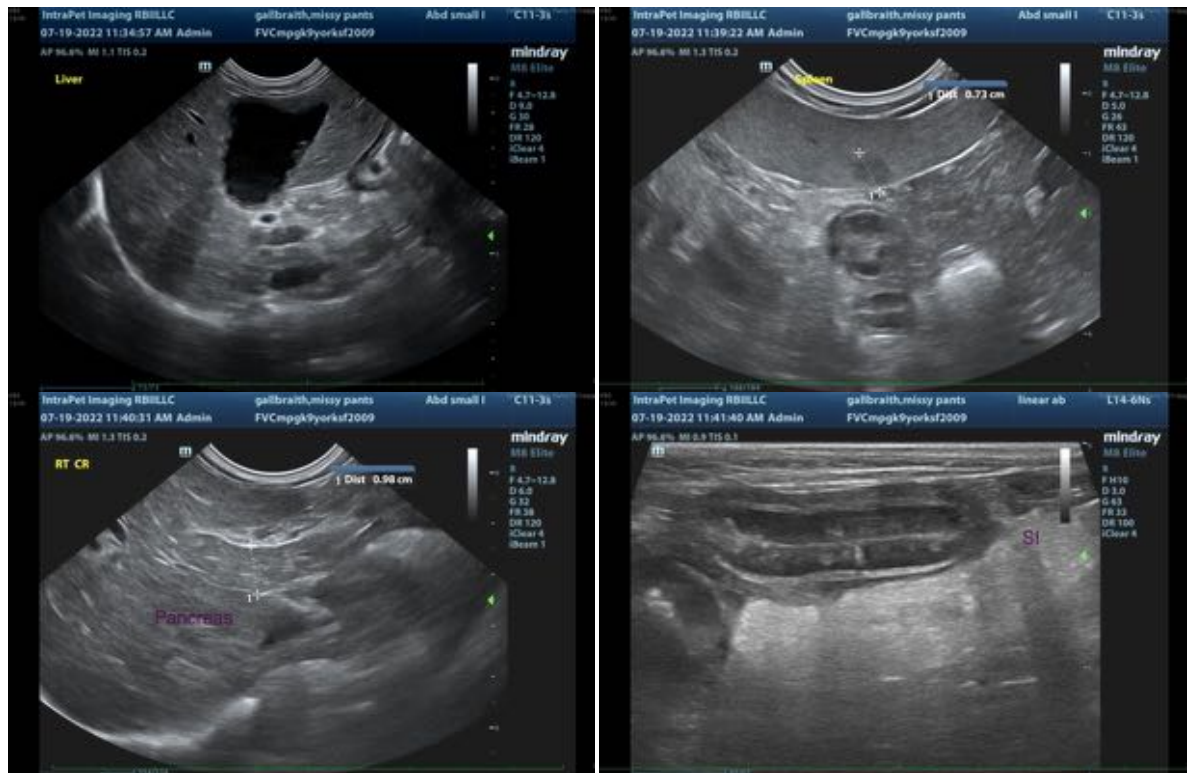
- The pancreatic changes are most consistent with age-related remodeling. Mild chronic pancreatitis may also be present, particularly if the patient exhibits cranial abdominal pain on palpation.
- The splenic parenchyma changes are most consistent with a benign process such as lymphoid hyperplasia, extramedullary hematopoiesis or splenitis with a low possibility of infiltrative neoplasia (i.e., lymphoma, mast cell neoplasia).
- Mild bilateral adrenomegaly (previously observed).
- Bilateral chronic, age-related renal changes (previously observed).

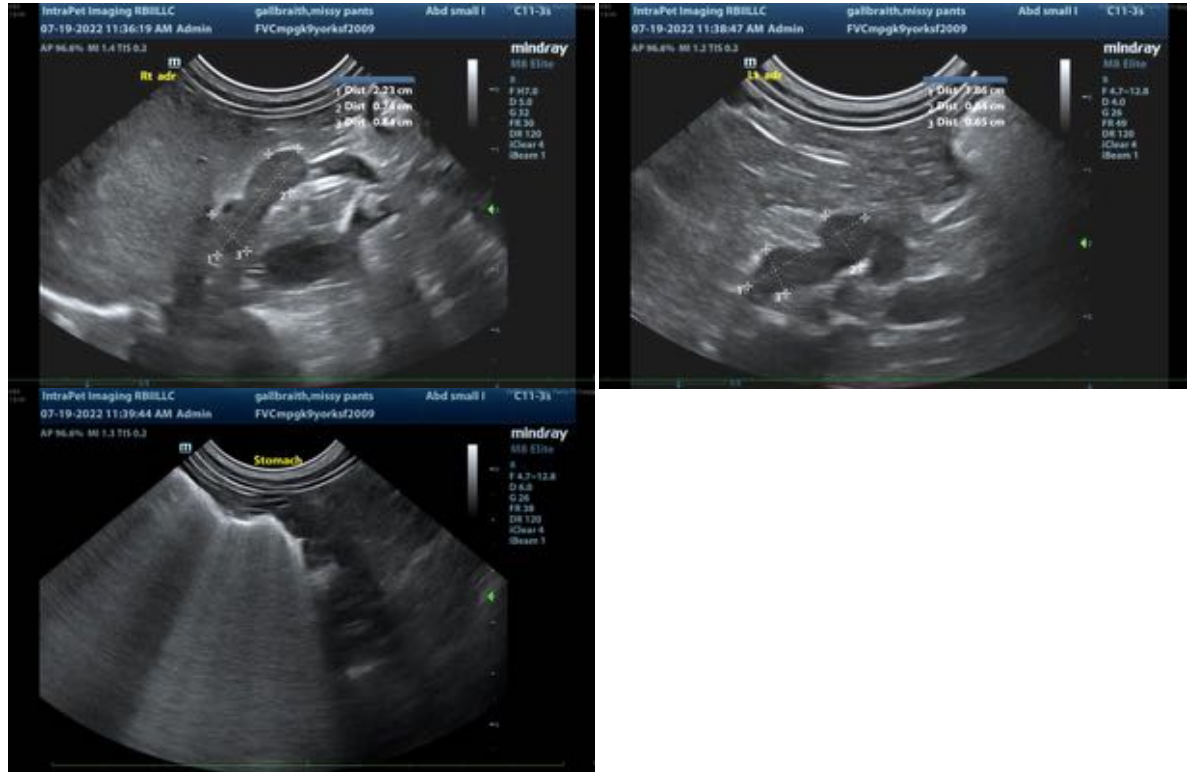
## **INTERPRETATION OF THE FINDINGS & FURTHER RECOMMENDATIONS**

- To further investigate the elevated ALT, consider pre- and post-prandial serum bile acids, Leptospirosis testing (i.e., blood and urine PCR, serology) +/- hepatic tissue sampling (i.e., fine needle aspirate or surgical biopsy). Surgical biopsies are more likely to yield a definitive diagnosis. If pursued, aerobic and anaerobic bile cultures as well as acquisition of additional hepatic tissue samples for potential copper quantitation are recommended. If hepatic tissue sampling is not

pursued, consider empirical treatment for bacterial cholangiohepatitis (i.e., Amoxicillin clavulanic acid +/- Metronidazole, Denamarin) with serial monitoring of the patient's liver values. If the patient responds to therapy, she should be treated for at least 4-6 weeks and 1 week beyond normalization of the ALT.

- Regarding the bowel changes, consider the following:
  1. Malabsorption panel including serum cobalamin, folate, TLI and PLI.
  2. A fecal evaluation for ova/Giardia.
  3. Consider a low-fat, hypoallergenic diet trial. A nutritional consultation (i.e., University of Tennessee) may be warranted.
  4. Ultimately, endoscopic or surgical gastrointestinal biopsies may be necessary to get a definitive diagnosis.





The information and recommendations provided are based on the images presented by the referring veterinarian. No evaluation can be communicated regarding pathology that was not visible in the image/video clips provided.

Thank you for this referral. If the clinical or image interpretation does not parallel your findings or if I can be of any further assistance please contact me.

Andrea Nicastro, DVM, Diplomate ACVIM (*Small Animal Internal Medicine*)  
Andrea.nicastro@sonopath.com