



PATIENT

Zappa Edmunds

SPECIES

Canine

BREED

Terrier mix

SEX

Male, neutered

AGE

14 Yrs.

WEIGHT

16.1 lbs.

INTERPRETED BY

Andrea Nicastro, DVM,
Diplomate ACVIM
(*Small Animal Internal
Medicine*)

**IMAGING
PERFORMED BY**

Dr. Saum Hadi

HOSPITAL NAME

Bethany Family Pet
Clinic

REFERRING VET

Dr. Saum Hadi

INVOICE

13730

DATE

7/18/22

PRESENTING CLINICAL SIGNS

History: P has a history of recurring UTI's. Rods were seen on free catch UA on 7/14. Last culture was performed on 3/13/22, which grew E. Coli. At home, P is having accidents and exhibiting stranguria. Abnormal PE/Chem/CBC/UA Results: 7/14/22 UA (free catch): 100+ rods, 1+ occult blood, pH 7.0, 1+ protein, 1.017 USG, >50 WBC. 6/7/22: CBC/Chem 27/UA/T4: ALKP 98 U/L (WNL), Mild hyperkalemia (5.7 mEq/L), similar UA results (100+ rods, 1.015 USG, marked WBC).

ULTRASONOGRAPHIC EXAMINATION OF THE ABDOMEN

Urinary System

The urinary bladder is mildly distended. The wall is thickened (up to 0.84 cm), particularly in the region of the apex and irregular. A small amount of suspended echogenic debris is observed within the lumen. No cystic calculi are observed. The region of the trigone appears normal.

The prostate is not definitively visualized due to its pelvic location.

The left kidney is normal size (4.50 cm in length); normal shape and architecture with smooth peripheral margins. There is a normal 1:3 cortex to medulla ratio with mild loss of corticomedullary distinction. A few small cortical cysts are seen. There is no evidence of pyelectasia, nephroliths, infarcts or hydroureter.

The right kidney is normal size (4.63 cm in length); normal shape and architecture with smooth peripheral margins. There is a normal 1:3 cortex to medulla ratio with normal corticomedullary distinction. There is no evidence of pyelectasia, nephroliths, infarcts or hydroureter. Renal vasculature is normal.

Adrenal Glands

The left adrenal gland is normal size (0.48 cm at cranial pole) (0.52 cm at caudal pole); normal shape; homogenous parenchyma. The glandular echogenicity and detail are unremarkable. Capsule, cortex, and medullary definition are normal. The phrenicoabdominal vein and surrounding vasculature are normal.

The right adrenal gland is not definitively visualized in the available images.

Spleen

The spleen is not visualized in its entirety. In the visualized portions, the spleen is subjectively normal in size with normal curvilinear peripheral contours. The parenchyma appears homogenous. No distinct focal lesions are observed.

Liver

The liver is subjectively prominent in size with slightly irregular peripheral contours. The parenchyma is hypoechoic relative to the spleen and diffusely mottled in appearance. A 4.27 x 2.69 cm irregular heterogeneous cavitated lesion/mass is observed on the right side. In addition, a few small hypoechoic nodules are seen, at least one of which causes mild capsular expansion. Vascular and biliary tracts are of normal volume with no evidence of congestion. The gall bladder lumen is moderately distended. The wall is thin and smooth. A moderate amount of aggregated echogenic to mineralized debris/sludge is observed within the lumen, most of which is gravity-dependent and some of which is adhered to the luminal surface. The cystic and common bile ducts are normal/not seen.



PATIENT

Zappa Edmunds

SPECIES

Canine

BREED

Terrier mix

SEX

Male, neutered

AGE

14 Yrs.

WEIGHT

16.1 lbs.

INTERPRETED BY

Andrea Nicastro, DVM,
Diplomate ACVIM
(*Small Animal Internal
Medicine*)

IMAGING PERFORMED BY

Dr. Saum Hadi

HOSPITAL NAME

Bethany Family Pet
Clinic

REFERRING VET

Dr. Saum Hadi

INVOICE

13730

DATE

7/18/22

Gastrointestinal

The stomach and intestine are free of stasis and exhibit normal peristaltic activity. The gastric lumen is not distended. The gastric wall and pylorus are normal in thickness with a normal layering pattern. The pyloric outflow tract is patent. The small intestinal lumen is not dilated. The small intestinal wall thickness is normal with a normal layering pattern and appropriate mural detail. Discreet masses are not identified. The colonic wall is normal. No obstructive disease is noted.

Pancreas

The region of the pancreas is isoechoic relative to surrounding omental fat. No obvious parenchymal abnormalities are observed. There is no evidence of regional inflammation or effusion.

Free Abdomen

There is no obvious evidence of free fluid. The abdominal lymph nodes are normal/not visible.

ULTRASONOGRAPHIC FINDINGS

Primary Findings:

- The urinary bladder wall changes are most consistent with cystitis. However, infiltrative neoplasia cannot be completely excluded.
- Right cystic/mass like lesion. Differentials include necrotic tumor, abscess, granuloma with necrotic areas, complex cyst, other. The diffuse hepatic parenchymal changes are non-specific and could be associated with a benign process (i.e., regenerative nodular hyperplasia, vacuolar hepatopathy, age-related remodeling). However, infiltrative neoplasia cannot be completely excluded.

Secondary Findings:

- Minor, bilateral, age-related renal changes with left cortical cysts.
- Mineralized gallbladder debris/sludge- incidental.

INTERPRETATION OF THE FINDINGS & FURTHER RECOMMENDATIONS

- Regarding the hepatic lesion, three-view thoracic radiographs are recommended to assess for pulmonary metastases. If there is no evidence of metastases in the lungs, consider an abdominal exploratory with removal of the lesion and submission for histopathology +/- aerobic and anaerobic bile cultures. Biopsies of the other liver lobes should also be obtained.
- Regarding the recurring urinary tract infections, a urine culture and sensitivity is recommended, preferably on a pre-antibiotic sample. A prolonged antibiotic course (i.e., 3 weeks) may be warranted given the recurring nature of the infections. Ideally, a repeat culture would be performed 5-7 days after the last dose of antibiotics. Also consider a urine BRAF test to further evaluate for lower urinary tract neoplasia. It should be noted, however, that a negative BRAF test does not completely exclude the possibility of cancer. Therefore, if clinical suspicion is high, additional diagnostics (i.e., biopsies) may be necessary to get a definitive diagnosis.



PATIENT

Zappa Edmunds

SPECIES

Canine

BREED

Terrier mix

SEX

Male, neutered

AGE

14 Yrs.

WEIGHT

16.1 lbs.

INTERPRETED BY

Andrea Nicastro, DVM,
Diplomate ACVIM
(Small Animal Internal
Medicine)

IMAGING PERFORMED BY

Dr. Saum Hadi

HOSPITAL NAME

Bethany Family Pet
Clinic

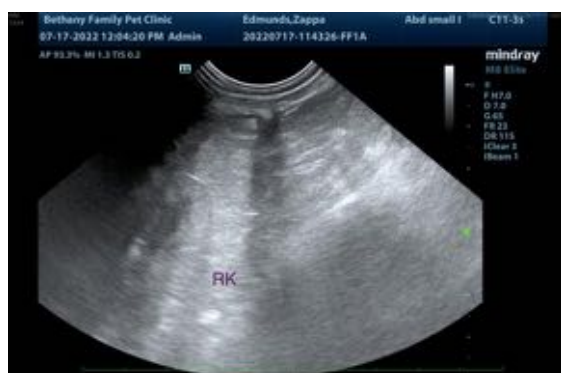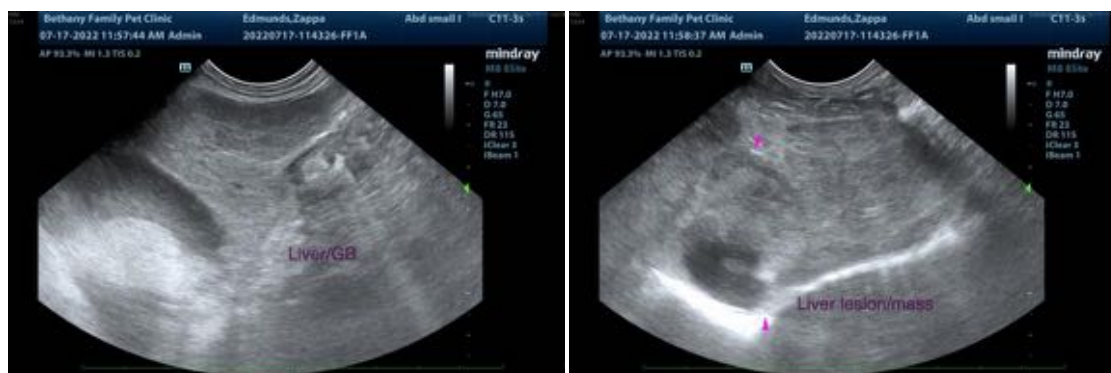
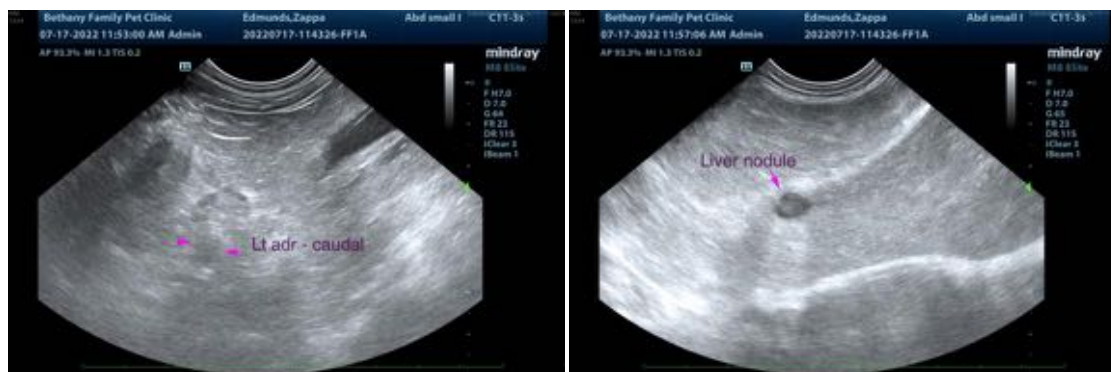
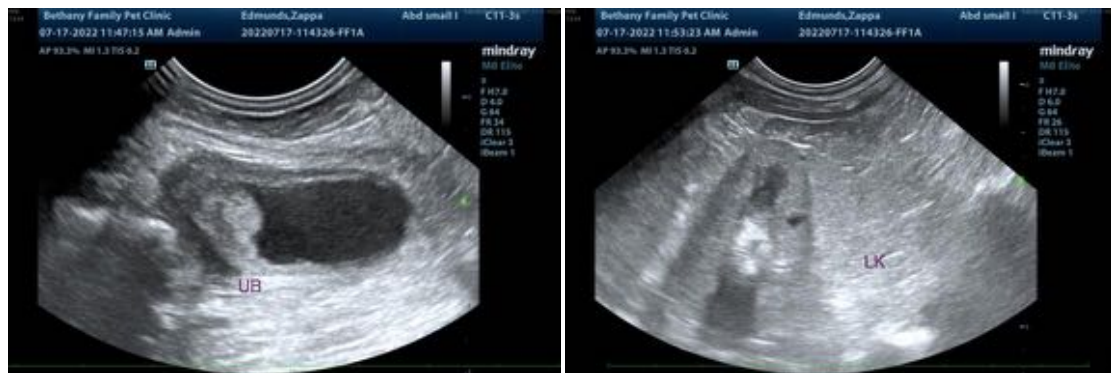
REFERRING VET

Dr. Saum Hadi

INVOICE

13730

DATE
7/18/22



The information and recommendations provided are based on the images presented by the referring veterinarian/sonographer. No evaluation can be communicated regarding pathology that was not visible



PATIENT

Zappa Edmunds

in the image/video clips provided.

Thank you for this referral. If the clinical or image interpretation does not parallel your findings or if I can be of any further assistance please contact me.

SPECIES

Canine

Andrea Nicastro, DVM, Diplomate ACVIM (*Small Animal Internal Medicine*)

Andrea.nicastro@sonopath.com

BREED

Terrier mix

SEX

Male, neutered

AGE

14 Yrs.

WEIGHT

16.1 lbs.

INTERPRETED BY

Andrea Nicastro, DVM,
Diplomate ACVIM
(*Small Animal Internal
Medicine*)

**IMAGING
PERFORMED BY**

Dr. Saum Hadi

HOSPITAL NAME

Bethany Family Pet
Clinic

REFERRING VET

Dr. Saum Hadi

INVOICE

13730

DATE

7/18/22