

PATIENT

Mucca Escobar

SPECIES

Canine

BREED

Golden Retriever

SEX

Female, spayed

AGE

8 Yrs.

WEIGHT

69.6 lbs.

INTERPRETED BY

Andrea Nicastro, DVM,
Diplomate ACVIM (*Small
Animal Internal
Medicine*)

IMAGING PERFORMED

Dr. Ferrer

HOSPITAL NAME

Paseos VC

REFERRING VET

Dr. Garcia

INVOICE

15108

DATE

7/17/23

PRESENTING CLINICAL SIGNS

History: The patient came as a referral for an abdominal ultrasound to evaluate possible mass in the abdomen. Pt has hx of less appetite in the last month and went to rDVM for more evaluation and the radiographs showed changes of suspicious mass on the cranial abdomen.

Abnormal PE/Chem/CBC/UA Results: CBC: WNL CHEM: WNL Radiographs: Showed possible round opacity on the spleen area FNA of the liver was done: Pending

ULTRASONOGRAPHIC EXAMINATION OF THE ABDOMEN

Urinary System

The urinary bladder wall is normal in thickness and the mucosal surface is smooth. The bladder is moderately distended. Luminal contents are anechoic. No cystic calculi are observed. The region of the trigone and the visible portion of the proximal urethra are normal.

The left kidney is normal size (6.32 cm in length); normal shape and architecture with smooth peripheral margins. There is a normal 1:3 cortex to medulla ratio with minima loss of corticomedullary distinction. Trace pyelectasia is present. There is no evidence of nephroliths or hydroureter.

The right kidney is normal size (7.14 cm in length); normal shape and architecture with smooth peripheral margins. There is a normal 1:3 cortex to medulla ratio with minimal loss of corticomedullary distinction. There is no evidence of pyelectasia, nephroliths, infarcts or hydroureter.

Adrenal Glands

The left adrenal gland is enlarged at the caudal pole and normal in size at the cranial pole (0.46 cm at cranial pole) (0.97 cm at caudal pole) (3.18 cm in length). A 1.09 x 0.95 cm hyperechoic heterogeneous nodule is observed at the caudal aspect. The lesion causes capsular expansion. The glandular echogenicity and detail at the cranial aspect are normal. The phrenicoabdominal vein and surrounding vasculature are normal.

The right adrenal gland is normal size (0.46 cm at cranial pole) (0.60 cm at caudal pole) (2.55 cm in length); normal shape; homogenous parenchyma. The glandular echogenicity and detail are unremarkable. Capsule, cortex, and medullary definition are normal. The phrenicoabdominal vein and surrounding vasculature are normal.

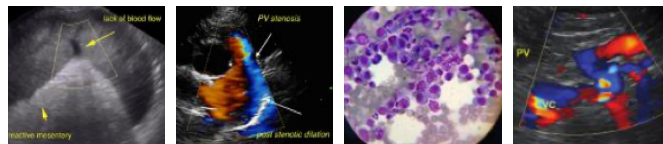
Spleen

The spleen is normal to mildly enlarged in size (1.75 cm in width at the level of the hilus) with irregular peripheral contours. A >3 cm heterogeneous mass is arising from the parenchyma. The mass causes capsular expansion. In the remainder of the spleen, ill-defined hypoechoic areas are observed throughout the organ. Splenic vasculature is normal with no evidence of thrombosis.

Liver

The liver is subjectively enlarged with irregular peripheral contours. Several large isoechoic to slightly heterogeneous masses are observed throughout the organ, the largest measuring >9 cm. Some normal appearing liver is visualized. Vascular is of normal volume with no evidence of congestion. The gall bladder lumen is moderately distended. The wall is thin and smooth. A small amount of mostly gravity-dependent echogenic debris is observed within the lumen. The cystic and common bile ducts are normal/not seen.

Gastrointestinal



PATIENT

Mucca Escobar

SPECIES

Canine

BREED

Golden Retriever

SEX

Female, spayed

AGE

8 Yrs.

WEIGHT

69.6 lbs.

INTERPRETED BY

Andrea Nicastro, DVM,
Diplomate ACVIM (*Small
Animal Internal
Medicine*)

IMAGING PERFORMED

Dr. Ferrer

HOSPITAL NAME

Paseos VC

REFERRING VET

Dr. Garcia

INVOICE

15108

DATE

7/17/23

The stomach and intestine are free of stasis and exhibit normal peristaltic activity. The gastric lumen is not distended. The gastric wall and pylorus are normal in thickness with a normal layering pattern. The pyloric outflow tract is patent. The small intestinal lumen is not dilated. The small intestinal wall thickness is normal with a normal layering pattern and appropriate mural detail. Discreet masses are not identified. The ileocecolic junction and colonic wall are normal. No obstructive disease is noted.

Pancreas

The region of the pancreas is isoechoic relative to surrounding omental fat. No obvious parenchymal abnormalities are observed. There is no evidence of regional inflammation or effusion.

Free Abdomen

A small amount of free fluid is visualized. 1-2 prominent mesenteric lymph nodes are seen, the largest measuring 1.73 x 0.68 cm.

ULTRASONOGRAPHIC FINDINGS

Primary Findings:

- Multiple hepatic masses. Neoplasia (i.e., carcinoma, round cell tumor, sarcoma) is suspected with a low possibility of a multifocal inflammatory process or other hepatopathy.
- Splenic mass. Again, neoplasia (i.e., primary tumor vs metastatic disease) is suspected with a lower possibility of a benign process. The diffuse splenic parenchymal changes are also concerning for infiltrative disease. However, a non-neoplastic process (i.e., lymphoid hyperplasia, extramedullary hematopoiesis or similar) cannot be excluded.
- The left adrenal nodule could be consistent with macronodular hyperplasia, adenoma, adenocarcinoma, pheochromocytoma, metastatic lesion, inflammatory focus, other.

Secondary Findings:

- The prominent mesenteric lymph nodes could be consistent with reactive change or infiltrative change. A reactive process is favored based on the appearance of the nodes.

INTERPRETATION OF THE FINDINGS & FURTHER RECOMMENDATIONS

- Three-view thoracic radiographs are recommended to assess for pulmonary metastases.
- If cytology results from the hepatic mass are inconclusive, surgical biopsies of the hepatic and splenic masses may be necessary to get a definitive diagnosis.
- Regarding the left adrenal, the following diagnostics can be considered:
 1. Baseline blood pressure measurement to evaluate for systemic hypertension.
 2. Further testing for a functional tumor (i.e., low-dose dexamethasone suppression test), urine/blood catecholamine levels.



PATIENT

Mucca Escobar

SPECIES

Canine

BREED

Golden Retriever

SEX

Female, spayed

AGE

8 Yrs.

WEIGHT

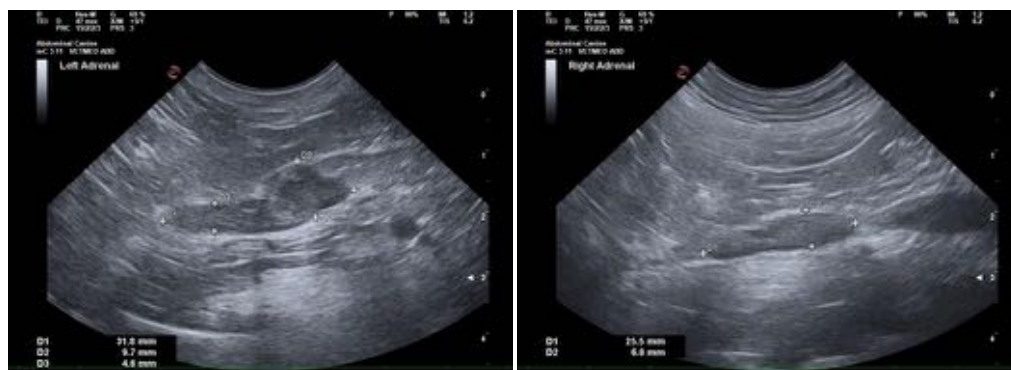
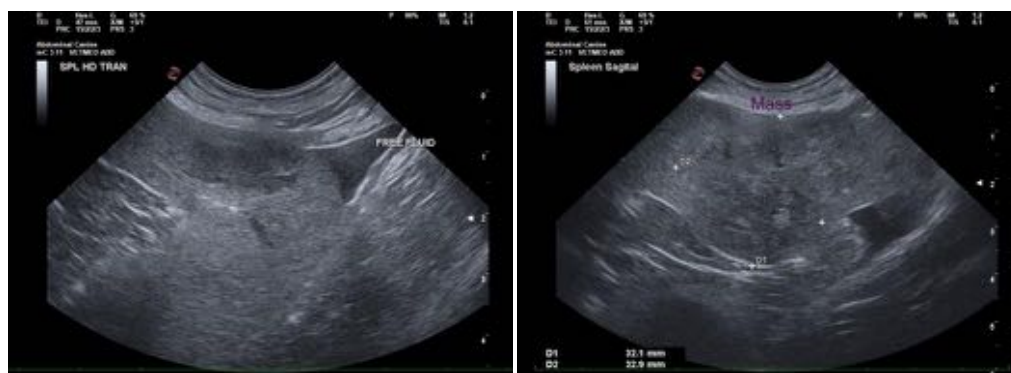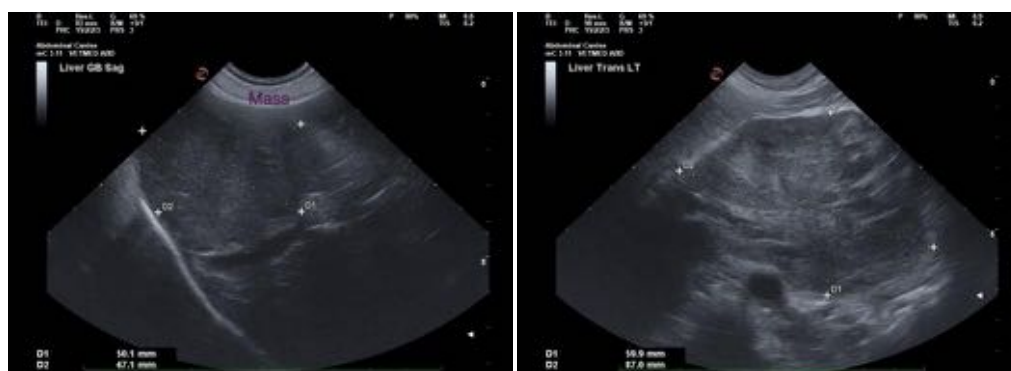
69.6 lbs.

INTERPRETED BY

Andrea Nicastro, DVM,
Diplomate ACVIM (*Small
Animal Internal
Medicine*)

IMAGING PERFORMED

Dr. Ferrer



HOSPITAL NAME

Paseos VC

The information and recommendations provided are based on the images presented by the referring veterinarian/sonographer. No evaluation can be communicated regarding pathology that was not visible in the image/video clips provided.

REFERRING VET

Dr. Garcia

Thank you for this referral. If the clinical or image interpretation does not parallel your findings or if I can be of any further assistance please contact me.

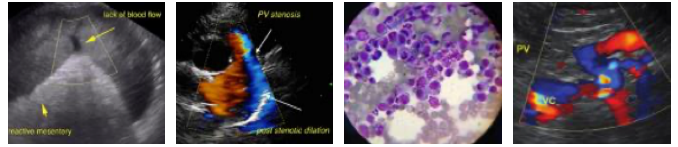
INVOICE

15108

Andrea Nicastro, MPH, DVM, Diplomate DACVIM (Small Animal Internal Medicine)
info@SonoPath.com

DATE

7/17/23



PATIENT

Mucca Escobar

SPECIES

Canine

BREED

Golden Retriever

SEX

Female, spayed

AGE

8 Yrs.

WEIGHT

69.6 lbs.

INTERPRETED BY

Andrea Nicastro, DVM,
Diplomate ACVIM (*Small
Animal Internal
Medicine*)

IMAGING PERFORMED

Dr. Ferrer

HOSPITAL NAME

Paseos VC

REFERRING VET

Dr. Garcia

INVOICE

15108

DATE

7/17/23