



PATIENT

Rosie Iannaccona

SPECIES

Canine

BREED

Greater Swiss Mt Dog

SEX

Spayed Female

AGE

11 years, 2 mos

WEIGHT

93.6 lbs

INTERPRETED BY

Andrea Nicastro,
DVM, Diplomate
ACVIM (*Small Animal
Internal Medicine*)

IMAGING PERFORMED BY

Kelly Vazquez

HOSPITAL NAME

Westwood Reg. VH

REFERRING VET

Dr. Hartwick

INVOICE

11228

DATE

7.15.22

PRESENTING CLINICAL SIGNS

History: Previous history of gastric dilation without torsion on Feb. 2022, reactive, nodular spleen was seen on AUS at that time (at emergency hospital). History of mast cell - dermal, history of nonspecific hepatopathy; improved since Jan. 2022 on Denamarin. History of mild creat. elevation 8/2019, history of hypertension - controlled. Current meds: "pain away" supplement, Probiocin, Prilosec, Denamarin, Gas X prn, metoclopramide p.m., Proin & DES, Benazapril for hypertension.

Abnormal PE/Chem/CBC/UA Results: 1/27/22: AST 127, ALT 250, BUN 30, creat. 1.3. 2/28/22: ALT: 140, BUN 28, creat. 1.4. USG: 1.014.

ULTRASONOGRAPHIC EXAMINATION OF THE ABDOMEN

Urinary System

The **urinary bladder** wall is normal in thickness and the mucosal surface is smooth. The bladder lumen is moderately distended with anechoic urine. No masses, inflammatory changes or calculi are observed. The region of the trigone and the visible portion of the proximal urethra are normal.

The **left kidney** is normal size (5.79 cm in length); normal shape and architecture with smooth peripheral margins. There is a normal 1:3 cortex to medulla ratio with minimal to mild loss of corticomedullary distinction. There is no evidence of pyelectasia, nephroliths, infarcts or hydroureter.

The **right kidney** is normal size (5.36 cm in length); normal shape and architecture with smooth peripheral margins. There is a normal 1:3 cortex to medulla ratio with minimal to mild loss of corticomedullary distinction. There is no evidence of pyelectasia, nephroliths, infarcts or hydroureter.

Adrenal Glands

The **left adrenal gland** is normal size (0.76 cm at cranial pole) (0.71 cm at caudal pole) (1.87 cm in length); normal shape; homogenous parenchyma. The glandular echogenicity and detail are unremarkable. Capsule, cortex, and medullary definition are normal. The phrenicoabdominal vein and surrounding vasculature are normal.

The **right adrenal gland** is normal size (0.80 cm at cranial pole) (0.70 cm at caudal pole) (2.26 cm in length); normal shape; homogenous parenchyma. The glandular echogenicity and detail are unremarkable. Capsule, cortex, and medullary definition are normal. The phrenicoabdominal vein and surrounding vasculature are normal.

Spleen

The **spleen** is subjectively normal in size (1.94 cm in width at the level of the hilus) with normal curvilinear peripheral contours. The parenchyma is diffusely mottled in appearance with a few ill-defined, hyperechoic nodules, the largest measuring 0.53 cm in diameter. Splenic vasculature appears normal with no evidence of thrombosis.

Liver

The **liver** is subjectively normal in size with normal contours and structure. There is appropriate echogenicity and echotexture. No overt structural evidence of inflammatory, infiltrative, or regenerative pathology is evident. Vascular and biliary tracts are of normal volume with no evidence of congestion. No pathological hepatic lymphadenopathy observed.

The **gall bladder** lumen is moderately distended. The wall is thin and smooth. Luminal contents are anechoic. The cystic and common bile ducts are normal/not seen.

Gastrointestinal

The **gastric lumen** is mildly to moderate fluid-distended and appears hypomotile. The gastric wall and pylorus are normal in thickness with a normal layering pattern. The pyloric outflow tract is patent. The small intestinal lumen is not dilated. The small intestinal wall thickness is normal with a normal layering pattern and appropriate mural detail. Discreet masses are not identified. The colonic wall is normal. There is no evidence of an obstructive pattern.

Pancreas

The region of the **pancreas** is isoechoic relative to surrounding omental fat. No obvious parenchymal abnormalities are observed. There is no evidence of regional inflammation or effusion.

Free Abdomen

The **peritoneal cavity** is normal. There is no evidence of inflammation or effusion. The abdominal **lymph nodes** are normal/not visible.

ULTRASONOGRAPHIC FINDINGS

Primary Findings

- The fluid within the gastric lumen may be secondary to a primary motility issue or recent water ingestion. Correlation with the patient's clinical history is recommended.
- Bilateral, nonspecific, chronic, age-related renal changes
- An obvious cause for the elevated liver enzymes is not identified in the study. However, a microscopic hepatopathy (i.e., bacterial cholangiohepatitis, Leptospirosis, chronic active hepatitis, copper-associated hepatotoxicity, reactive hepatopathy, infiltrative neoplasia (less likely)) cannot be excluded.

Secondary Findings

- The splenic parenchymal changes are nonspecific and could be secondary to lymphoid hyperplasia, extramedullary hematopoiesis, splenitis, antigenic stimulation, or less likely, infiltrative neoplasia (i.e., round cell tumor). Given the previous history of a reactive spleen, a benign process is favored.

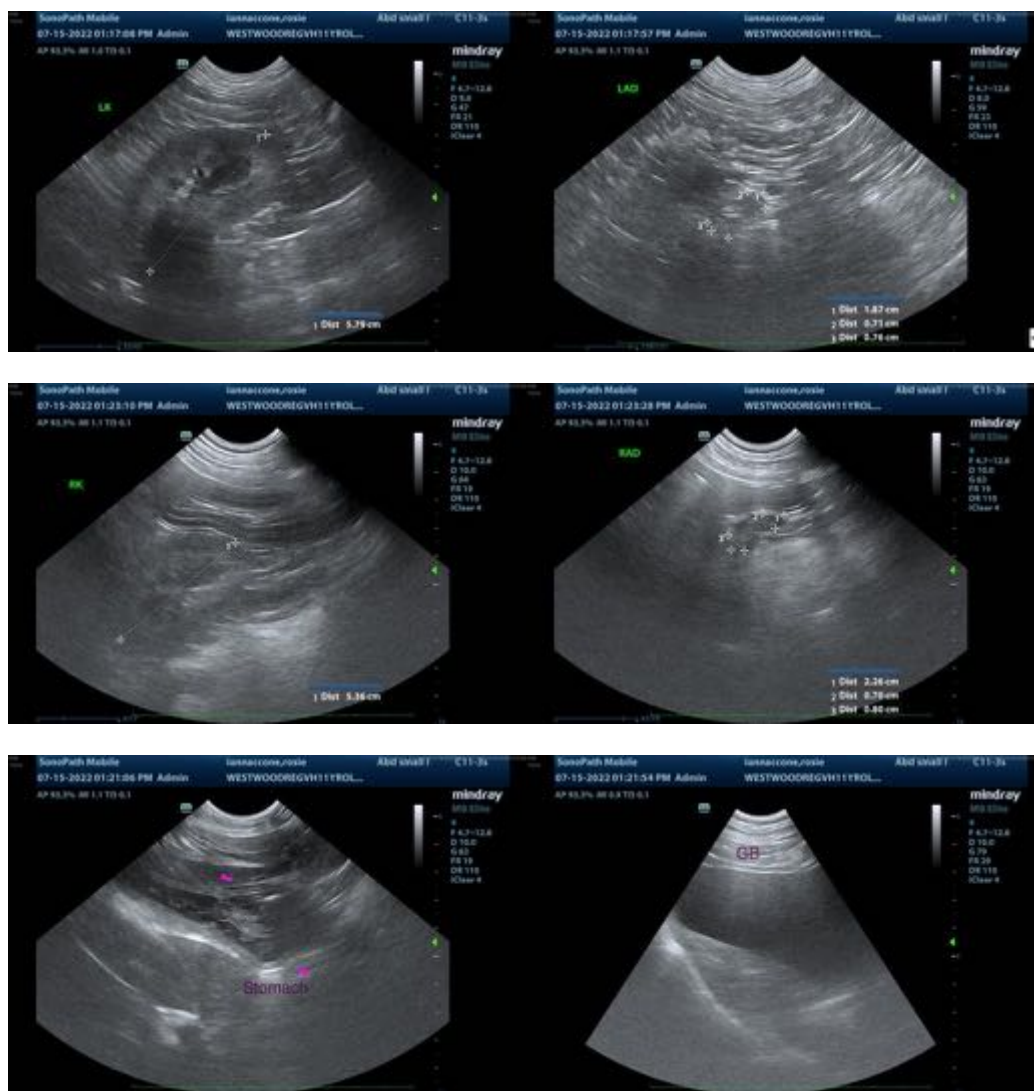
INTERPRETATION OF THE FINDINGS & FURTHER RECOMMENDATIONS

Regarding the azotemia and sonographic renal changes, consider the following:

1. Urine culture and sensitivity
2. UPC (if proteinuria is present)
3. Baseline blood pressure measurement
4. Transition to a prescription renal diet, if tolerated

Regarding the elevated liver enzymes, consider pre-and postprandial serum bile acids, +/- hepatic tissue sampling (i.e., fine-needle aspirate or surgical biopsy). Surgical biopsies are preferred in that they are more likely to be representative of global organ pathology. If pursued, aerobic and anaerobic bile cultures as well as acquisition of additional hepatic tissue samples for potential copper quantitation are recommended. If a conservative approach is desired, consider empirical treatment for bacterial cholangiohepatitis (amoxicillin-clavulanic acid, +/-metronidazole, Denamarin). If no improvement in the liver values is seen within 7-10 days of initiating therapy, antibiotics should be discontinued, and hepatic tissue sampling reconsidered. If liver values improve, continue therapy for at least 4-6 weeks and 1 week beyond normalization of the liver values.

A fine needle aspirate of the spleen can be considered (if clotting status is appropriate), particularly if the parenchymal changes appear more severe that on today's scan compared to the previous sonogram.



The information and recommendations provided are based on the images presented by the referring veterinarian/sonographer. No evaluation can be communicated regarding pathology that was not visible in the image/video clips provided.

Thank you for this referral. If the clinical or image interpretation does not parallel your findings or if I can be of any further assistance, please contact me.

Andrea Nicastro, DVM, Diplomate DACVIM (Small Animal Internal Medicine)
info@SonoPath.com