



PATIENT

Tucker Pardue

SPECIES

Canine

BREED

Pomeranian Mix

SEX

Neutered Male

AGE

8.31.2011

WEIGHT

26.3 lbs

INTERPRETED BY

Andrea Nicastro,
DVM, Diplomate
ACVIM (Small Animal
Internal Medicine)

IMAGING PERFORMED BY

Andrea Nicastro,
DVM, Diplomate
ACVIM (Small Animal
Internal Medicine)

HOSPITAL NAME

Foxbank VH

REFERRING VET

Dr. Ashley Parsons

INVOICE

11221

DATE

7.14.22

PRESENTING CLINICAL SIGNS

Clinical Exam Findings: Patient presented for annual on 7/5/2022.

USG 1.003 on urine on senior bloodwork with inactive sediment. Urine Culture Pending.

Patient is hypothyroid, but owners not managing. ALKP 1573 on senior bloodwork, 421 6/26/2021

Abnormal lab-work values: USG 1.003 on urine on senior bloodwork with inactive sediment. Urine Culture Pending. Patient is hypothyroid, but owners not managing. ALKP 1573 on senior bloodwork, 421 6/26/2021

Current Medications: None

ULTRASONOGRAPHIC EXAMINATION OF THE ABDOMEN

Urinary System

The **urinary bladder** is moderately distended with anechoic urine. The wall is of appropriate thickness for the level of repletion. The mucosal surface is smooth. No cystic calculi are observed. The region of the trigone and the proximal urethra, visible to a depth of 2-3 cm, are normal.

The **prostate** is normal in size (0.73 cm in width) and shape. Parenchyma is homogenous. The prostatic urethra appears normal without evidence of dilation or obstruction.

The **left kidney** is normal size (5.40 cm in length); normal shape and architecture with smooth peripheral margins. There is a normal 1:3 cortex to medulla ratio with mild to moderate loss of corticomedullary distinction. The cortex is hyperechoic. Trace pyelectasia is present. There is no evidence of nephroliths, infarcts or hydronephrosis. Renal vasculature is normal.

The **right kidney** is normal in size (6.46 cm in length) with a normal shape, smooth peripheral margins, and normal internal architecture. There is mild to moderate loss of corticomedullary distinction. The cortex is mildly hyperechoic. Several hyperechoic shadowing diverticular foci are observed. There is no evidence of pyelectasia, infarcts or hydronephrosis. Renal vasculature is normal.

Adrenal Glands

The **left adrenal gland** is mildly enlarged (0.66 cm at cranial pole) (0.84 cm at caudal pole); normal shape; homogenous parenchyma. The glandular echogenicity and detail are unremarkable. Capsule, cortex, and medullary definition are normal. The phrenicoabdominal vein and surrounding vasculature are normal.

The **right adrenal gland** is normal size (1.04 cm at cranial pole) (0.59 cm at caudal pole) (0.95 cm in length); normal shape; homogenous parenchyma. The glandular echogenicity and detail are unremarkable. Capsule, cortex, and medullary definition are normal. The phrenicoabdominal vein and surrounding vasculature are normal.

Spleen

The **spleen** is normal in size (1.18 cm in width at the level of the hilus) with a normal capsular contour. There is appropriate echogenicity and echotexture. No focal lesions are observed. Splenic vasculature is normal.

Liver

The **liver** is subjectively enlarged with normal swollen peripheral contours. The parenchyma is hyperechoic relative to the spleen and diffusely mottled, with numerous, small, hyperechoic nodules throughout the organ. Hepatic vasculature and intrahepatic biliary tracts are of normal volume with no evidence of congestion. The portal vein to caudal vena cava ratio is approximately 1: 1.



PATIENT

Tucker Pardue

The **gall bladder** lumen is moderately distended. The wall is thin and smooth. A small to moderate amount of echogenic to mineralized, mostly gravity dependent debris is observed within the lumen. The cystic and common bile ducts are normal/not seen.

SPECIES

Canine

Gastrointestinal

The **stomach and intestine** are free of stasis and exhibit normal peristaltic activity. The gastric lumen is not distended. The gastric wall and pylorus are normal in thickness with a normal layering pattern. The pyloric outflow tract is patent. The small intestinal lumen is not dilated. The small intestinal wall thickness is normal with a normal layering pattern and appropriate mural detail. Discreet masses are not identified. The colonic wall is normal. There is no evidence of an obstructive pattern.

BREED

Pomeranian Mix

SEX

Neutered Male

Pancreas

The right limb of the pancreas is visible with normal curvilinear peripheral contours. The parenchyma is largely isoechoic relative to surrounding omental fat and slightly mottled in appearance. The pancreatic duct is visible but not overtly dilated. There is no evidence of peripancreatic inflammation or effusion.

AGE

8.31.2011

Free Abdomen

The **peritoneal cavity** is normal. There is no evidence of inflammation or effusion. The abdominal **lymph nodes** are normal/not visible.

WEIGHT

26.3 lbs

Other

A brief echocardiogram reveals no evidence of pericardial effusion or obvious right atrial/auricular mass.

ULTRASONOGRAPHIC FINDINGS

INTERPRETED BY

Andrea Nicastro,
DVM, Diplomate
ACVIM (Small Animal
Internal Medicine)

Primary Findings

- The hepatic parenchyma changes are nonspecific and could be associated with a benign process (i.e., vacuolar hepatopathy, regenerative nodular hyperplasia). Alternatively, infiltrative neoplasia (i.e., lymphoma) cannot be completely excluded.
- Gall bladder debris, non-mucocele
- The mild left adrenomegaly may represent early hyperplastic change, normal variation, or less likely, an emerging tumor.

IMAGING PERFORMED BY

Andrea Nicastro,
DVM, Diplomate
ACVIM (Small Animal
Internal Medicine)

Secondary Findings

- The pancreatic changes are most consistent with age-related parenchymal remodeling, potentially secondary to a prior inflammatory episode, early fibrosis or chronic pancreatitis.

HOSPITAL NAME

Foxbank VH

INTERPRETATION OF THE FINDINGS & FURTHER RECOMMENDATIONS

REFERRING VET

Dr. Ashley Parsons

If an aggressive approach is desired, consider a fine-needle aspirate of the liver (if clotting status is appropriate) to further assess for lymphoma.

INVOICE

11221

If a more conservative approach is desired, consider rechecking liver values in 3-4 weeks. If values are continuing to increase and/or if the patient becomes clinically ill, consider hepatic tissue sampling at that time. Thoracic radiographs are recommended prior to any anesthetic event.

DATE

7.14.22

Consider testing for hyperadrenocorticism with a low-dose dexamethasone suppression test or ACTH stimulation test if clinical signs (i.e., PU/PD) develop.



PATIENT

Tucker Pardue

SPECIES

Canine

BREED

Pomeranian Mix

SEX

Neutered Male

AGE

8.31.2011

WEIGHT

26.3 lbs

INTERPRETED BY

Andrea Nicastro,
DVM, Diplomate
ACVIM (Small Animal
Internal Medicine)

IMAGING PERFORMED BY

Andrea Nicastro,
DVM, Diplomate
ACVIM (Small Animal
Internal Medicine)

HOSPITAL NAME

Foxbank VH

REFERRING VET

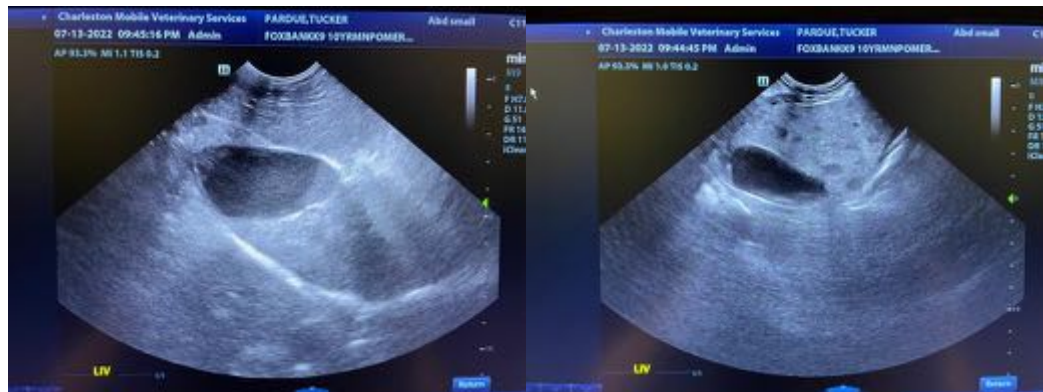
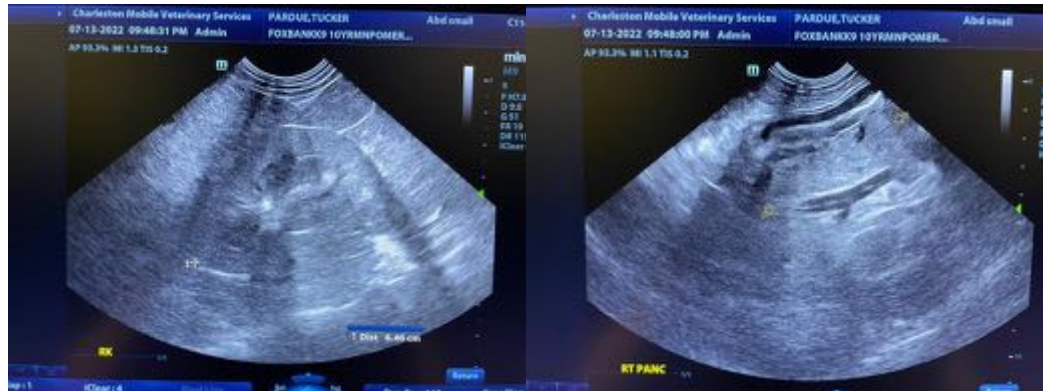
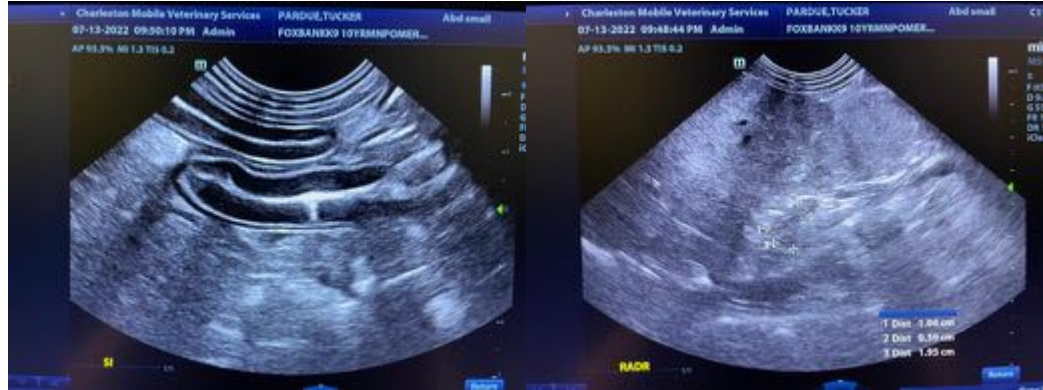
Dr. Ashley Parsons

INVOICE

11221

DATE

7.14.22





PATIENT

Tucker Pardue

SPECIES

Canine

BREED

Pomeranian Mix

SEX

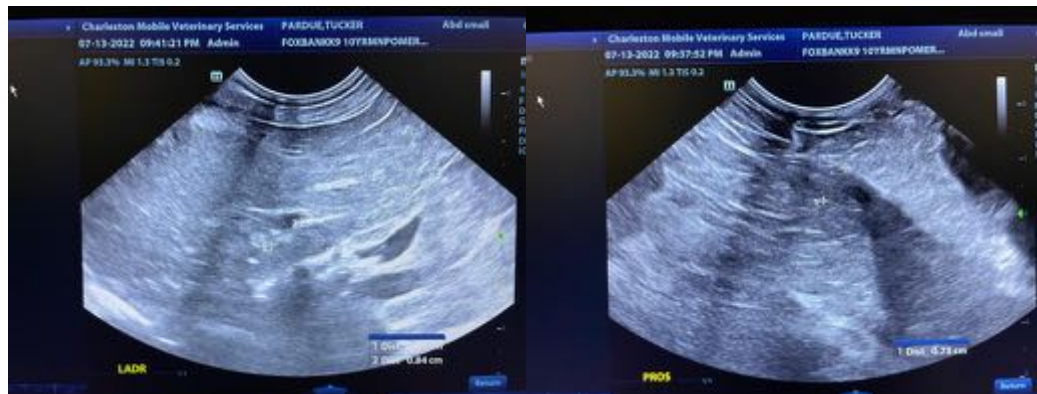
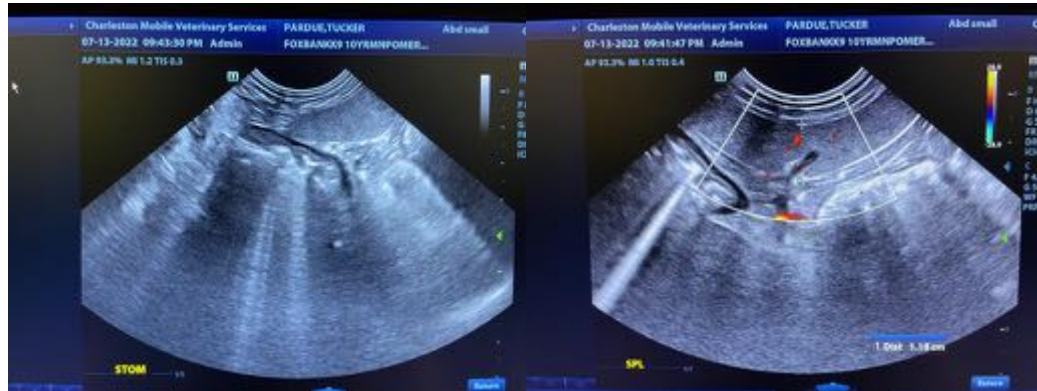
Neutered Male

AGE

8.31.2011

WEIGHT

26.3 lbs



INTERPRETED BY

Andrea Nicastro,
DVM, Diplomate
ACVIM (Small Animal
Internal Medicine)

**IMAGING
PERFORMED BY**

Andrea Nicastro,
DVM, Diplomate
ACVIM (Small Animal
Internal Medicine)

HOSPITAL NAME

Foxbank VH

REFERRING VET

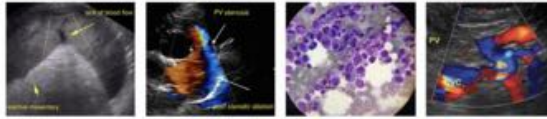
Dr. Ashley Parsons

INVOICE

11221

DATE

7.14.22



PATIENT

Tucker Pardue

SPECIES

Canine

BREED

Pomeranian Mix

SEX

Neutered Male

AGE

8.31.2011

WEIGHT

26.3 lbs

INTERPRETED BY

Andrea Nicastro,
DVM, Diplomate
ACVIM (*Small Animal
Internal Medicine*)

IMAGING PERFORMED BY

Andrea Nicastro,
DVM, Diplomate
ACVIM (*Small Animal
Internal Medicine*)

HOSPITAL NAME

Foxbank VH

REFERRING VET

Dr. Ashley Parsons

INVOICE

11221

DATE

7.14.22

The information and recommendations provided are based on the images presented by the referring veterinarian/sonographer. No evaluation can be communicated regarding pathology that was not visible in the image/video clips provided.

Thank you for this referral. If the clinical or image interpretation does not parallel your findings or if I can be of any further assistance, please contact me.

Andrea Nicastro, DVM, Diplomate DACVIM (Small Animal Internal Medicine)
info@SonoPath.com