

**DATE PRESENTING CLINICAL SIGNS**

7.14.2022 Hx of UTIs. Hazy Area in bladder on rads. Worried about possible non radio opaque bladder stones or other causes for recurrent UTIs.

PATIENT

Kai Corbin

Current Medications: Simplicef 100mg SID, Cranberry supplement.
Date of Previous IntraPet Ultrasound: No previous.
Sedation: Not required to complete full diagnostic ultrasound.
Stat Report: Not requested.

SPECIES

Canine

Imaging Performed By: Andi Parkinson, BS, RDMS.

ULTRASONOGRAPHIC EXAMINATION OF THE ABDOMEN**BREED**

Goldendoodle

Urinary System

The **urinary bladder** wall is normal in thickness and the mucosal surface is smooth. The bladder is moderately distended. A small amount of suspended, echogenic debris is observed within the lumen. No masses, inflammatory changes or calculi are observed. Ureteral papillae and visualized portion of the proximal urethra, visible to a depth of 2 cm, are normal.

SEX

Spayed Female

The **left kidney** is normal size (4.83 cm in length); normal shape and architecture with smooth peripheral margins. There is a normal 1:3 cortex to medulla ratio with normal corticomedullary distinction. There is no evidence of pyelectasia, nephroliths, infarcts or hydroureter.

AGE

4.20.2020

The **right kidney** is normal size (5.57 cm in length); normal shape and architecture with smooth peripheral margins. There is a normal 1:3 cortex to medulla ratio with normal corticomedullary distinction. There is no evidence of pyelectasia, nephroliths, infarcts or hydroureter.

WEIGHT

38 lbs

Adrenal Glands

The **left adrenal gland** is normal size (0.48 cm at cranial pole) (0.51 cm at caudal pole) (2.00 cm in length); normal shape; homogenous parenchyma. The glandular echogenicity and detail are unremarkable. Capsule, cortex, and medullary definition are normal. The phrenicoabdominal vein and surrounding vasculature are normal.

INTERPRETED BY

Andrea Nicastro,
DMV, Diplomate
DACVIM (Small Animal
Internal Medicine)

The **right adrenal gland** is normal size (0.57 cm at cranial pole) (0.42 cm at caudal pole) (1.61 cm in length); normal shape; homogenous parenchyma. The glandular echogenicity and detail are unremarkable. Capsule, cortex, and medullary definition are normal. The phrenicoabdominal vein and surrounding vasculature are normal.

HOSPITAL NAME

Healing Paws Vet.
Wellness Ctr

Spleen

The **spleen** is normal in size (1.44 cm in width at the level of the hilus) with a normal capsular contour. There is appropriate echogenicity and echotexture. No focal lesions are observed. Splenic vasculature is normal.

REFERRING VET

Dr. Levitsky

Liver

The **liver** is subjectively normal in size with normal contours and structure. There is appropriate echogenicity and echotexture. No overt structural evidence of inflammatory, infiltrative, or regenerative pathology is evident. Vascular and biliary tracts are of normal volume with no evidence of congestion. No pathological hepatic lymphadenopathy observed.

INVOICE

11225

The **gall bladder** lumen is moderately distended. The wall is thin and smooth. A scant amount of suspended, echogenic debris is observed within the lumen. The cystic and common bile ducts are normal/not seen.

Gastrointestinal

The **stomach and intestine** are free of stasis and exhibit normal peristaltic activity. The gastric lumen is mildly distended with ingesta. The gastric wall is normal in thickness with a normal layering pattern. The small intestinal lumen is not dilated. The small intestinal wall thickness is normal with a normal layering pattern and appropriate mural detail. Discreet masses are not identified. The colonic wall is normal. There is no evidence of an obstructive pattern.

Pancreas

The region of the **pancreas** is isoechoic relative to surrounding omental fat. No obvious parenchymal abnormalities are observed. There is no evidence of regional inflammation or effusion.

Free Abdomen

The **peritoneal cavity** is normal. There is no evidence of inflammation or effusion. The abdominal **lymph nodes** are normal/not visible.

ULTRASONOGRAPHIC FINDINGS

Primary Findings

- The urinary bladder debris could be consistent with cells, crystals and/or exfoliated material. An obvious cause for the patient's recurring urinary tract infections is not identified in this study. Considerations include resistant infection, abnormal external genitalia, underlying metabolic issue, other.

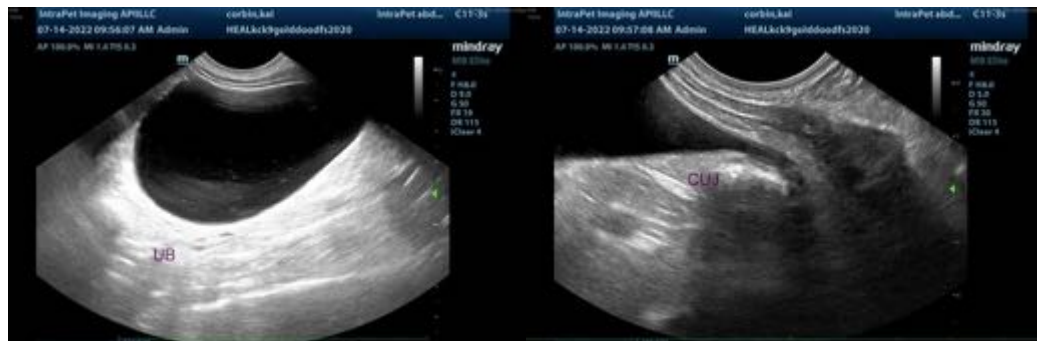
INTERPRETATION OF THE FINDINGS & FURTHER RECOMMENDATIONS

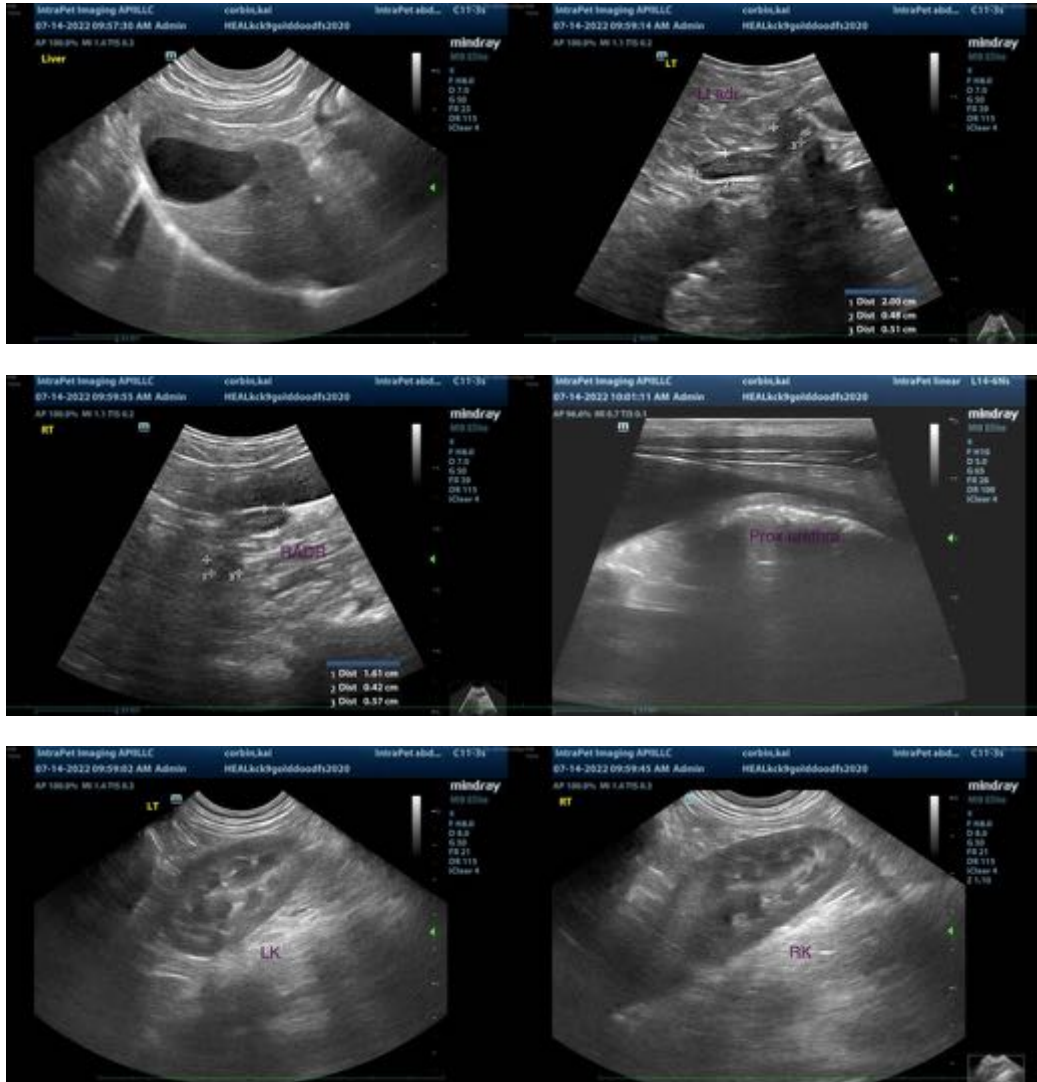
Examination of the external genitalia for abnormalities (i.e., recessed vulva) is recommended, if not already performed.

Baseline lab work, including a CBC Chemistry panel, urinalysis and T4 is also recommended, to assess overall metabolic function.

A urine culture and sensitivity should be performed. A prolonged antibiotic course (i.e., 3 weeks) based on urine culture and sensitivity is recommended with a recheck culture 5-7 days after the last antibiotic dose.

If urinary tract infections persist, a more advanced workup (i.e., contrast cystourethrogram, cystoscopy) may be warranted.





The information and recommendations provided are based on the images presented by the referring veterinarian/sonographer. No evaluation can be communicated regarding pathology that was not visible in the image/video clips provided.

Thank you for this referral. If the clinical or image interpretation does not parallel your findings or if I can be of any further assistance, please contact me.

Andrea Nicastro, DVM, Diplomate DACVIM (Small Animal Internal Medicine)
info@SonoPath.com