

**PATIENT PRESENTING CLINICAL SIGNS**

**PATIENT** Stevie Paulson  
**SPECIES** Feline  
**BREED** Siamese  
**SEX** Female, spayed  
**AGE** 12 Years  
**WEIGHT** 6.5 Pounds

History: Gender(altered?) F Age: 12Y Weight in #: 6.5 Breed: Siamese History: History of vomiting. Mild hematochezia. Patient did vomit up a chunk of tissue that has been save for biopsy depending on what is found on the ultrasound. Physical exam findings: Boring PE. Abdomen was soft and non-painful. No masses noted. Abnormal CBC values: CBC: mild monocytosis Abnormal Chemistry Values: Chem: mild hypoproteinemia. Albumin and globulin low normal. ALT and AST are low T4: WNL Texas GI panel was all WNL, however, cobalamin and folate are at the low end of the reference range. Abnormal UA Values: UA: well concentrated. 2+ proteinuria. UPC 0.2 - borderline Radiograph Findings(email radiographs if available): Reason for Ultrasound: Concern for underlying IBD, lymphoma, gastric mass or ulcerative colitis. Evaluating for cause of low proteins

**ULTRASONOGRAPHIC EXAMINATION OF THE ABDOMEN**

**Urinary System**

The urinary bladder wall is normal in thickness and the mucosal surface is smooth. The bladder lumen is moderately distended. A small amount of suspended echogenic debris is observed within the lumen. No masses, inflammatory changes or calculi are observed. Ureteral papillae and visualized portion of the proximal urethra, visible to a depth of 1 cm, are normal.

The left kidney is borderline small in size (3.01 cm in length) with a slightly irregular shape. There is a normal 1:3 cortex to medulla ratio with moderate loss of corticomedullary distinction. A hyperechoic medullary band is observed at the corticomedullary junction. There is no evidence of pyelectasia, nephroliths, infarcts or hydroureter.

The right kidney is normal size (3.06 cm in length); normal shape and architecture with smooth peripheral margins. There is a normal 1:3 cortex to medulla ratio with moderate loss of corticomedullary distinction. There is no evidence of pyelectasia, nephroliths, infarcts or hydroureter.

**Adrenal Glands**

The left adrenal gland is normal in size (0.33 cm width). Normal shape and glandular echogenicity. The phrenicoabdominal vein and surrounding vasculature are normal.

The right adrenal gland is normal in size (0.33 cm width). Normal shape and glandular echogenicity. The phrenicoabdominal vein and surrounding vasculature are normal.

**Spleen**

The spleen is normal in size (0.64 cm in width at the level of the hilus) with a normal capsular contour. There is appropriate echogenicity and echotexture. No focal lesions are observed. Splenic vasculature is normal.

**Liver**

The liver is normal to slightly prominent in size with normal curvilinear peripheral contours. The parenchyma is isoechoic relative to the spleen and diffusely homogeneous in appearance. No distinct focal lesions are observed. Vascular and biliary tracts are of normal volume with no evidence of congestion. The gall bladder lumen is moderately distended. The wall is thin and smooth. A small amount of suspended echogenic debris is observed within the lumen. The cystic and common bile ducts are normal/not seen.

**Gastrointestinal**

**INTERPRETED BY**

Andrea Nicastro, DVM,  
Diplomate ACVIM  
(Small Animal Internal  
Medicine)

**IMAGING PERFORMED BY**

Loetitia Saint-Jacques, RVT

**HOSPITAL NAME**

Alpine AH

**REFERRING VET**

Dr. Sjoloin

**INVOICE**

13514

**DATE**

7/11/22



**PATIENT**

Stevie Paulson

**SPECIES**

Feline

**BREED**

Siamese

**SEX**

Female, spayed

**AGE**

12 Years

**WEIGHT**

6.5 Pounds

**INTERPRETED BY**

Andrea Nicastro, DVM,  
Diplomate ACVIM  
(Small Animal Internal  
Medicine)

**IMAGING PERFORMED BY**

Loetitia Saint-Jacques, RVT

**HOSPITAL NAME**

Alpine AH

**REFERRING VET**

Dr. Sjoloin

**INVOICE**

13514

**DATE**

7/11/22

The gastric lumen is mildly fluid distended. The gastric wall in the region of the fundus is severely thickened (up to 2.03 cm), irregular and hypoechoic to heterogeneous in appearance with loss of the normal layering pattern. The mesentery adjacent to the thickened wall is hyperechoic. The pyloric outflow tract is patent. The small intestinal lumen is not dilated. The small intestinal wall thickness is normal with a normal layering pattern and appropriate mural detail. The ileocecolic junction is normal. The wall of the descending colonic is borderline thickened (up to 0.27 cm) with retention of the normal layering pattern. No obstructive disease is noted.

**Pancreas**

A portion of the pancreas is obscured by the gastric pathology. In the visualized portions, no obvious abnormalities are seen.

**Free Abdomen**

Trace free fluid is observed. A gastric lymph node is visualized (1.05 x 0.69 cm). In addition, a few prominent mesenteric lymph nodes are seen, the largest measuring 1.57 cm in length. 1-2 prominent lymph nodes are also seen in the right cranial quadrant.

**Other**

A brief echocardiogram reveals no evidence of pericardial effusion.

**ULTRASONOGRAPHIC FINDINGS**

**Primary Findings:**

- Gastric wall mass effect. Neoplasia (i.e., adenocarcinoma, lymphoma) is considered likely with a lower possibility of benign pathology (i.e., pyogranulomatous inflammation). Regional peritonitis is present.
- The abdominal lymphadenopathy could be consistent with reactive lymphadenitis, lymphoid hyperplasia or metastatic disease/infiltrative neoplasia.

**Secondary Findings:**

- The hepatic parenchymal changes are non-specific and may be a normal variant for this patient. Alternatively, early hepatic lipidosis, inflammatory disease, or infiltrative neoplasia may be present.

**INTERPRETATION OF THE FINDINGS & FURTHER RECOMMENDATIONS**

- Three-view thoracic radiographs are recommended to assess for pulmonary metastases.
- Consider a fine needle aspirate of the gastric wall if clotting status is appropriate. A 25-gauge needle should be used. If cytology results are inconclusive, endoscopic or surgical biopsies of the gastric wall may be necessary to get a definitive diagnosis. If surgical biopsies are pursued, abdominal lymph nodes should also be biopsied.
- Also consider a malabsorption panel including serum cobalamin, folate, TLI and PLI.



**PATIENT**

Stevie Paulson

**SPECIES**

Feline

**BREED**

Siamese

**SEX**

Female, spayed

**AGE**

12 Years

**WEIGHT**

6.5 Pounds

**INTERPRETED BY**

Andrea Nicastro, DVM,  
Diplomate ACVIM  
(Small Animal Internal  
Medicine)

**IMAGING PERFORMED BY**

Loetitia Saint-Jacques, RVT

**HOSPITAL NAME**

Alpine AH

**REFERRING VET**

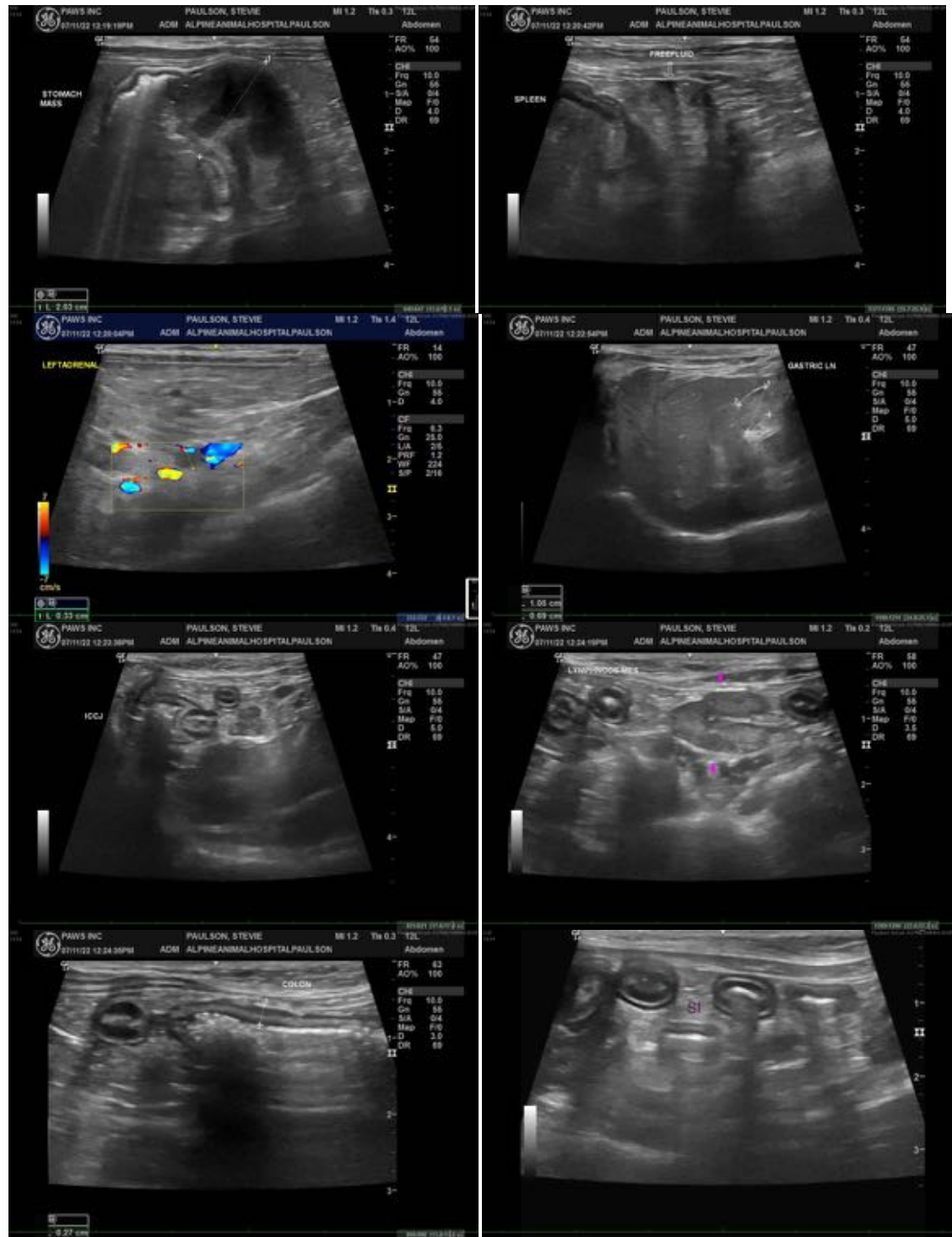
Dr. Sjoloin

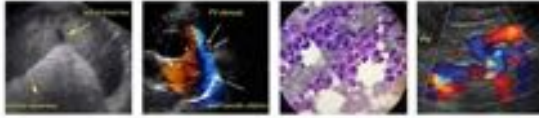
**INVOICE**

13514

**DATE**

7/11/22





**PATIENT**

Stevie Paulson

**SPECIES**

Feline

**BREED**

Siamese

**SEX**

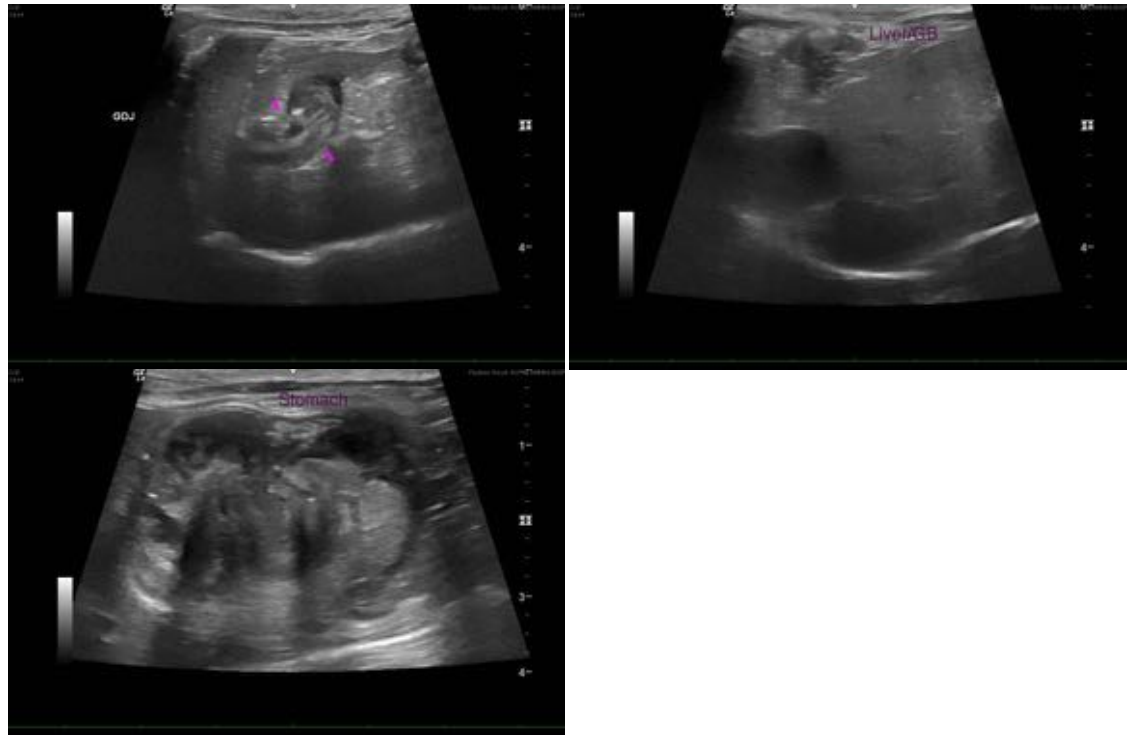
Female, spayed

**AGE**

12 Years

**WEIGHT**

6.5 Pounds



**INTERPRETED BY**

Andrea Nicastro, DVM,  
Diplomate ACVIM  
(Small Animal Internal  
Medicine)

**IMAGING PERFORMED BY**

Loetitia Saint-Jacques, RVT

**HOSPITAL NAME**

Alpine AH

**REFERRING VET**

Dr. Sjloin

**INVOICE**

13514

**DATE**

7/11/22

The information and recommendations provided are based on the images presented by the referring veterinarian/sonographer. No evaluation can be communicated regarding pathology that was not visible in the image/video clips provided.

Thank you for this referral. If the clinical or image interpretation does not parallel your findings or if I can be of any further assistance, please contact me.

Andrea Nicastro, DVM, Diplomate ACVIM (Small Animal Internal Medicine)

[andrea.nicastro@sonopath.com](mailto:andrea.nicastro@sonopath.com)