



DATE PRESENTING CLINICAL SIGNS

6/8/26

Patient History: Pet Exam on 5/19/26: P presents for hepatic panel recheck. O states P still isn't eating as much. Will take about a few bites or a 1/4 of each meal and be done. Still drinking enough water. No vi/di; peed outside litterbox twice but overall normal habits. P doesn't seem overly lethargic. P has been getting a little frumpy with her siblings but unsure if she's just annoyed or there's something else bothering her. Pet has been slowly gaining weight over the past year but is a BCS 5/9.

PATIENT

Shayna Mogollon

SPECIES

Feline

Current Medications: None.

Labwork Results: Labwork not attached, reported as: ALT 4/17 179, 5/18 163. Mass Cytology: basilar type epithelial neoplasm or an adnexal/follicular growth (eg. trichoblastoma, basal cell tumor, etc.). These are generally benign with excision being curative in most cases.

Date of Previous IntraPet Ultrasound: No previous.

Sedation: Not required to complete full diagnostic ultrasound.

Stat Report: Not requested.

Imaging Performed by: Stephanie Warga RDCS, RVT.

BREED

Domestic shorthair

SEX

Female, spayed

ULTRASONOGRAPHIC EXAMINATION OF THE ABDOMEN

Urinary System

The urinary bladder wall is normal in thickness and the mucosal surface is smooth. The bladder is moderately distended. A moderate amount of suspended echogenic debris is observed within the lumen. No cystic calculi are observed. The region of the trigone and the visible portion of the proximal urethra are normal.

AGE

9/17/2018

The left kidney is normal in size (3.99 cm in length) with a normal shape, architecture and smooth peripheral margins. There is a normal 1:3 cortex to medulla ratio with mild to moderate loss of corticomedullary distinction. There is no evidence of pyelectasia, nephroliths, infarcts or hydroureter. Renal vasculature is normal.

WEIGHT

6.74 kg.

The right kidney is normal in size (4.20 cm in length) with a normal shape, architecture and smooth peripheral margins. There is a normal 1:3 cortex to medulla ratio with normal corticomedullary distinction. There is no evidence of pyelectasia, nephroliths, infarcts or hydroureter. Renal vasculature is normal.

INTERPRETED BY

Andrea Nicastro, DVM,
Diplomate ACVIM
(Small Animal Internal
Medicine)

Adrenal Glands

The left adrenal gland is normal size (0.28 cm width). Normal shape and glandular echogenicity. The phrenicoabdominal vein and surrounding vasculature are normal.

HOSPITAL NAME

Banfield Columbia

The right adrenal gland is normal size (0.36 cm width). Normal shape and glandular echogenicity. The phrenicoabdominal vein and surrounding vasculature are normal.

REFERRING VET

Dr. Landon

Spleen

The spleen is normal in size (0.81 cm in width at the level of the hilus) with a normal capsular contour. There is appropriate echogenicity and echotexture. No focal lesions are observed. Splenic vasculature is normal.

INVOICE

13598

Liver

The liver is subjectively normal in size with normal curvilinear peripheral contours. The parenchyma is isochoic relative to the spleen and diffusely homogeneous in appearance. No distinct focal lesions are observed. Vascular and biliary tracts are of normal volume with no evidence of congestion.

The gall bladder lumen is moderately distended. The wall is thin and smooth. A scant amount of echogenic debris is observed within the lumen. The cystic and common bile ducts are normal.

Gastrointestinal

The stomach and intestine are free of stasis and exhibit normal peristaltic activity. The gastric lumen is mildly distended with ingesta. The gastric wall and pylorus are normal in thickness with a normal layering pattern. The pyloric outflow tract is patent. The small intestinal lumen is segmentally dilated with gas and chyme. The small intestinal wall thickness is normal. There is disruption in the normal 1:3 muscularis: mucosal ratio in several segments. Discreet masses are not identified. The ileocecal colic junction and colonic wall are normal. No obstructive disease is noted.

Pancreas

The pancreas is normal in size with normal peripheral contours. The pancreatic duct is normal. The base and limbs of the pancreas are isoechoic to surrounding omental fat. No focal lesions are observed. There is no evidence of peripancreatic inflammation or effusion.

Lymph nodes

The abdominal lymph nodes are normal/not visible.

Free Abdomen

The peritoneal cavity is normal. There is no evidence of inflammation or effusion.

ULTRASONOGRAPHIC FINDINGS

Primary Findings:

- The small intestinal wall changes could be consistent with inflammatory bowel disease. However, emerging lymphoma cannot be completely excluded.
- If the patient was fasted for this study, the presence of ingesta within the gastric lumen could suggest delayed gastric emptying.

Secondary Findings:

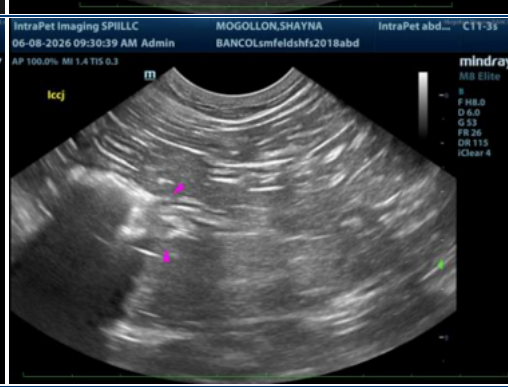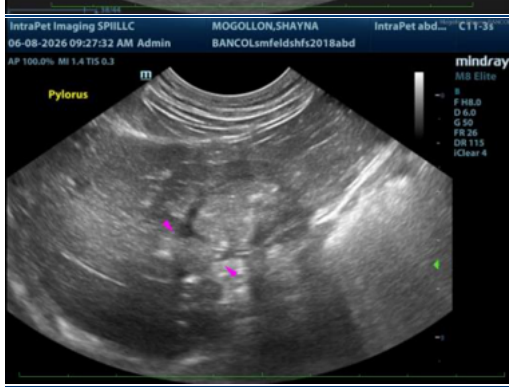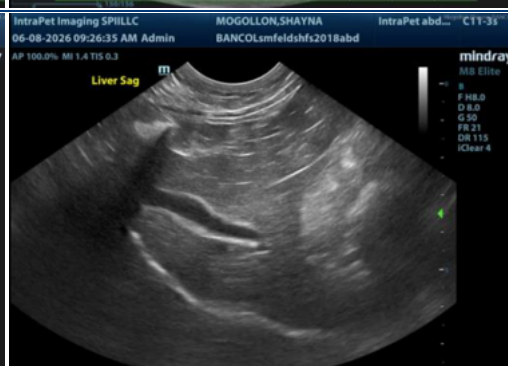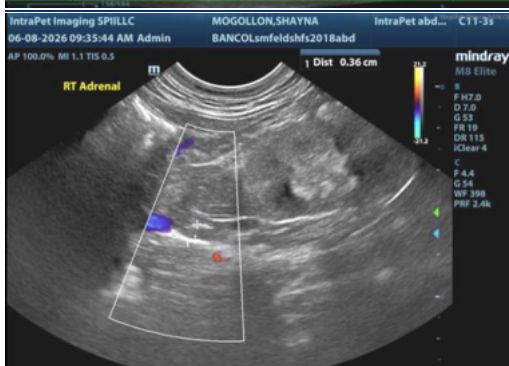
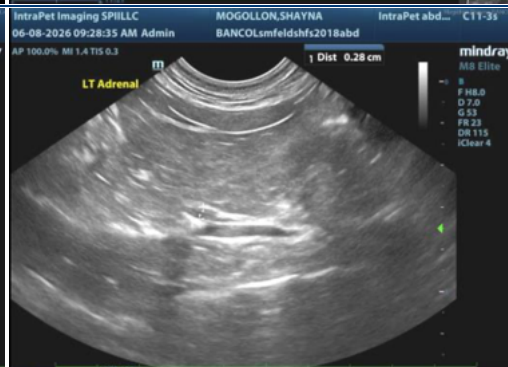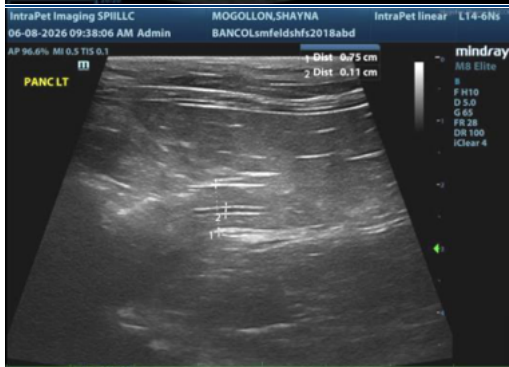
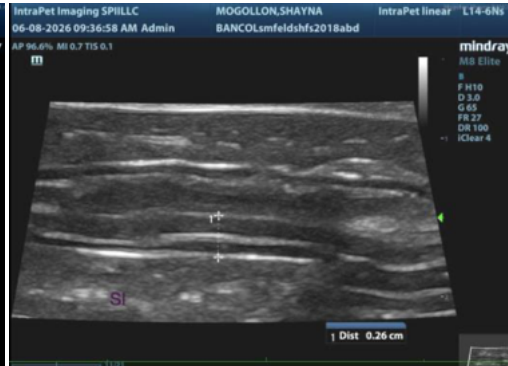
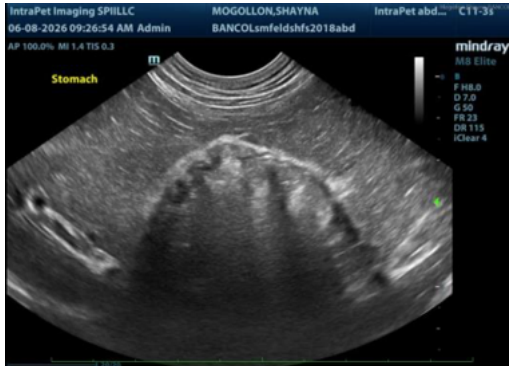- Bilateral, nonspecific age-related renal changes

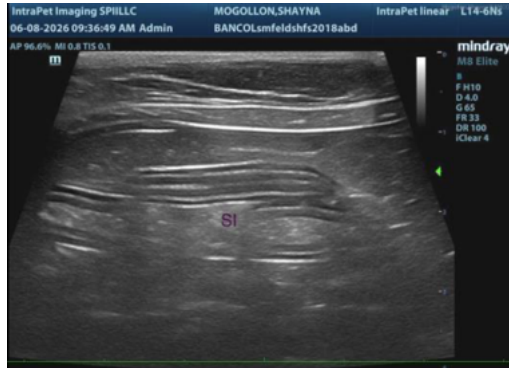*An obvious cause for the elevated liver enzymes is not identified in the study. However, a microscopic hepatopathy (i.e., bacterial cholangiohepatitis, lymphoplasmacytic hepatitis, hepatic lipidosis, reactive hepatopathy or infiltrative neoplasia (less likely) should be considered.

INTERPRETATION OF THE FINDINGS & FURTHER RECOMMENDATIONS

Given the patient's clinical history, consider the following:

1. Fecal evaluation for ova and Giardia
2. GI panel including serum cobalamin, folate, TLI and PLI
3. Pre and post-prandial serum bile acids
4. Three-view thoracic radiographs to assess for occult pathology in the chest
5. Depending on the results of the above diagnostics, further workup (i.e., GI and/or liver biopsies) may be warranted.





The information and recommendations provided are based on the images presented by the referring veterinarian/sonographer. No evaluation can be communicated regarding pathology that was not visible in the image/video clips provided.

Thank you for this referral. If the clinical or image interpretation does not parallel your findings or if I can be of any further assistance please contact me.

Andrea Nicastro, MPH, DVM, Diplomate DACVIM (Small Animal Internal Medicine) info@SonoPath.com