


PATIENT PRESENTING CLINICAL SIGNS

Salior Panette

Abnormal PE/Chem/CBC/UA Results: H Reticulocytes 154.0 (possibly secondary to mild bleeding in GI from IBD etc)

SPECIES

Canine

ULTRASONOGRAPHIC EXAMINATION OF THE ABDOMEN
BREED

Pomeranian Mix

Urinary System

The urinary bladder, trigone, and pelvic urethra are normal in thickness and the mucosal surface is smooth. The bladder lumen is moderately distended with anechoic urine. No masses, inflammatory changes or calculi are observed. Ureteral papillae and visualized portion of the proximal urethra, visible to a depth of 2 cm, are normal.

SEX

Neutered Male

The prostate is normal in size (0.55 cm in width) and shape. Parenchyma is homogenous. The prostatic urethra appears normal without evidence of dilation or obstruction.

AGE

10 years

The left kidney is normal in size (3.74 cm in length) with a normal shape, smooth peripheral margins, and normal internal architecture. There is mild loss of corticomedullary distinction. Several hyperechoic shadowing diverticular foci are observed. There is no evidence of pyelectasia, infarcts or hydronephrosis.

WEIGHT

7.1 lbs

The right kidney is normal in size (3.97 cm in length) with a normal shape, smooth peripheral margins, and normal internal architecture. There is mild loss of corticomedullary distinction. Several hyperechoic shadowing diverticular foci are observed. There is no evidence of pyelectasia, infarcts or hydronephrosis.

INTERPRETED BY

Andrea Nicastro,
 DVM, Diplomate
 ACVIM (*Small Animal
 Internal Medicine*)

Adrenal Glands

The left adrenal gland is normal size (0.38 cm at cranial pole) (0.42 cm at caudal pole) (1.31 cm in length); normal shape; homogenous parenchyma. The glandular echogenicity and detail are unremarkable. Capsule, cortex, and medullary definition are normal. The phrenicoabdominal vein and surrounding vasculature are normal.

IMAGING PERFORMED BY

Andrew Holmes

The right adrenal gland is normal size (0.39 cm at cranial pole) (0.49 cm at caudal pole) (1.98 cm in length); normal shape; homogenous parenchyma. The glandular echogenicity and detail are unremarkable. Capsule, cortex, and medullary definition are normal. The phrenicoabdominal vein and surrounding vasculature are normal.

HOSPITAL NAME

Cedarview AH

Spleen

The spleen is normal in size (1.28 cm in width at the level of the hilus) with a normal capsular contour. There is appropriate echogenicity and echotexture. No focal lesions are observed. Splenic vasculature is normal.

REFERRING VET

Dr. Andrew Holmes

Liver

The liver is normal to slightly small in size with normal curvilinear peripheral contours. The parenchyma is hypoechoic relative to the spleen and homogenous in appearance. No focal lesions are observed. Hepatic vasculature and intrahepatic biliary tracts are of normal volume with no evidence of congestion. The portal vein to caudal vena cava ratio is approximately 1: 1.

INVOICE

11036

DATE

6/8/22

The gall bladder lumen is moderately distended. The wall is thin and smooth. A small amount of mostly gravity dependent, echogenic debris is observed within the lumen. The cystic and common bile ducts are normal/not seen.

Gastrointestinal

The gastric lumen is gas distended. The gastric wall is normal in thickness with a normal layering pattern. The small intestinal lumen is not dilated. The small intestinal wall thickness is normal with a normal layering pattern and appropriate mural detail. Discreet masses are not identified. The colonic wall is normal. The colonic lumen contains shadowing fecal material.

Pancreas

The right limb of the pancreas is visible and normal in size with normal curvilinear peripheral contours. The parenchyma is largely isoechoic relative to surrounding omental fat and slightly mottled in appearance. The pancreatic duct is visible but not overtly dilated. There is no evidence of peripancreatic inflammation or effusion.

Free Abdomen

The peritoneal cavity is normal. There is no evidence of inflammation or effusion. The abdominal lymph nodes are normal/not visible.

ULTRASONOGRAPHIC FINDINGS

Primary Findings

- The pancreatic changes are most consistent with age-related parenchymal remodeling, potentially secondary to a prior inflammatory episode, early fibrosis or chronic pancreatitis.
- Bilateral, minor, chronic renal changes with dystrophic mineralization

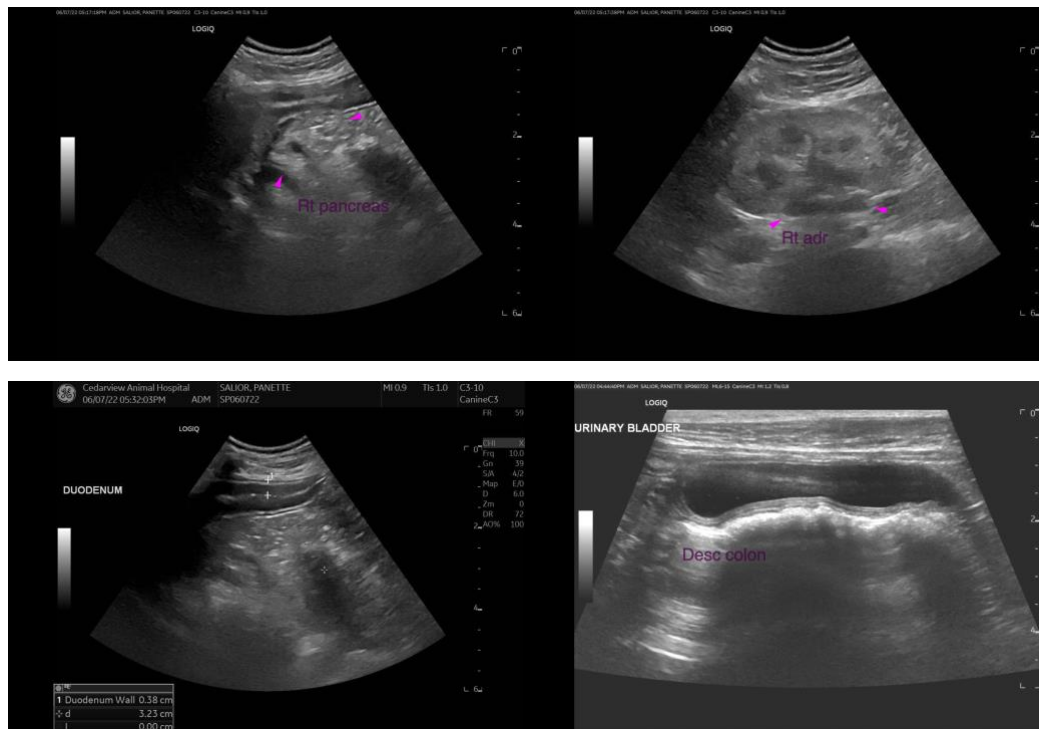
*An obvious cause for the patient's gastrointestinal signs is not identified in this study. Considerations include microscopic gastrointestinal disease (i.e., infectious/parasitic, food allergy/intolerance, inflammatory bowel disease), low-grade pancreatitis, underlying metabolic issue, other.

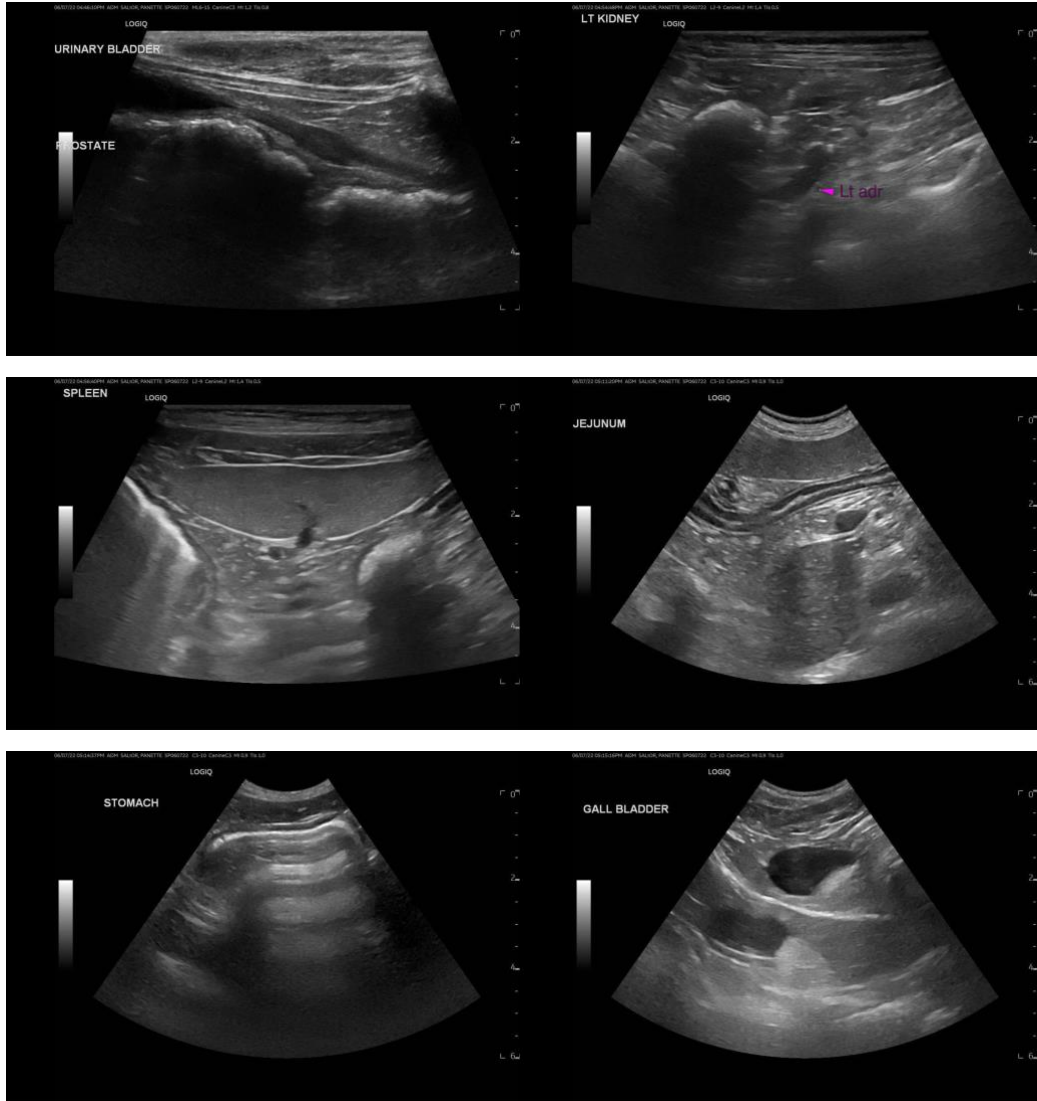
INTERPRETATION OF THE FINDINGS & FURTHER RECOMMENDATIONS

The following diagnostics/treatment recommendations can be considered:

1. Serum cobalamin, folate, PLI and TLI
2. A fecal evaluation for ova/Giardia
3. Consider a fecal PCR panel for infectious diseases.

4. Prophylactic deworming with Fenbendazole at 50 mg/kg once a day for 5 days is recommended. Repeat above protocol in 3 weeks.
5. A 6-week limited antigen diet trial to assess for food allergies.
6. Consider a 4-week course of Tylosin at 15-20 mg/kg by mouth every 12 hours as empirical treatment for small intestinal bacterial overgrowth.
7. A resting cortisol level to screen for hypoadrenocorticism. If resting cortisol level is < 2.0 mcg/dL, an ACTH stimulation test is recommended.
8. Depending on the results of the above diagnostics/therapeutics, endoscopic or surgical gastrointestinal biopsies may be warranted.
9. Three-view thoracic radiographs are recommended to assess for occult esophageal disease and to assess cardiopulmonary status.





The information and recommendations provided are based on the images presented by the referring veterinarian/sonographer. No evaluation can be communicated regarding pathology that was not visible in the image/video clips provided.

Thank you for this referral. If the clinical or image interpretation does not parallel your findings or if I can be of any further assistance, please contact me.

Andrea Nicastro, DVM, Diplomate DACVIM (Small Animal Internal Medicine)
info@SonoPath.com

