



**PATIENT**

Dutch Tetteris

**SPECIES**

Canine

**BREED**

German Shorthair  
Pointer

**SEX**

Intact Male

**AGE**

5 years

**WEIGHT**

60 lbs

**INTERPRETED BY**

Andrea Nicastro,  
DVM, Diplomate  
ACVIM (*Small Animal  
Internal Medicine*)

**IMAGING  
PERFORMED BY**

Michelle Bartus

**HOSPITAL NAME**

Valley Vet Svc Inc

**REFERRING VET**

Michelle Bartus

**INVOICE**

11030

**DATE**

6/7/22

**PRESENTING CLINICAL SIGNS**

History: Intact male, blood drips from penis intermittently. Normal urine stream. Dog is acting normal.  
Abnormal PE/Chem/CBC/UA Results: Referring vet did a urinalysis last week: Sp. Gr. 1.026 pH 7.0, Prot 30 Leuk 100 Bld 250, WBC 18 hpf, RBC >50 hpf

\*\*This study was limited to the urinary system. There is a potential for pathology in organs that were not visualized.

**ULTRASONOGRAPHIC EXAMINATION OF THE ABDOMEN**

**Urinary System**

The urinary bladder, trigone, and pelvic urethra are normal in thickness and the mucosal surface is smooth. The bladder lumen is moderately distended with anechoic urine. No masses, inflammatory changes or calculi are observed. Ureteral papillae and visualized portion of the proximal urethra, visible to a depth of 2-3 cm, are normal.

The prostate is enlarged (4.34 cm in width) with a slightly irregular shape. The parenchyma is hyperechoic relative to the spleen and mildly heterogenous in appearance. Ill-defined fluid pockets, which contain suspended echogenic debris, are observed within the parenchyma. A small amounts of capsular fluid is present.

The left kidney is normal size (6.53 cm in length); normal shape and architecture with smooth peripheral margins. There is a normal 1:3 cortex to medulla ratio with minimal loss of corticomedullary distinction. There is no evidence of pyelectasia, nephroliths, infarcts or hydroureter

The right kidney is normal size (7.28 cm in length); normal shape and architecture with smooth peripheral margins. There is a normal 1:3 cortex to medulla ratio with minimal loss of corticomedullary distinction. There is no evidence of pyelectasia, nephroliths, infarcts or hydroureter. Renal vasculature is normal.

**Adrenal Glands**

The left adrenal gland is normal size (0.57 cm at cranial pole) (0.60 cm at caudal pole); normal shape; homogenous parenchyma. The glandular echogenicity and detail are unremarkable. Capsule, cortex, and medullary definition are normal. The phrenicoabdominal vein and surrounding vasculature are normal.

The caudal pole of the right adrenal gland is visualized and is normal in size (0.65 cm in width); with a normal shape, glandular echogenicity and detail. The phrenicoabdominal vein and surrounding vasculature appear normal.

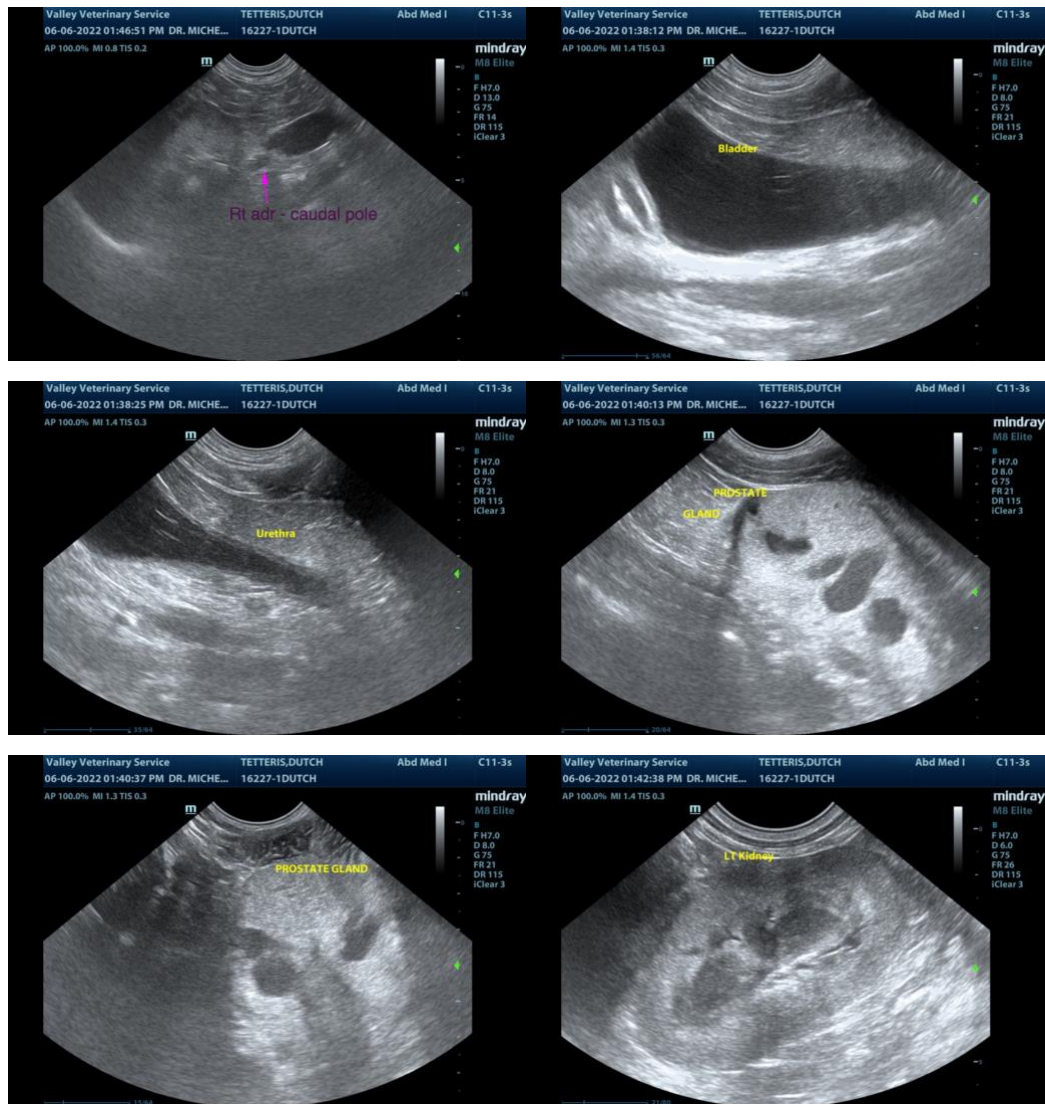
**ULTRASONOGRAPHIC FINDINGS**

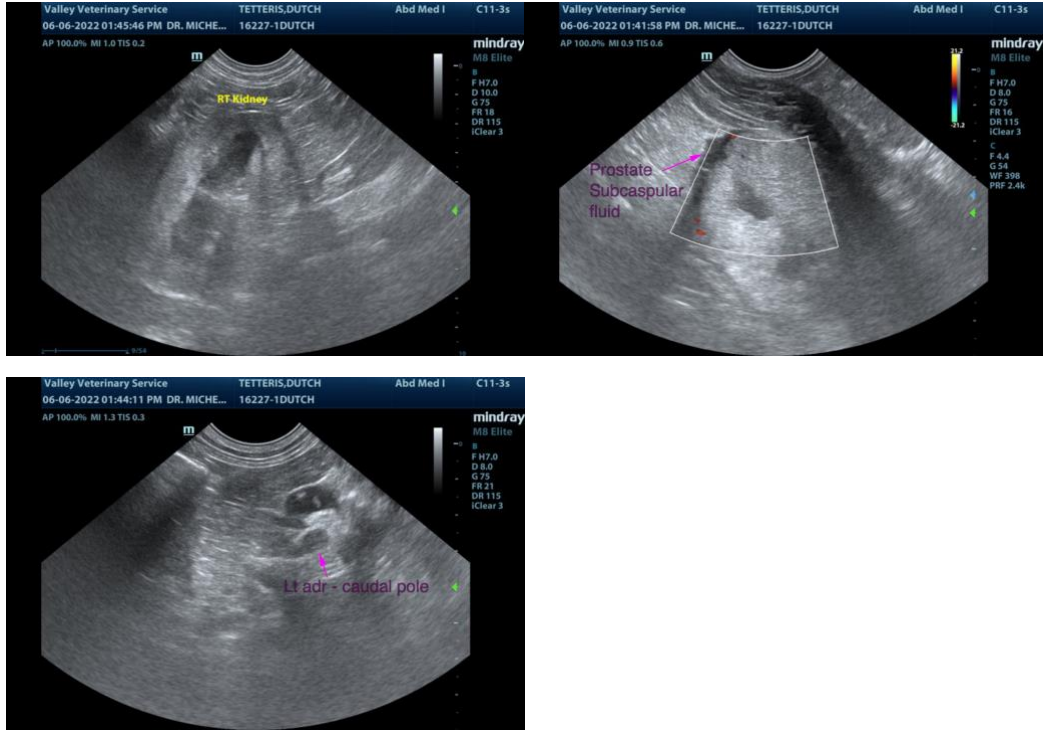
**Primary Findings**

- Given the patient's clinical history and sonographic changes, benign prostatic hyperplasia with concurrent bacterial prostatitis is suspected. The fluid pockets within the prostatic parenchyma may represent parenchymal cysts or abscessed areas.

## INTERPRETATION OF THE FINDINGS & FURTHER RECOMMENDATIONS

- A urine culture and sensitivity is recommended.
- While awaiting test results, initiation of a broad-spectrum antibiotic (i.e., fluoroquinolone) should be considered.
- Castration is strongly recommended. Consider consultation with a board-certified surgeon to determine if omentalization of the prostate is warranted.
- Consider a complete abdominal ultrasound to rule out pathology in other organs.





The information and recommendations provided are based on the images presented by the referring veterinarian/sonographer. No evaluation can be communicated regarding pathology that was not visible in the image/video clips provided.

Thank you for this referral. If the clinical or image interpretation does not parallel your findings or if I can be of any further assistance, please contact me.

**Andrea Nicastro, DVM, Diplomate DACVIM (Small Animal Internal Medicine)**  
info@SonoPath.com