



PATIENT

Dak Giessler

PRESENTING CLINICAL SIGNS

History: Febrile, anorexic, listless, palpable intra-abdominal mass. Current meds: Convenia given 6/4.

SPECIES

Feline

Abnormal PE/Chem/CBC/UA Results: SDMA 20, BUN 77, Creat 2.1, Phos 11.7, TBili 2.6, ALP <10. CBC pending

BREED

DSH

ULTRASONOGRAPHIC EXAMINATION OF THE ABDOMEN

Urinary System

The urinary bladder, trigone, and pelvic urethra are normal in thickness and the mucosal surface is smooth. The bladder lumen is moderately distended. A moderate amount of suspended, echogenic debris is observed within the lumen. No masses, inflammatory changes or calculi are observed. Ureteral papillae and visualized portion of the proximal urethra, visible to a depth of 2 cm, are normal.

SEX

Neutered Male

AGE

2 years

The left kidney is borderline enlarged (4.49 cm in length); with a normal shape and smooth peripheral contours. There is a normal 1:3 cortex to medulla ratio with normal corticomedullary distinction. Trace pyelectasia is present. There is no evidence of nephroliths, infarcts or hydronephrosis. Renal vasculature is normal.

WEIGHT

9.1 lbs

The right kidney is mildly enlarged (4.58 cm in length); with a normal shape architecture and smooth peripheral contours. There is a normal 1:3 cortex to medulla ratio with normal corticomedullary distinction. There is no evidence of pyelectasia, nephroliths, infarcts or hydronephrosis. Renal vasculature is normal.

INTERPRETED BY

Andrea Nicastro, DVM,
Diplomate ACVIM
(Small Animal Internal
Medicine)

Adrenal Glands

The left adrenal gland is normal size (0.50 cm length; 0.42 cm width). Normal shape and glandular echogenicity. The phrenicoabdominal vein and surrounding vasculature are normal.

The right adrenal gland is normal size (1.00 cm length; 0.47 cm width). Normal shape and glandular echogenicity. The phrenicoabdominal vein and surrounding vasculature are normal.

IMAGING PERFORMED BY

Shari Reffi, CVT

Spleen

The spleen is prominent in size (1.05 cm in width at the level of the hilus) with slightly swollen peripheral contours. The parenchyma is subtly mottled in appearance. No focal lesions are observed. Splenic vasculature is normal with no evidence of thrombosis.

HOSPITAL NAME

Morris Hills VC

Liver

The liver is subjectively normal in size with normal contours and structure. There is appropriate echogenicity and echotexture. No overt structural evidence of inflammatory, infiltrative, or regenerative pathology is evident. Vascular and biliary tracts are of normal volume with no evidence of congestion. No pathological hepatic lymphadenopathy observed.

REFERRING VET

Dr. Hirshenson

INVOICE

11032

The gall bladder lumen is moderately distended. The wall is thin and smooth. A small amount of suspended, echogenic debris is observed within the lumen. The cystic and common bile ducts are normal/not seen.

DATE

6/6/22



PATIENT

Gastrointestinal

Dak Giessler

The gastric lumen is mildly to moderately fluid distended and hypomotile. The gastric wall and pylorus are normal in thickness with a normal layering pattern. The small intestinal lumen is not dilated. The small intestinal wall thickness is normal with a normal layering pattern and appropriate mural detail. Discreet masses are not identified. The ileocecolic junction and colonic wall are normal. There is no evidence of an obstructive pattern.

SPECIES

Feline

BREED

Pancreas

DSH

The region of the pancreas is isoechoic relative to surrounding omental fat. No obvious parenchymal abnormalities are observed. There is no evidence of regional inflammation or effusion.

SEX

Free Abdomen

Neutered Male

Trace free fluid is observed. A 1.16 x 0.29 cm lymph node is observed just caudal to the stomach. In addition, several, enlarged, irregular, hypoechoic lymph nodes are observed in the midabdomen, the largest measuring 3.43 cm in length. The mesentery surrounding all nodes is hyperechoic.

AGE

2 years

Other

A brief echocardiogram reveals no evidence of pericardial effusion or obvious right atrial/auricular mass.

WEIGHT

9.1 lbs

ULTRASONOGRAPHIC FINDINGS

INTERPRETED BY

Primary Findings

Andrea Nicastro, DVM,
Diplomate ACVIM
(Small Animal Internal
Medicine)

- The abdominal lymphadenopathy is concerning for infiltrative neoplasia (i.e., lymphoma). However, pyogranulomatous lymphadenitis cannot be completely excluded. Adjacent peritonitis is present.
- The mild splenomegaly may be a normal variant for this patient or may be secondary to lymphoid hyperplasia, extramedullary hematopoiesis, infiltrative neoplasia, splenitis, antigenic stimulation, other.
- The mild bilateral adrenomegaly could be consistent with an inflammatory disease (i.e., interstitial nephritis), infiltrative neoplasia or normal variation.

IMAGING PERFORMED BY

Shari Reffi, CVT

HOSPITAL NAME

Morris Hills VC

Secondary Findings

REFERRING VET

Dr. Hirshenson

- Mild to moderate gastric ileus
- Urinary bladder debris

INVOICE

11032

INTERPRETATION OF THE FINDINGS & FURTHER RECOMMENDATIONS

- Feline leukemia and FIV testing is recommended if not already performed.

DATE

6/6/22



PATIENT

Dak Giessler

- Consider fine-needle aspiration of the large abdominal lymph nodes +/- spleen if clotting status is appropriate. If cytology results are inconclusive, flow cytometry or surgical biopsies may be necessary to get a definitive diagnosis.

SPECIES

Feline

BREED

DSH

SEX

Neutered Male

AGE

2 years

WEIGHT

9.1 lbs

INTERPRETED BY

Andrea Nicastro, DVM,
Diplomate ACVIM
(Small Animal Internal
Medicine)

IMAGING PERFORMED BY

Shari Reffi, CVT

HOSPITAL NAME

Morris Hills VC

REFERRING VET

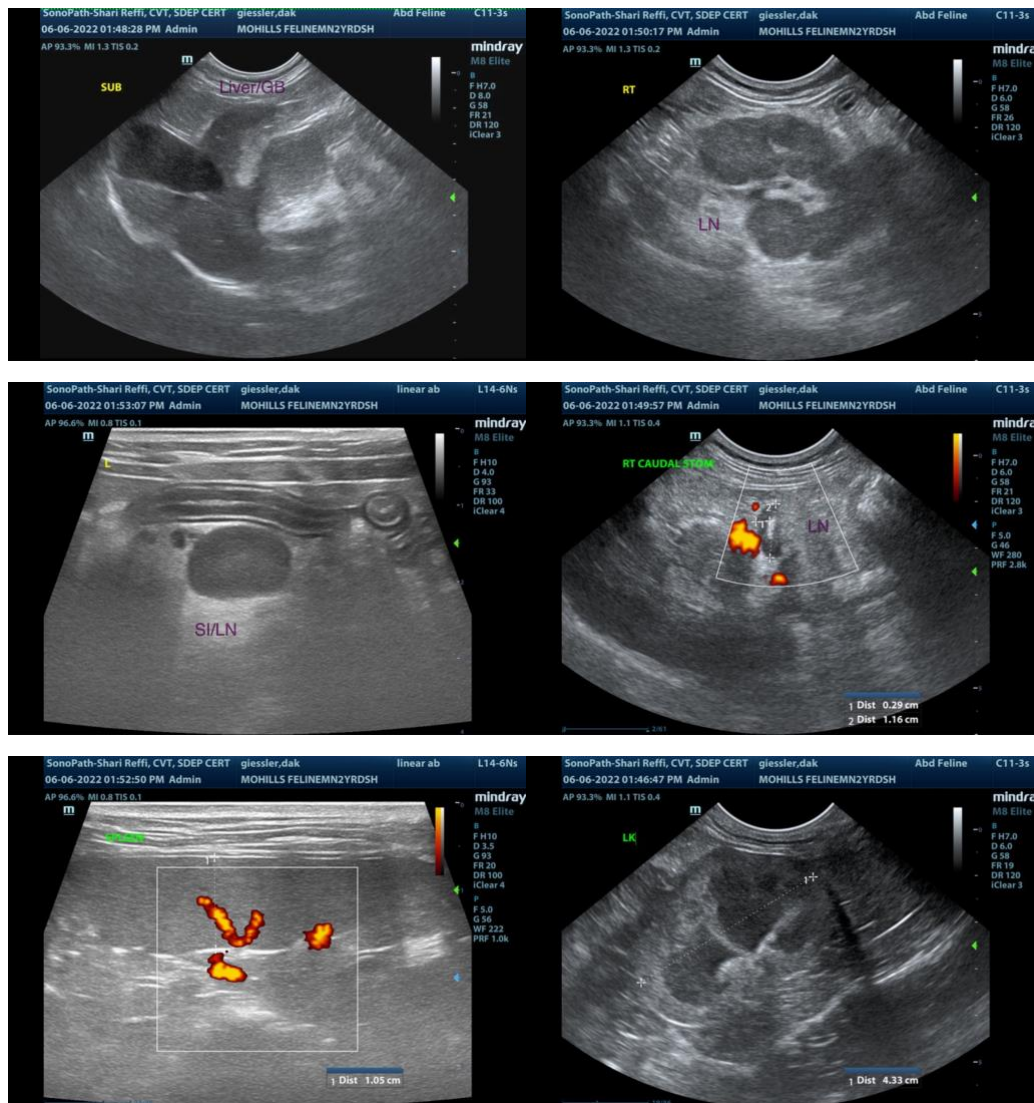
Dr. Hirshenson

INVOICE

11032

DATE

6/6/22





PATIENT

Dak Giessler

SPECIES

Feline

BREED

DSH

SEX

Neutered Male

AGE

2 years

WEIGHT

9.1 lbs

INTERPRETED BY

Andrea Nicastro, DVM,
Diplomate ACVIM
(Small Animal Internal
Medicine)

IMAGING PERFORMED BY

Shari Reffi, CVT

HOSPITAL NAME

Morris Hills VC

REFERRING VET

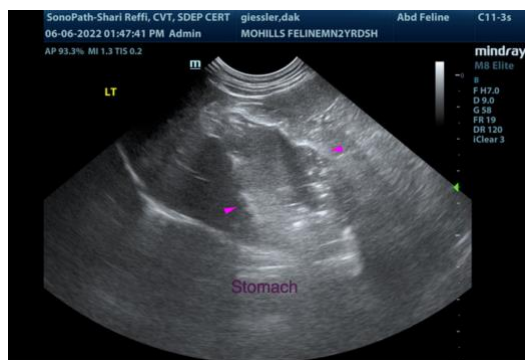
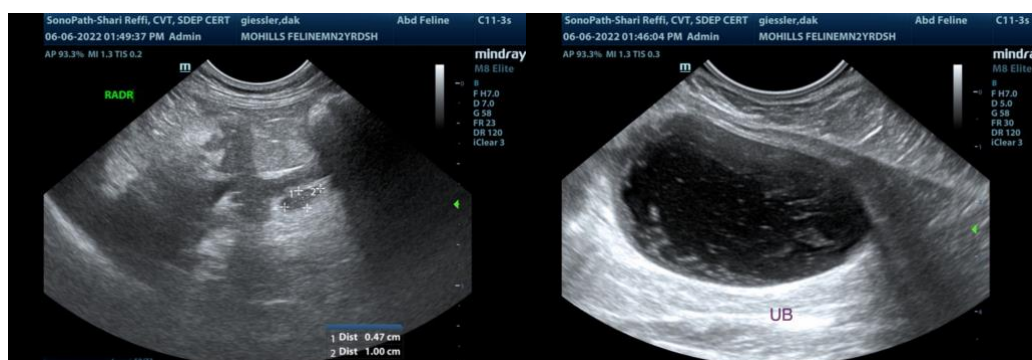
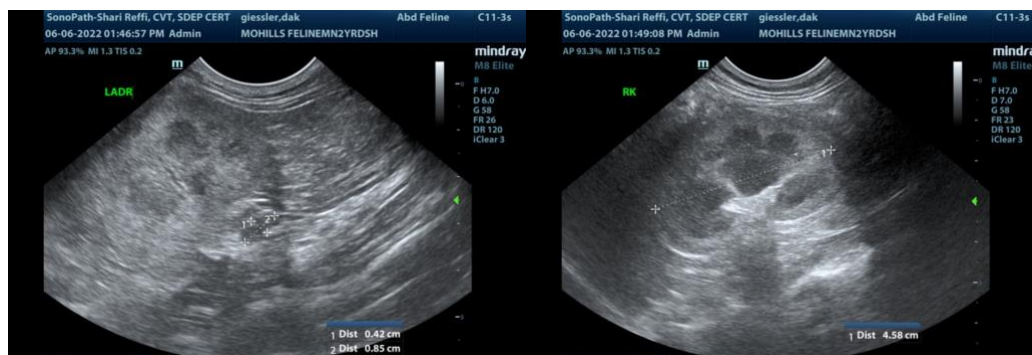
Dr. Hirshenson

INVOICE

11032

DATE

6/6/22



The information and recommendations provided are based on the images presented by the referring veterinarian/sonographer. No evaluation can be communicated regarding pathology that was not visible in the image/video clips provided.

Thank you for this referral. If the clinical or image interpretation does not parallel your findings or if I can be of any further assistance, please contact me.

Andrea Nicastro, DVM, Diplomate DACVIM (Small Animal Internal Medicine)
info@SonoPath.com