



## PATIENT PRESENTING CLINICAL SIGNS

Gracie Riles History: PU/PD; appetite down, chewing less hx heart murmur on pimobendan and ursodiol previous AUS w/ you guys in 11/2021

**SPECIES** Abnormal PE/Chem/CBC/UA Results: ALKP 175 U/L 5 - 160 : : | HIGH TRIG 871 mg/dL 20 - 150 : : | HIGH otherwise CBC/Chem/T4 wnl/cPL wnl UA: pH 6 SP GRAVITY 1.013 no oral abnormalities noted

Canine

## ULTRASONOGRAPHIC EXAMINATION OF THE ABDOMEN

### BREED *Urinary System*

Dachshund Mix

The **urinary bladder**, trigone, and pelvic urethra are normal in thickness and the mucosal surface is smooth. The bladder lumen is moderately distended with anechoic urine. No masses, inflammatory changes or calculi are observed. The region of the trigone and the visible portion of the proximal urethra are normal.

### SEX

Spayed Female

The **left kidney** is normal in size (4.83 cm in length); with a normal shape and smooth peripheral contours. The cortex is mildly thickened and hyperechoic to slightly heterogenous in appearance with several small cortical cysts and a large (1.66 cm) cyst at the cranial aspect. Hyperechoic shadowing diverticular foci are visualized. There is no evidence of pyelectasia, infarcts or hydronephrosis.

### AGE

14.5 years

The **right kidney** is normal size (4.53 cm in length); with a normal shape and smooth peripheral contours. The cortex is mildly thickened and hyperechoic to slightly heterogenous in appearance with several small cortical cysts at the cranial aspect. Hyperechoic shadowing diverticular foci are visualized. There is no evidence of pyelectasia, infarcts or hydronephrosis.

### WEIGHT

17 lbs

### *Adrenal Glands*

The **left adrenal gland** is mildly enlarged (0.77 cm at cranial pole) (0.65 cm at caudal pole); (1.82 cm in length) with an irregular shape. There appears to be a 1.27 x 0.96 cm mildly heterogenous nodule at the cranial pole. The glandular echogenicity and detail at the caudal pole appear normal. The phrenicoabdominal vein and surrounding vasculature appear normal.

## INTERPRETED BY

Andrea Nicastro,  
DVM, Diplomate  
ACVIM (*Small Animal  
Internal Medicine*)

The **right adrenal gland** is mildly enlarged (0.97 cm at cranial pole) (0.71 cm at caudal pole); with a normal shape and smooth peripheral contours. The parenchyma is slightly heterogenous with some loss of glandular detail. The phrenicoabdominal vein and surrounding vasculature are normal.

## IMAGING PERFORMED BY

Christina Sitton

### *Spleen*

The **spleen** is normal in size (1.16 cm in width at the level of the hilus) with a normal capsular contour. There is appropriate echogenicity and echotexture. A few, small, ill-defined myelolipomas are observed in the region of the hilus. Splenic vasculature is normal.

## HOSPITAL NAME

Sherwood Family PC

### *Liver*

The **liver** is subjectively prominent to enlarged with swollen peripheral contours. The parenchyma is hypoechoic relative to the right renal cortex, and is diffusely heterogenous in appearance, with a few varying-sized, irregular, hyperechoic nodule throughout the organ. Hepatic vasculature and intrahepatic biliary tracts are of normal volume with no evidence of congestion.

## REFERRING VET

Dr. Christina Sitton

The **gall bladder** lumen is moderately distended. The wall is thin and smooth. A moderate amount of aggregated, echogenic, partially dependent to suspended sludge, with a few linear projections to the periphery, is observed within the lumen. The cystic and common bile ducts are normal/not seen.

## INVOICE

11186

## DATE

6.29.22

### ***Gastrointestinal***

The **gastric lumen** is not distended. The gastric wall is normal in thickness with a normal layering pattern. The small intestinal lumen is not dilated. The small intestinal wall thickness is normal with a normal layering pattern and appropriate mural detail. Discreet masses are not identified. The colonic wall is normal. There is no evidence of an obstructive pattern.

### ***Pancreas***

The region of the **pancreas** is isoechoic relative to surrounding omental fat. No obvious parenchymal abnormalities are observed. There is no evidence of regional inflammation or effusion.

### ***Free Abdomen***

The **peritoneal cavity** is normal. There is no evidence of inflammation or effusion. The abdominal **lymph nodes** are normal/not visible.

## **ULTRASONOGRAPHIC FINDINGS**

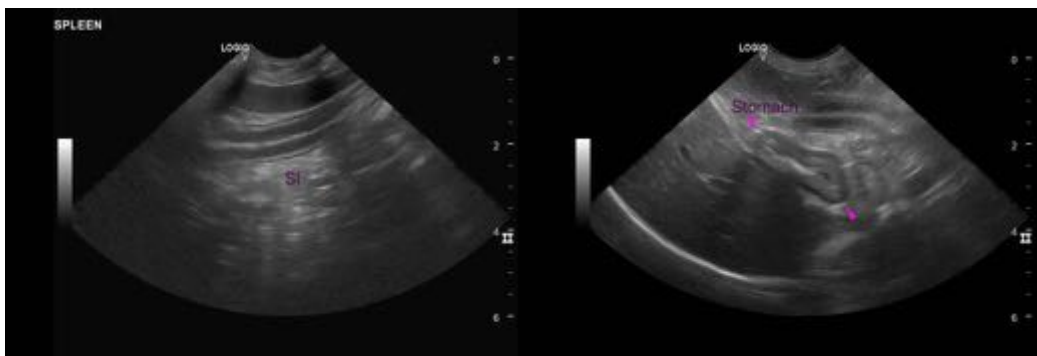
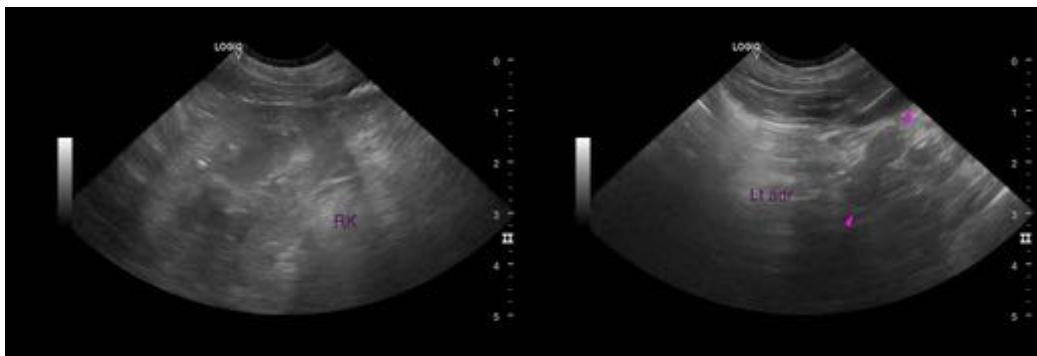
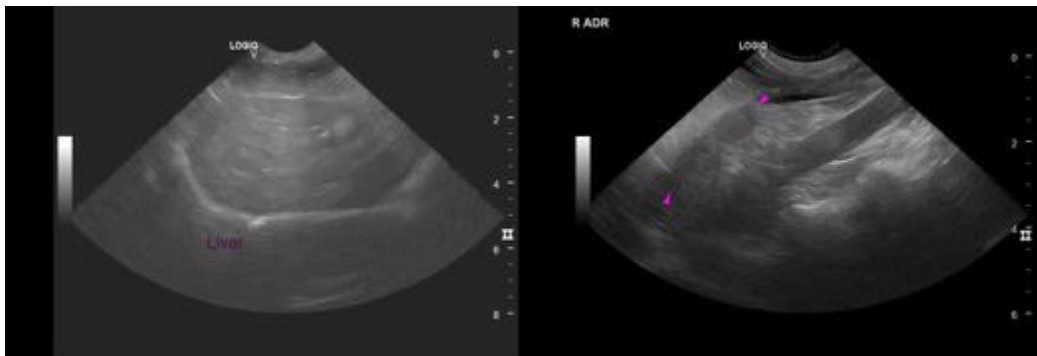
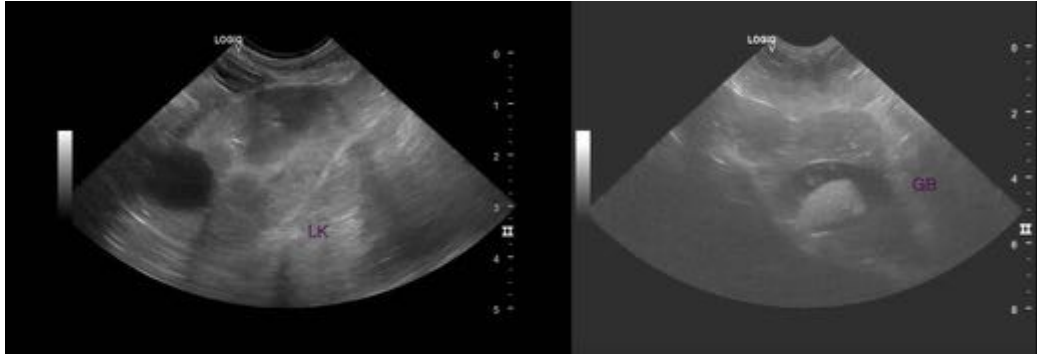
### **Primary Findings**

- Nonspecific diffuse hepatopathy. Top differentials include regenerative nodular hyperplasia, vacuolar hepatopathy, and/or age-related remodeling. Other hepatopathies cannot be completely excluded. Infiltrative neoplasia is possible but considered less likely.
- Mild bilateral adrenomegaly
- Bilateral chronic age-related renal changes with dystrophic mineralization and cortical cysts
- The gall bladder changes are suggestive of a developing mucocele.

## **INTERPRETATION OF THE FINDINGS & FURTHER RECOMMENDATIONS**

Given the clinical history, consider the following:

1. Urine culture and sensitivity to assess for occult pyelonephritis
2. Pre-and postprandial serum bile acids to assess hepatic function
3. +/- Leptospirosis testing (i.e., blood and urine PCR, serology)
4. Cushing's Testing (i.e., low-dose dexamethasone suppression test or ACTH stimulation test) can also be considered. However, Cushing's Disease should not result in inappetence. If Cushing's Disease is present, a concurrent problem is likely.
5. A malabsorption panel, including serum cobalamin and folate, TLI and PLI, can also be considered to assess for gastrointestinal and pancreatic disease as possible causes for inappetence.
6. Given the inappetence and history of a heart murmur, thoracic radiographs are recommended to assess cardiopulmonary status.
7. Regarding the gallbladder changes, consider initiation of Ursodiol with serial sonographic monitoring (i.e., every 6-8 weeks) to assess for progression to a fully-formed mucocele.



The information and recommendations provided are based on the images presented by the referring veterinarian/sonographer. No evaluation can be communicated regarding pathology that was not visible in the image/video clips provided.

Thank you for this referral. If the clinical or image interpretation does not parallel your findings or if I can be of any further assistance, please contact me.

**Andrea Nicastro**, DVM, Diplomate DACVIM (Small Animal Internal Medicine)  
info@SonoPath.com