



## PATIENT PRESENTING CLINICAL SIGNS

Dakota Bishop History: drank paint thinner 2 months ago (April). Elevated liver and renal values. On Denamarin and NexGuard  
 Abnormal PE/Chem/CBC/UA Results: glob 4.7, A/G ratio decr 0.6, ALT 240, crea 2.0, Amylase 1532; SDMA 12.8 wnl

## Canine ULTRASONOGRAPHIC EXAMINATION OF THE ABDOMEN

### BREED **Urinary System**

Lab Mix The **urinary bladder**, trigone, and pelvic urethra are normal in thickness and the mucosal surface is smooth. The bladder lumen is moderately distended with anechoic urine. No masses, inflammatory changes or calculi are observed. Ureteral papillae and visualized portion of the proximal urethra, visible to a depth of 2 cm, are normal.

### SEX

Spayed Female The **left kidney** is normal size (5.72 cm in length); with a slightly irregular shape. There is a normal 1:3 cortex to medulla ratio with moderate loss of corticomedullary distinction. There is a suspected infarct at the caudolateral aspect. Mild to moderate pyelectasia is present (0.39 cm in the longitudinal plane). There is no evidence of nephroliths or hydroureter. Renal vasculature is normal.

### AGE

8 years The **right kidney** is normal size (6.18 cm in length); normal shape and architecture with smooth peripheral margins. There is a normal 1:3 cortex to medulla ratio with mild to moderate loss of corticomedullary distinction. Hyperechoic shadowing diverticular foci are visualized. There is no evidence of pyelectasia, infarcts or hydroureter. Renal vasculature is normal.

### WEIGHT

53 lbs

### Adrenal Glands

The **left adrenal gland** is normal size (0.55 cm at cranial pole) (0.42 cm at caudal pole) (2.00 cm in length); normal shape; homogenous parenchyma. The glandular echogenicity and detail are unremarkable. Capsule, cortex, and medullary definition are normal. The phrenicoabdominal vein and surrounding vasculature are normal.

## INTERPRETED BY

Andrea Nicastro,  
DVM, Diplomate  
ACVIM (*Small Animal  
Internal Medicine*)

The **right adrenal gland** is mildly enlarged (1.71 cm at cranial pole) (0.94 cm at caudal pole) (2.36 cm in length); normal shape; homogenous parenchyma. The glandular echogenicity and detail are unremarkable. Capsule, cortex, and medullary definition are normal. The phrenicoabdominal vein and surrounding vasculature are normal.

## IMAGING PERFORMED BY

Diane McFadden

### Spleen

The **spleen** is normal in size (2.06 cm in width at the level of the hilus) with a normal capsular contour. There is appropriate echogenicity and echotexture. No focal lesions are observed. Splenic vasculature is normal.

## HOSPITAL NAME

AH of Roxbury

### Liver

The **liver** is subjectively normal in size with normal curvilinear peripheral contours. The parenchyma is slightly mottled in appearance. No distinct focal lesions are observed. Vascular and biliary tracts are of normal volume with no evidence of congestion

## REFERRING VET

Dr. Elia

The **gall bladder** is of normal contours and contains some dependent echogenic debris. The wall is normal in thickness. No choleliths are observed. The cystic and common bile ducts are normal/not seen.

## INVOICE **Gastrointestinal**

11184 The **gastric lumen** is not distended. The gastric wall is normal in thickness with a normal layering pattern. The small intestinal lumen is not dilated. The small intestinal wall thickness is normal with a normal

## DATE

6.29.22

layering pattern and appropriate mural detail. Discreet masses are not identified. The colonic wall is normal. There is no evidence of an obstructive pattern.

#### ***Pancreas***

The region of the **pancreas** is isoechoic relative to surrounding omental fat. No obvious parenchymal abnormalities are observed. There is no evidence of regional inflammation or effusion.

#### ***Free Abdomen***

The **peritoneal cavity** is normal. There is no evidence of inflammation or effusion. A 2.80 x 1.32 cm multiseptated cystic lymph nodes is observed just caudal to the left renal artery.

### **ULTRASONOGRAPHIC FINDINGS**

#### **Primary Findings**

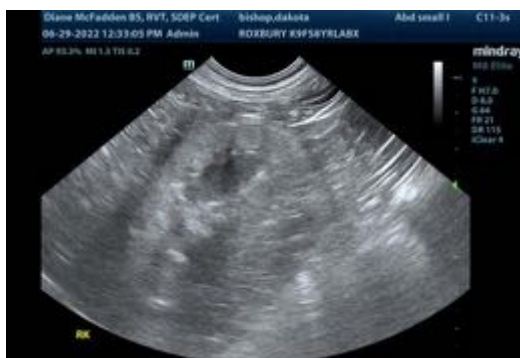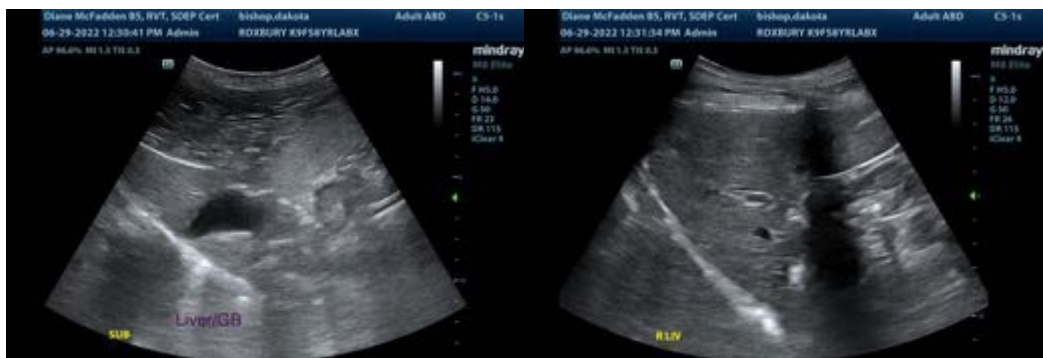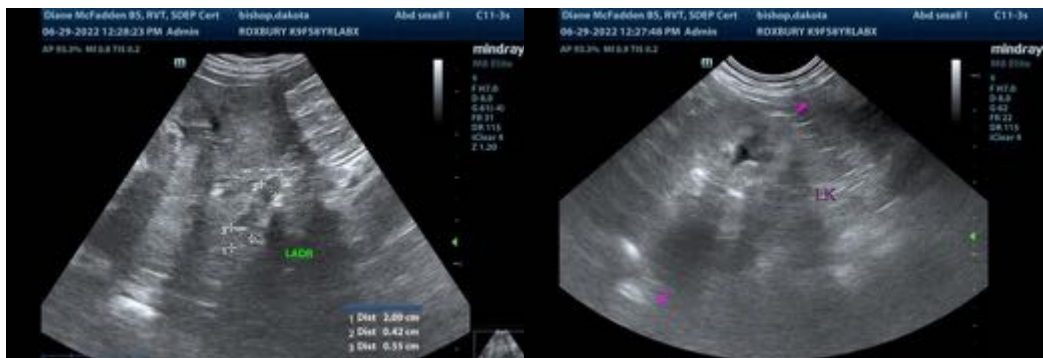
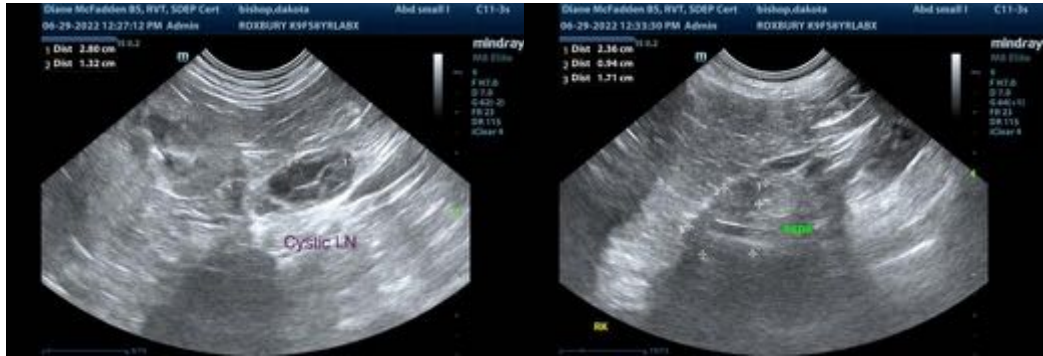- Bilateral chronic renal changes with left pyelectasia and a suspected cortical infarct
- The hepatic parenchymal changes are nonspecific and could be secondary to inflammatory disease (i.e., chronic active hepatitis, bacterial cholangiohepatitis), hepatotoxicosis, fibrosis, reactive hepatopathy, Leptospirosis, infiltrative neoplasia (less likely), other hepatopathy.

#### **Secondary Findings**

- The mild right adrenomegaly may be a normal variant for this patient or may represent early hyperplastic change. Emerging neoplasia is possible but considered less likely.
- The cystic lymph node in the left mid-abdomen is likely reactive with a lower possibility of emerging neoplasia.

### **INTERPRETATION OF THE FINDINGS & FURTHER RECOMMENDATIONS**

- Given the azotemia, consider a urine culture and sensitivity, UPC (if proteinuria is present) and baseline blood pressure measurement.
- A prescription renal diet should also be considered.
- With regard to the elevated ALT, hepatic tissue sampling (fine-needle aspirate or surgical biopsy) would be necessary to get a definitive diagnosis. Surgical biopsies are preferred in that they are more likely to be represent of underlying hepatic pathology. If pursued, aerobic and anaerobic bile cultures as well as acquisition of additional hepatic tissue samples for potential copper quantitation are recommended. Thoracic radiographs are recommended prior to any anesthetic event.



The information and recommendations provided are based on the images presented by the referring veterinarian/sonographer. No evaluation can be communicated regarding pathology that was not visible in the image/video clips provided.

Thank you for this referral. If the clinical or image interpretation does not parallel your findings or if I can be of any further assistance, please contact me.

**Andrea Nicastro**, DVM, Diplomate DACVIM (Small Animal Internal Medicine)  
info@SonoPath.com