



PATIENT	PRESENTING CLINICAL SIGNS
Freyja McAllister	History: mild azotemia noted on two serial bloodwork samples. Pet is asymptomatic- BUN 28 and 38, Crea 1.5 and 1.8, ALP 732 and 608. UA had 1 + protein and urine SG 1.025. UPC < 0.2
SPECIES	ULTRASONOGRAPHIC EXAMINATION OF THE ABDOMEN
Canine	Urinary System The urinary bladder wall is normal in thickness and the mucosal surface is smooth. The bladder is moderately distended. A small amount of suspended echogenic debris is observed within the lumen. No cystic calculi are observed. The region of the trigone and the proximal urethra, visible to a depth of 1-2 cm, are normal.
BREED	
Bernese Mix	
SEX	
Spayed Female	The left kidney is normal in size (5.49 cm in length) with a normal shape, architecture, and smooth peripheral margins. There is a normal 1:3 cortex to medulla ratio with normal corticomedullary distinction. A hyperechoic medullary band is observed at the corticomedullary junction. There is no evidence of pyelectasia, nephroliths, infarcts or hydroureter. Renal vasculature is normal.
AGE	
4 years	The right kidney is normal in size (6.48 cm in length) with a normal shape, architecture, and smooth peripheral margins. There is a normal 1:3 cortex to medulla ratio with normal corticomedullary distinction. A hyperechoic medullary band is observed at the corticomedullary junction. There is no evidence of pyelectasia, nephroliths, infarcts or hydroureter. Renal vasculature is normal.
WEIGHT	Adrenal Glands The left adrenal gland is normal in size (0.43 cm at cranial pole) (0.54 cm at caudal pole) with a normal shape and homogenous parenchyma. The glandular echogenicity and detail are unremarkable. Capsule, cortex, and medullary definition are normal. The phrenicoabdominal vein and surrounding vasculature are normal.
48 lbs	
INTERPRETED BY	
Andrea Nicastro, DVM, Diplomate ACVIM (Small Animal Internal Medicine)	The right adrenal gland is normal in size (0.62 cm at cranial pole) (0.47 cm at caudal pole) with a normal shape and homogenous parenchyma. The glandular echogenicity and detail are unremarkable. Capsule, cortex, and medullary definition are normal. The phrenicoabdominal vein and surrounding vasculature are normal.
IMAGING PERFORMED BY	Spleen The spleen is normal in size (1.59 cm in width at the level of the hilus) with a normal capsular contour. There is appropriate echogenicity and echotexture. No focal lesions are observed. Splenic vasculature appears normal.
Dr. Sheldon	
HOSPITAL NAME	Liver The liver is subjectively normal in size with normal contours and structure. There is appropriate echogenicity and echotexture. No overt structural evidence of inflammatory, infiltrative, or regenerative pathology is evident. Vascular and biliary tracts are of normal volume with no evidence of congestion. No pathological hepatic lymphadenopathy observed.
Advanced PetCare of Oakland	
REFERRING VET	The gall bladder is of normal contours and contains some dependent echogenic debris. The wall is normal in thickness. No choleliths are observed. The cystic and common bile ducts are normal/not seen.
Dr. Sheldon	
INVOICE	Gastrointestinal The lumen is not distended. The gastric wall is normal in thickness with a normal layering pattern. The small intestinal lumen is not dilated. The small intestinal wall thickness is normal with a normal layering pattern and appropriate mural detail. Discreet masses are not identified. The colonic wall is normal. There is no evidence of an obstructive pattern.
13469	
DATE	
6.23.23	



PATIENT

Freyja McAllister

Pancreas

The pancreas is normal in size with normal peripheral contours. The pancreatic duct is normal. The base and limbs of the pancreas are isoechoic to surrounding omental fat. No focal lesions are observed. There is no evidence of peripancreatic inflammation or effusion.

SPECIES

Canine

Free Abdomen

The peritoneal cavity is normal. There is no evidence of inflammation or effusion. The abdominal lymph nodes are normal/not visible.

BREED

Bernese Mix

ULTRASONOGRAPHIC FINDINGS

Findings

- The medullary band seen in both kidneys may be a normal variant for this patient or may be secondary to renal disease.

SEX

Spayed Female

*An obvious cause for the patient's azotemia and elevated liver values is not definitively identified in this study. Considerations include infectious disease (i.e., Leptospirosis), toxicity, other.

AGE

4 years

INTERPRETATION OF THE FINDINGS & FURTHER RECOMMENDATIONS

Regarding the azotemia, consider the following:

- Leptospirosis testing (i.e., blood and urine PCR, serology) is recommended.
- A resting cortisol level to screen for hypoadrenocorticism. If resting cortisol level is < 2.0 mcg/dL, an ACTH stimulation test is recommended.
- A urine culture and sensitivity should be considered to assess for occult pyelonephritis.
- A baseline blood pressure measurement should also be considered.

WEIGHT

48 lbs

Regarding the elevated liver values, consider the following:

- Consider pre-and postprandial serum bile acids to evaluate hepatic function.
- Leptospirosis testing (as mentioned above)
- +/- hepatic tissue sampling (i.e., fine-needle aspirate or biopsies) may be warranted.

INTERPRETED BY

Andrea Nicastro,
DVM, Diplomate
ACVIM (Small Animal
Internal Medicine)

**IMAGING
PERFORMED BY**

Dr. Sheldon

HOSPITAL NAME

Advanced PetCare
of Oakland

REFERRING VET

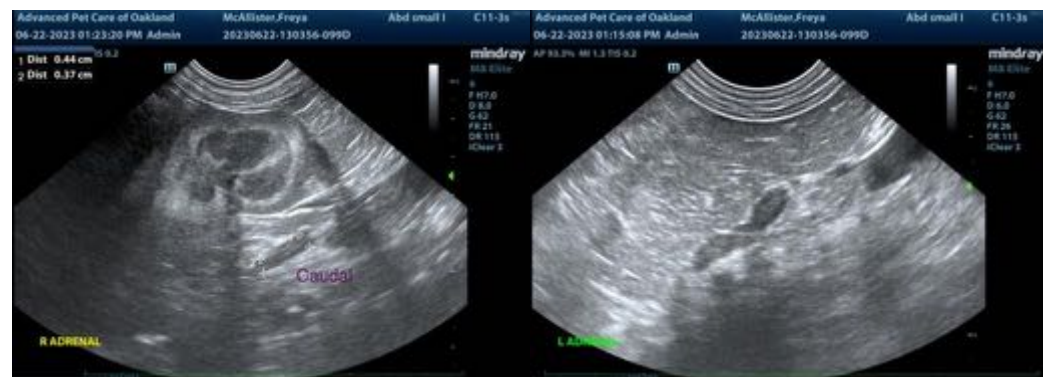Dr. Sheldon

INVOICE

13469

DATE

6.23.23





PATIENT

Freyja McAllister

SPECIES

Canine

BREED

Bernese Mix

SEX

Spayed Female

AGE

4 years

WEIGHT

48 lbs

INTERPRETED BY

Andrea Nicastro,
DVM, Diplomate
ACVIM (Small Animal
Internal Medicine)

**IMAGING
PERFORMED BY**

Dr. Sheldon

HOSPITAL NAME

Advanced PetCare
of Oakland

REFERRING VET

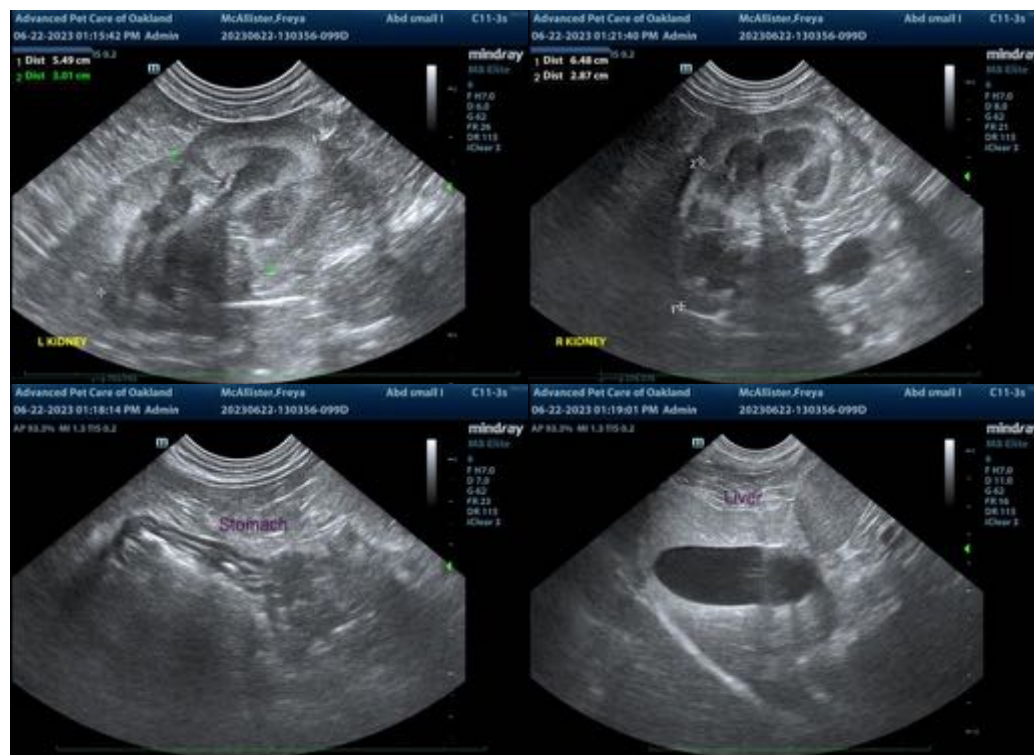
Dr. Sheldon

INVOICE

13469

DATE

6.23.23



The information and recommendations provided are based on the images presented by the referring veterinarian/sonographer. No evaluation can be communicated regarding pathology that was not visible in the image/video clips provided.

Thank you for this referral. If the clinical or image interpretation does not parallel your findings or if I can be of any further assistance, please contact me.

Andrea Nicastro, MPH, DVM, Diplomate DACVIM (Small Animal Internal Medicine)
info@SonoPath.com