



PATIENT PRESENTING CLINICAL SIGNS

Mark Aragon

History: presented on 6/21 for v/d today. 1 year ago seen for chronic diarrhea - low protein - prescribed I/D - got worse, prescribed hydrolyzed protein and diarrhea stopped but had a lot of flatulence. O switched to plain chicken on 6/8 and he got better Recheck Jan w/BW and AUS - normal. at the time skin issues occurring 1 month ago diagnosed w/Cushing 6/9 started on vetoryl 20mg PO SID need to call clinic in Cali for records 6/17 ate some cat vomit, 6/18 diarrhea, 6/20 vomiting, 6/21 hyporexia

SPECIES

Canine

BREED

Yorkshire Terrier

SEX

Neutered Male

AGE

11 years

WEIGHT

8.5 lbs

INTERPRETED BY

Andrea Nicastro,
DVM, Diplomate
ACVIM (*Small Animal
Internal Medicine*)

IMAGING PERFORMED BY

Dr. Emi Menzen

HOSPITAL NAME

Wilvet Salem

REFERRING VET

Dr. Emi Menzen

INVOICE

11145

DATE

6/22/22

Abnormal PE/Chem/CBC/UA Results: PE - painful, murmur, cushingoid, diarrhea, dehydrated
Lab/trends: CBC: Hct 52%, WBC 10.56, Monocytes 1.37 (H), Plt 463 Chem17: TP 5.3, ALB 2.2, glob 3.1
EPOC: Na 146, K 4, Cl 113, Ca 1.17 UA: WBC 5/hpf (red rubber), RBC > 50/hpf (red rubber), no ketones on dipstick recheck, no bacteria, USG pending UMIC pending cPLI: 85 - normal Three view thoracic radiographs with STAT send out: FINDINGS: Moderate generalized broncho-interstitial infiltrate is present. The caudal border of the heart is mildly straightened on the left lateral view. The cardiac silhouette is elongated. The caudal vena cava and the pulmonary vasculature are normal. The principal bronchi are normal in position. The tracheal diameter is normal. No esophageal dilation is present. The pleural space, the mediastinum and diaphragm are normal. No tracheobronchial or other intrathoracic lymph node enlargement is present. Smoothly marginated callus production is present In the bodies of the left third, fourth, fifth, sixth and ninth ribs. Additional callus production appears to be present within the spinous processes of T4 and T5. A microchip is present in the soft tissues dorsal to the scapulae. The liver is enlarged and normal in shape. Adequate serosal margin detail is seen in the cranial abdomen.

CONCLUSIONS: 1. Mild left heart enlargement, most consistent with valvular insufficiency and no current evidence of cardiac decompensation. 2. Healed rib and thoracic spinous process fractures, associated with prior trauma or underlying metabolic disease. 3. Generalized hepatomegaly. Differentials include diabetes, steroid hepatopathy, congestion, inflammation, fatty infiltration, vacuolar hepatopathy and neoplasia.

RECOMMENDATIONS: Ultrasound examination of the abdomen is recommended for further evaluation of the liver architecture and to screen for the causes of abdominal pain.

ULTRASONOGRAPHIC EXAMINATION OF THE ABDOMEN

Urinary System

The urinary bladder, trigone, and pelvic urethra are normal in thickness and the mucosal surface is smooth. The bladder lumen is moderately distended with mostly anechoic urine. No masses, inflammatory changes or calculi are observed. Ureteral papillae and visualized portion of the proximal urethra, visible to a depth of 2 cm, are normal.

The prostate is normal in size (0.91 cm in width) and shape. Parenchyma is homogenous. The prostatic urethra appears normal without evidence of dilation or obstruction.

The left kidney is normal size (4.53 cm in length); normal shape and architecture with smooth peripheral margins. There is a normal 1:3 cortex to medulla ratio with minimal to mild loss of corticomedullary distinction. There is no evidence of pyelectasia, nephroliths, infarcts or hydronephrosis. Renal vasculature is normal.

The right kidney is normal size (5.50 cm in length); normal shape and architecture with smooth peripheral margins. There is a normal 1:3 cortex to medulla ratio with mild to moderate loss of corticomedullary distinction. There is no evidence of pyelectasia, nephroliths, infarcts or hydronephrosis. Renal vasculature is normal.

Adrenal Glands

The left adrenal gland is enlarged (0.85 cm at cranial pole) (0.69 cm at caudal pole); normal shape; homogenous parenchyma. The glandular echogenicity and detail are unremarkable. Capsule, cortex, and medullary definition are normal. The phrenicoabdominal vein and surrounding vasculature are normal.

The right adrenal gland is enlarged (0.77 cm at cranial pole) (0.84 cm at caudal pole); with a slightly irregular shape. The parenchyma is subtly heterogenous with some loss of glandular detail. The phrenicoabdominal vein and surrounding vasculature are normal.

Spleen

The spleen is normal in size (1.16 cm in width at the level of the hilus) with a normal capsular contour. There is appropriate echogenicity and echotexture. No focal lesions are observed. Splenic vasculature is normal.

Liver

The liver is subjectively enlarged with swollen peripheral contours. The parenchyma is isoechoic relative to the spleen and subtly heterogenous in appearance, with a few, ill-defined, hyperechoic nodules/areas throughout the organ. Hepatic vasculature and intrahepatic biliary tracts are of normal volume with no evidence of congestion. The portal vein to caudal vena cava ratio is approximately 1: 1.

The gall bladder lumen is mildly to moderately distended. The wall is thickened (up to 0.31 cm), irregular, and hyperechoic. A moderate to large amount of aggregated, echogenic to mineralized, suspended sludge, in a partially stellate pattern is observed within the lumen. The cystic and common bile ducts are normal/not seen.

Gastrointestinal

The gastric lumen is mildly fluid distended. The gastric wall is subjectively thickened, although the wall thickness is difficult to measure due to excessive rugal folds. There is questionable retention of the normal layering pattern. The pyloric outflow tract is patent. The small intestinal lumen is not dilated. The small intestinal wall is normal to mildly thickened (up to 0.41 cm) with a normal layering pattern. There is evidence of mucosal speckling and striations several segments. Discreet masses are not identified. The colonic wall is normal. The lumen of the descending colon contains a moderate to large amount of liquid-appearing fecal material. There is no obvious evidence of an obstructive pattern.

Pancreas

The base and right limb of the pancreas are visible with normal curvilinear peripheral contours. The parenchyma is largely isoechoic relative to surrounding omental fat and slightly mottled in appearance. The pancreatic duct is visible but not overtly dilated. There is no evidence of peripancreatic inflammation or effusion.

Free Abdomen

Portions of the mesentery in the cranial to midabdominal are mildly hyperechoic. There is questionable trace ascites. The abdominal lymph nodes are normal/not visible.

ULTRASONOGRAPHIC FINDINGS

Primary Findings

- The clinical history, in conjunction with the sonographic intestinal changes are concerning for a protein-losing enteropathy. Differentials include lymphangiectasia, inflammatory bowel disease, infectious/parasitic, emerging neoplasia (less likely), other.
- The gastric wall changes could be consistent with inflammatory, hypertrophy or emerging neoplasia'
- The gall bladder wall changes are consistent with cholecystitis. The luminal sludge is concerning for a developing mucocele.
- Mild peritonitis, likely secondary to bowel pathology.

Secondary Findings

- Minor, bilateral, age-related renal changes
- The bilateral adrenomegaly is consistent with the previous diagnostics of pituitary-dependent hyperadrenocorticism.
- The diffuse hepatic changes are non-specific and could be consistent with vacuolar hepatopathy, regenerative nodular hyperplasia, and/or age-related remodeling. Inflammatory and infiltrative disease are considered less likely.
- The pancreatic changes are most consistent with age-related parenchymal remodeling, potentially secondary to a prior inflammatory episode, early fibrosis or chronic pancreatitis.

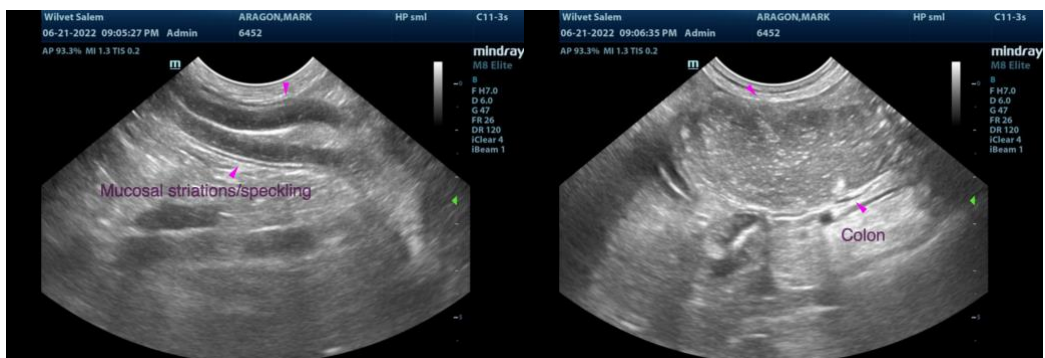
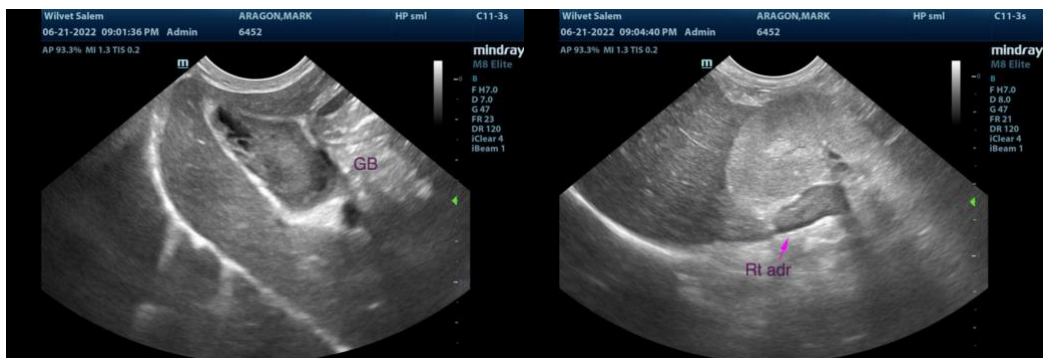
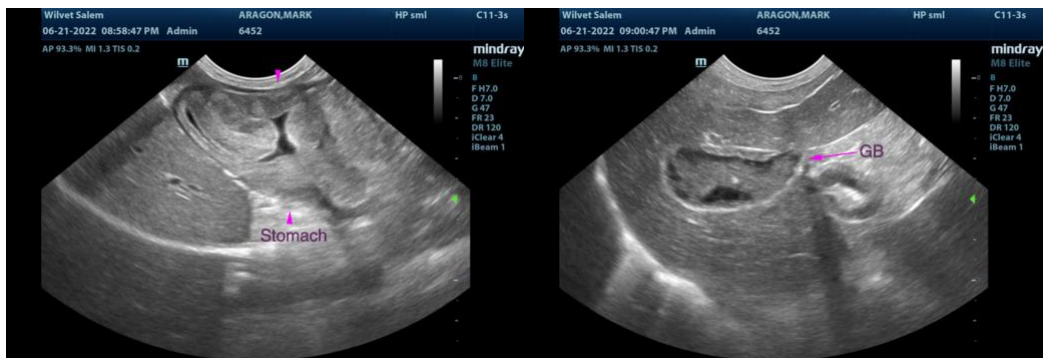
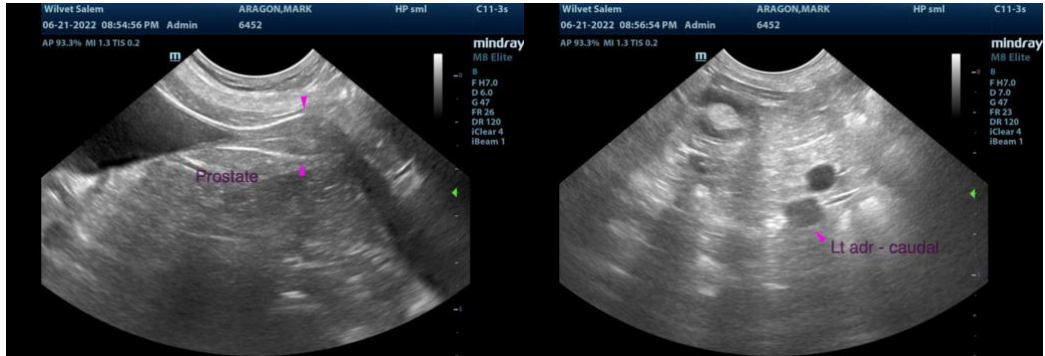
INTERPRETATION OF THE FINDINGS & FURTHER RECOMMENDATIONS

In order to get a definitive diagnosis, gastrointestinal biopsies (i.e., endoscopic or surgical) would be necessary. Surgical biopsies are preferred in that all areas of bowel can be accessed. If surgery is pursued, the gall bladder should be assessed +/- removed, due to the potential for a developing mucocele. Referral to a board-certified surgeon is recommended due to the potential for perioperative complications associated with cholecystectomy.

Other diagnostics considerations include the following:

1. Fecal evaluation for ova and Giardia (if not already performed)
2. Malabsorption panel, including serum cobalamin and folate, TLI and PLI
3. Pre-and postprandial serum bile acids to rule out hepatic dysfunction as a possible concurrent cause of hypoalbuminemia.
4. Consider a UPC if proteinuria is present (to assess for renal protein loss).

While awaiting test results, symptomatic care is recommended along with initiation of a probiotic with a high colony count (i.e., Provable Forte or Visbiome). Also consider initiation of ursodiol therapy when the patient is no longer vomiting.



The information and recommendations provided are based on the images presented by the referring veterinarian/sonographer. No evaluation can be communicated regarding pathology that was not visible in the image/video clips provided.

Thank you for this referral. If the clinical or image interpretation does not parallel your findings or if I can be of any further assistance, please contact me.

Andrea Nicastro, DVM, Diplomate DACVIM (Small Animal Internal Medicine)
info@SonoPath.com