

**DATE PRESENTING CLINICAL SIGNS**

6.21.2023 Rocky presented for weight loss. He has a history of chronic renal disease (IRIS stage 2/4, managed with diet), hypertrophic cardiomyopathy, and hyperthyroidism. CV: No arrhythmias, grade 2/6 holosystolic murmur-sternal; strong, synchronous femoral pulses

**PATIENT**

Rocky Heller Current Medications: Methimazole 4mg BID (transdermal), Atenolol 12.5mg SID, Aspirin 20mg twice weekly

**SPECIES**

Feline

Lab Results: ALT, ALP, GGT, and TBILI are all elevated. SDSMA 20. Globulin 6. ALT 471. ALP 143. GGT 14. tBili 0.90. UPC 0.3. BNP 430. USG 1.014, inactive sediment. Trace proteinuria. Elevated T4 (11.2).

Date of Previous IntraPet Ultrasound: No previous.

Sedation: Not required to complete full diagnostic ultrasound.

Stat Report: Not requested.

**BREED**

Imaging Performed By: Rachel Brillhart, RDMS.

DSH

**SEX**

Neutered Male

**ULTRASONOGRAPHIC EXAMINATION OF THE ABDOMEN****Urinary System**

The urinary bladder wall is normal in thickness and the mucosal surface is smooth. The bladder is moderately distended. Luminal contents are anechoic. No cystic calculi are observed. The region of the trigone is normal.

**AGE**

1/1/2004

The left kidney is normal in size (4.02 cm in length) with a normal shape, architecture and smooth peripheral margins. The cortex is hyperechoic. There is a normal 1:3 cortex to medulla ratio with poor corticomedullary distinction. There is no evidence of pyelectasia, nephroliths, infarcts or hydronephrosis. Renal vasculature is normal.

**WEIGHT**

7 lbs

The right kidney is normal in size (3.96 cm in length) with a normal shape, architecture and smooth peripheral margins. The cortex is hyperechoic. There is a normal 1:3 cortex to medulla ratio with poor corticomedullary distinction. There is no evidence of pyelectasia, nephroliths, infarcts or hydronephrosis. Renal vasculature is normal.

**INTERPRETED BY**

Andrea Nicastro,  
DMV, Diplomate  
DACVIM (Small  
Animal  
Internal Medicine)

**Adrenal Glands**

The left adrenal gland is normal in size (0.49 cm width). Normal shape and glandular echogenicity. The phrenicoabdominal vein and surrounding vasculature are normal.

**HOSPITAL NAME**

Mt. Airy Vet Assoc

The right adrenal gland is normal in size (0.42 cm width). Normal shape and glandular echogenicity. The phrenicoabdominal vein and surrounding vasculature are normal.

**REFERRING VET**

Dr. Cormier

**Spleen**

The spleen is normal in size (0.76 cm in width at the level of the hilus) with a normal capsular contour. There is appropriate echogenicity and echotexture. No focal lesions are observed. Splenic vasculature is normal.

**INVOICE**

13437

**Liver**

The liver is normal to slightly prominent in size, with subtly irregular peripheral contours. The parenchyma is isoechoic-to-hyperechoic relative to the spleen. Two hyperechoic-to-heterogenous multiseptated cystic nodules are observed on the left side (one measuring 1.53 cm in diameter / the other measuring 1.26 cm in diameter). Hepatic vasculature and intrahepatic biliary tracts are of normal volume with no evidence of congestion.

The gall bladder is moderately distended. The wall is normal in thickness. A small amount of echogenic debris is suspended within the lumen. The cystic and common bile ducts are visible/tortuous but not overtly dilated.

### ***Gastrointestinal***

The stomach and intestine are free of stasis and exhibit normal peristaltic activity. The gastric lumen is not distended. The gastric wall and pylorus are normal in thickness with a normal layering pattern. The pyloric outflow tract is patent. The small intestinal lumen is not dilated. The small intestinal wall is normal in thickness with a normal layering pattern and appropriate mural detail. Discreet masses are not identified. The ileocecolic junction and colonic wall are normal. There is no evidence of an obstructive pattern.

### ***Pancreas***

The left limb of the pancreas is visible with normal curvilinear peripheral contours. The parenchyma is largely hypoechoic relative to surrounding omental fat and slightly mottled in appearance. The pancreatic duct is visible but not overtly dilated. There is no evidence of peripancreatic inflammation or effusion.

### ***Free Abdomen***

There is no obvious evidence of free fluid. The abdominal lymph nodes are normal/not visible.

## **ULTRASONOGRAPHIC FINDINGS**

### **Primary Findings**

- The cystic hepatic nodules are most consistent with biliary cystadenomas with a lower possibility of biliary cystadenocarcinomas.
- The diffuse hepatic parenchymal changes are nonspecific and may be secondary to hepatic lipidosis, inflammatory disease (i.e., bacterial cholangiohepatitis, lymphoplasmacytic hepatitis, feline infectious peritonitis), emerging lymphoma, or other hepatopathy.

### **Secondary Findings**

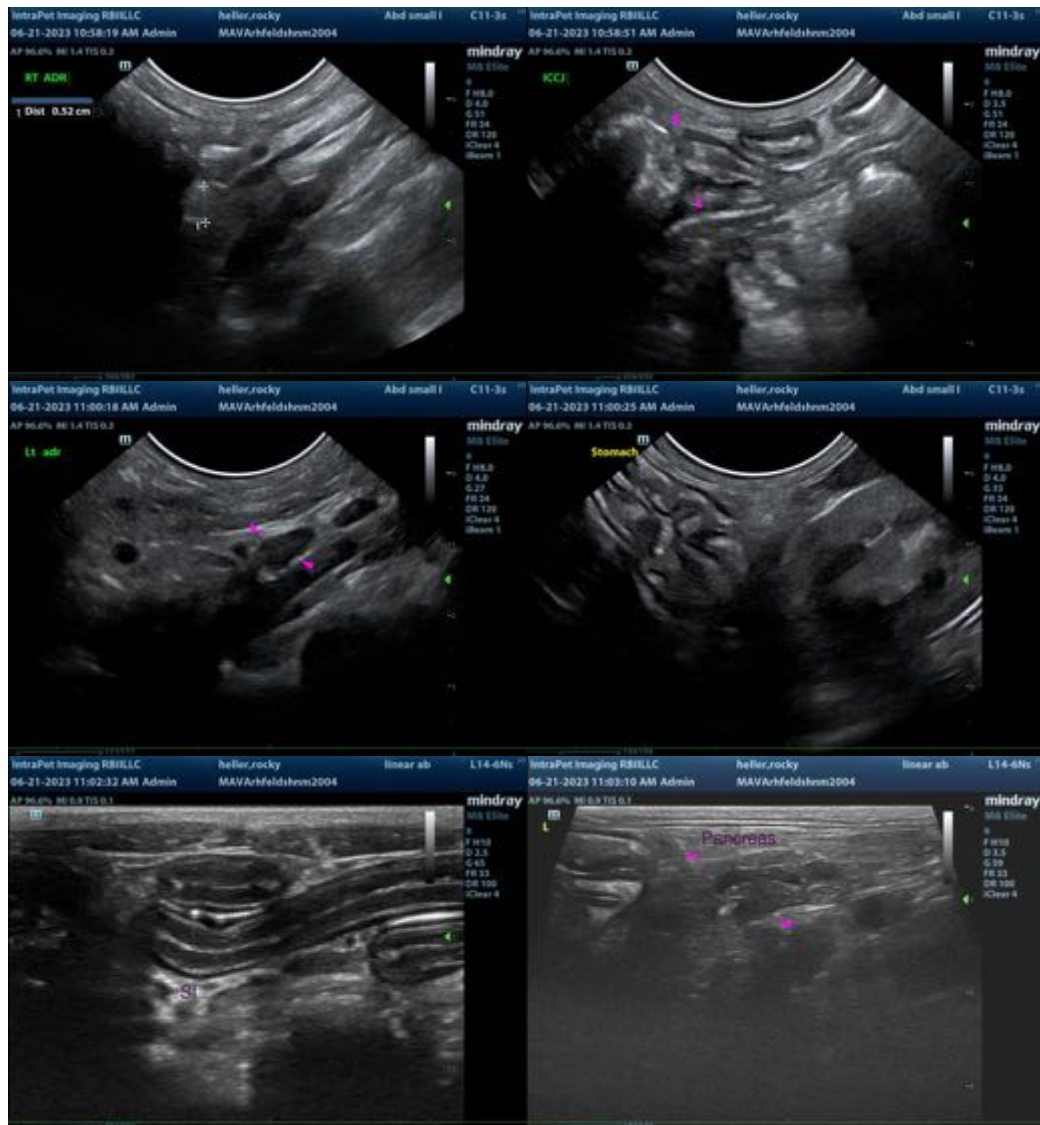
- Bilateral chronic nonspecific age-related renal changes
- The pancreatic changes are most consistent with age-related parenchymal remodeling, potentially secondary to a prior inflammatory episode, early fibrosis or chronic pancreatitis.

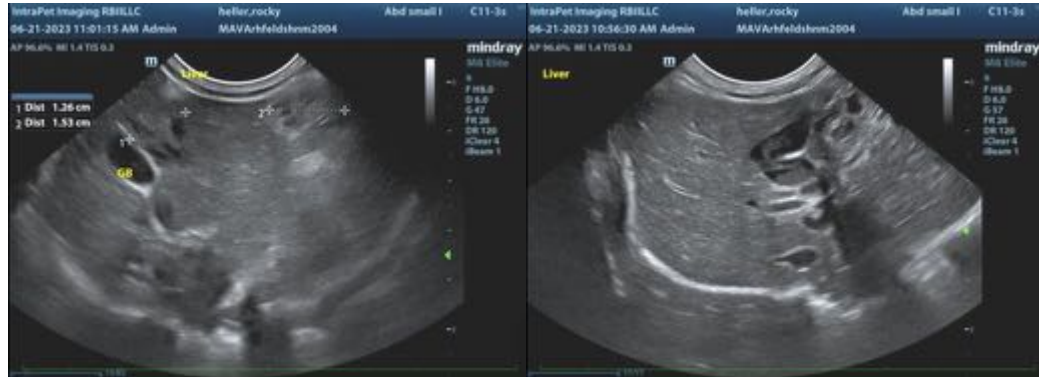
## **INTERPRETATION OF THE FINDINGS & FURTHER RECOMMENDATIONS**

- Given the history of weight loss, three-view thoracic radiographs are recommended to assess for occult disease in the chest.
- Regarding the elevated liver enzymes, consider ultrasound-guided fine-needle aspirates of the liver (if clotting status is appropriate). Twenty-five gauge-needles should be used for the procedure.
- Other diagnostic considerations include the following:
  1. Fecal evaluation for internal parasites

2. Texas GI panel including serum cobalamin and folate, TLI and PLI, to evaluate for concurrent small intestinal and pancreatic disease.

- Given the elevated T4, adjustment in the methimazole dose may be warranted.





The information and recommendations provided are based on the images presented by the referring veterinarian/sonographer. No evaluation can be communicated regarding pathology that was not visible in the image/video clips provided.

Thank you for this referral. If the clinical or image interpretation does not parallel your findings or if I can be of any further assistance, please contact me.

**Andrea Nicastro, MPH, DVM, Diplomate DACVIM (Small Animal Internal Medicine)**  
[info@SonoPath.com](mailto:info@SonoPath.com)