

**DATE PRESENTING CLINICAL SIGNS**

6.20.2022

Chronic diarrhea, intermittent hyporexia, recurrent aspiration pneumonia (suspect secondary to silent regurgitation/reflux). Polydipsic and questionably polyuric.

PATIENT

Kelsier Moriarty

Current Medications: Omeprazole 20mg BID, Metoclopramide 10mg BID (temporarily discontinued).
 Metronidazole 250mg BID. Trazodone 100mg PRN.

Lab Results: Normal ACTH stim (no Addison's). Other labs unremarkable except ALP 359.

Date of Previous IntraPet Ultrasound:

Sedation: Patient sedated with Torbugesic.

Stat Report: Not requested.

SPECIES

Canine

BREED

Australian Shepherd

Imaging Performed By: Andi Parkinson, BS, RDMS.

ULTRASONOGRAPHIC EXAMINATION OF THE ABDOMEN**SEX**

Neutered Male

Urinary System

The urinary bladder, trigone, and pelvic urethra are normal in thickness and the mucosal surface is smooth. The bladder lumen is moderately distended with anechoic urine. No masses, inflammatory changes or calculi are observed. Ureteral papillae and visualized portion of the proximal urethra, visible to a depth of 2 cm, are normal.

AGE

23.4kg

The prostate is normal in size (1.40 cm in width) with a normal shape and smooth peripheral contours. The parenchyma is subtly heterogenous. No distinct focal lesions are observed. The prostatic urethra urethra is not overtly dilated.

WEIGHT

12/24/2020

The left kidney is normal size (6.05 cm in length); normal shape and architecture with smooth peripheral margins. There is a normal 1:3 cortex to medulla ratio with normal corticomedullary distinction. There is no evidence of pyelectasia, nephroliths, infarcts or hydroureter. Renal vasculature is normal.

INTERPRETED BY

Andrea Nicastro, DMV,
 Diplomate DACVIM
 (Small Animal
 Internal Medicine)

The right kidney is normal size (5.77 cm in length); normal shape and architecture with smooth peripheral margins. There is a normal 1:3 cortex to medulla ratio with normal corticomedullary distinction. There is no evidence of pyelectasia, nephroliths, infarcts or hydroureter.

HOSPITAL NAME

Nexus Vet Specialists

Adrenal Glands

The left adrenal gland is normal size (0.57 cm at cranial pole) (0.49 cm at caudal pole) (2.45 cm in length); normal shape; homogenous parenchyma. The glandular echogenicity and detail are unremarkable. Capsule, cortex, and medullary definition are normal. The phrenicoabdominal vein and surrounding vasculature are normal.

REFERRING VET

Dr. Steele

The right adrenal gland is normal size (0.51 cm at cranial pole) (0.53 cm at caudal pole) (1.82 cm in length); normal shape; homogenous parenchyma. The glandular echogenicity and detail are unremarkable. Capsule, cortex, and medullary definition are normal. The phrenicoabdominal vein and surrounding vasculature are normal.

INVOICE

11123

Spleen

The spleen is normal in size (1.74 cm in width at the level of the hilus) with a normal capsular contour. There is appropriate echogenicity and echotexture. No focal lesions are observed. Splenic vasculature is normal.

Liver

The liver is subjectively normal in size with normal contours and structure. There is appropriate echogenicity and echotexture. No overt structural evidence of inflammatory, infiltrative, or regenerative pathology is evident. Vascular and biliary tracts are of normal volume with no evidence of congestion. No pathological hepatic lymphadenopathy observed.

The gall bladder lumen is moderately distended. The wall is thin and smooth. Luminal contents are anechoic. The cystic and common bile ducts are normal/not seen.

Gastrointestinal

The gastric lumen is gas distended. The gastric wall is normal in thickness with a normal layering pattern. The small intestinal lumen is not dilated. The small intestinal wall thickness is normal with a normal layering pattern and appropriate mural detail. Discreet masses are not identified. The colonic wall is normal. There is no evidence of an obstructive pattern.

Pancreas

The pancreas is visualized, +/- prominent, with normal curvilinear peripheral contours. The parenchyma is subtly hypoechoic relative to surrounding omental fat. No distinct focal lesions are observed. The pancreatic duct is not overtly dilated.

Free Abdomen

The peritoneal cavity is normal. There is no evidence of inflammation or effusion. A few prominent, mesenteric lymph nodes are visualized, the largest measuring 2.47 cm in length. In addition, a 1.20 cm sublumbar lymph node is seen. All of the lymph nodes are normal in shape and echogenicity.

Other

A brief echocardiogram reveals no evidence of pericardial effusion or obvious right atrial/auricular mass.

ULTRASONOGRAPHIC FINDINGS

Primary Findings

- The prominent abdominal lymph nodes are most consistent with reactive lymphadenitis or lymphoid hyperplasia. Neoplastic infiltration is considered less likely.

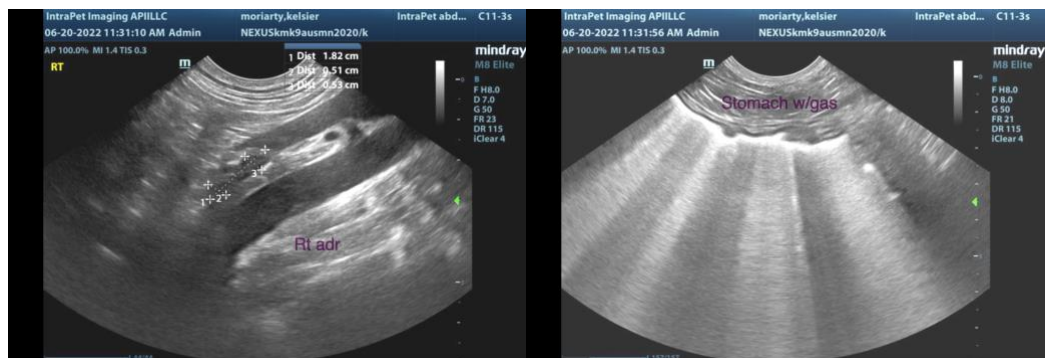
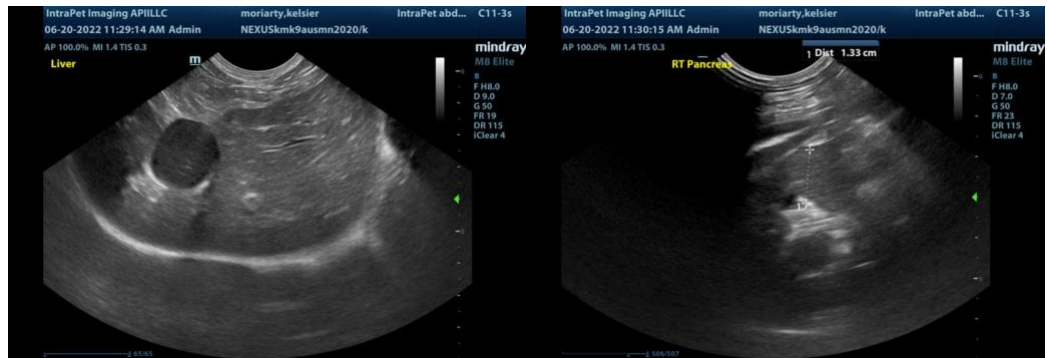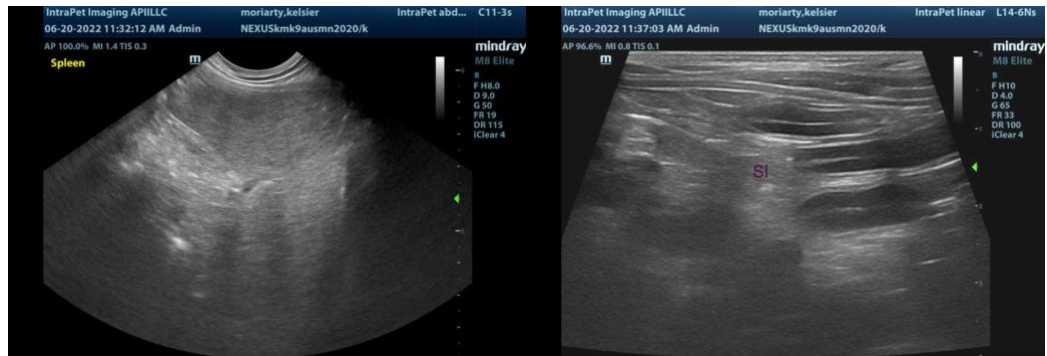
Secondary Findings

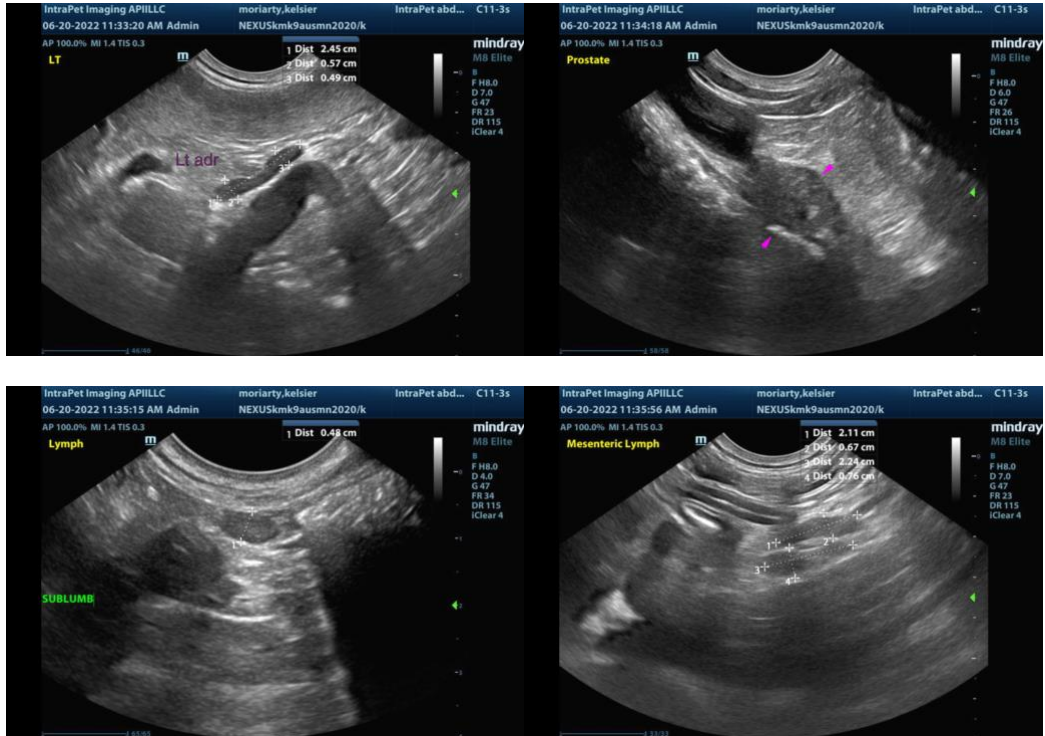
- The mild prostatic parenchymal heterogeneity is likely a normal variant for this patient. Although mild hyperplastic change cannot be completely excluded.
- The pancreatic changes may be a normal variant for this patient or could be consistent with mild, chronic pancreatitis. Correlation with clinical findings is recommended.

*An obvious cause for the patient's clinical signs is not identified in this study. Considerations include microscopic gastrointestinal disease (i.e., inflammatory bowel disease, infectious/parasitic disease, intestinal dysbiosis, food allergy/intolerance), low-grade pancreatitis, underlying metabolic issue, other.

INTERPRETATION OF THE FINDINGS & FURTHER RECOMMENDATIONS

Further diagnostics and treatment recommendations are to be implemented by Dr. Cara Steele.





The information and recommendations provided are based on the images presented by the referring veterinarian/sonographer. No evaluation can be communicated regarding pathology that was not visible in the image/video clips provided.

Thank you for this referral. If the clinical or image interpretation does not parallel your findings or if I can be of any further assistance, please contact me.

Andrea Nicastro, DVM, Diplomate DACVIM (Small Animal Internal Medicine)
info@SonoPath.com