


**PATIENT PRESENTING CLINICAL SIGNS**

Lexi Vincintore History: Presented for vomiting intermittently for about a week. Owner also mentioned lethargy and decrease energy level. Anorexia and mucous stools. Not Lepto vaccinated  
 Abnormal PE/Chem/CBC/UA Results: Alp: 1,776 GGT: 49 Bil total: > 27.9 Cholesterol: 472 T4: 0.9 Bile acid pre and post: over 180 Lepto snap neg Cpl: positive Radiographs were nsf

**SPECIES**

Canine

**ULTRASONOGRAPHIC EXAMINATION OF THE ABDOMEN**
**BREED**

Toy Poodle

**Urinary System**

The urinary bladder, trigone, and pelvic urethra are normal in thickness and the mucosal surface is smooth. The bladder lumen is moderately distended with anechoic urine. No masses, inflammatory changes or calculi are observed. The region of the trigone is normal.

**SEX**

Spayed Female

The left kidney is normal size (3.36 cm in length); normal shape and architecture with smooth peripheral margins. There is a normal 1:3 cortex to medulla ratio with minimal to mild loss of corticomedullary distinction. The cortex is hyperechoic. Several, nonobstructive nephroliths are visualized. There is no evidence of pyelectasia, infarcts or hydroureter.

**AGE**

8 years

The right kidney is normal size (3.76 cm in length); normal shape and architecture with smooth peripheral margins. There is a normal 1:3 cortex to medulla ratio with minimal to mild loss of corticomedullary distinction. The cortex is hyperechoic. Several, nonobstructive nephroliths are visualized. There is no evidence of pyelectasia, infarcts or hydroureter.

**WEIGHT**

10.2 lbs

**Adrenal Glands**

The left adrenal gland is normal size (0.34 cm at cranial pole) (0.41 cm at caudal pole); normal shape; homogenous parenchyma. The glandular echogenicity and detail are unremarkable. Capsule, cortex, and medullary definition are normal. The phrenicoabdominal vein and surrounding vasculature are normal.

**INTERPRETED BY**

Andrea Nicastro,  
 DVM, Diplomate  
 ACVIM (Small Animal  
 Internal Medicine)

The right adrenal gland is normal size (0.72 cm at cranial pole) (0.36 cm at caudal pole) (1.17 cm in length); normal shape; homogenous parenchyma. The glandular echogenicity and detail are unremarkable. Capsule, cortex, and medullary definition are normal. The phrenicoabdominal vein and surrounding vasculature are normal.

**IMAGING PERFORMED BY**

Dr. Reyes

**Spleen**

The spleen is normal in size (1.05 cm in width at the level of the hilus) with a normal capsular contour. There is appropriate echogenicity and echotexture. No focal lesions are observed. Splenic vasculature is normal.

**HOSPITAL NAME**

Mobile Vet Ultrasound

**Liver**

The liver is subjectively normal in size with normal contours and structure. There is appropriate echogenicity and echotexture. No overt structural evidence of inflammatory, infiltrative, or regenerative pathology is evident. Vascular and biliary tracts are of normal volume with no evidence of congestion. No pathological hepatic lymphadenopathy observed.

**REFERRING VET**

Dr. D'Ambrose

**INVOICE**

11097

The gall bladder lumen is overdistended. The wall is normal in thickness. A small amount of suspended, echogenic debris is observed within the lumen. The cystic duct is suspected to be dilated. However, gas shadowing from the gastric lumen obscures most of the region of the cystic and common bile ducts.

**DATE**

6/17/2022

### ***Gastrointestinal***

The gastric lumen is not distended. The gastric wall is normal in thickness with a normal layering pattern. The small intestinal lumen is not dilated. The small intestinal wall thickness is normal with a normal layering pattern and appropriate mural detail. Discreet masses are not identified. The colonic wall is normal. There is no evidence of an obstructive pattern.

### ***Pancreas***

The region of the pancreas is isoechoic relative to surrounding omental fat. No obvious parenchymal abnormalities are observed. There is no evidence of regional inflammation or effusion.

### ***Free Abdomen***

The peritoneal cavity is normal. There is no evidence of inflammation or effusion. The abdominal lymph nodes are normal/not visible.

## **ULTRASONOGRAPHIC FINDINGS**

### **Primary Findings**

- A structural bile duct obstruction (i.e., stone, tumor, stricture) is of major concern based on the patient's laboratory results, particularly, the total bilirubin. A functional obstruction (i.e., secondary to hepatocellular swelling) is also possible but is considered less likely.
- Pancreatic changes consistent with age-related remodeling +/- low-grade pancreatitis. Correlation with the patient's clinical history is recommended.

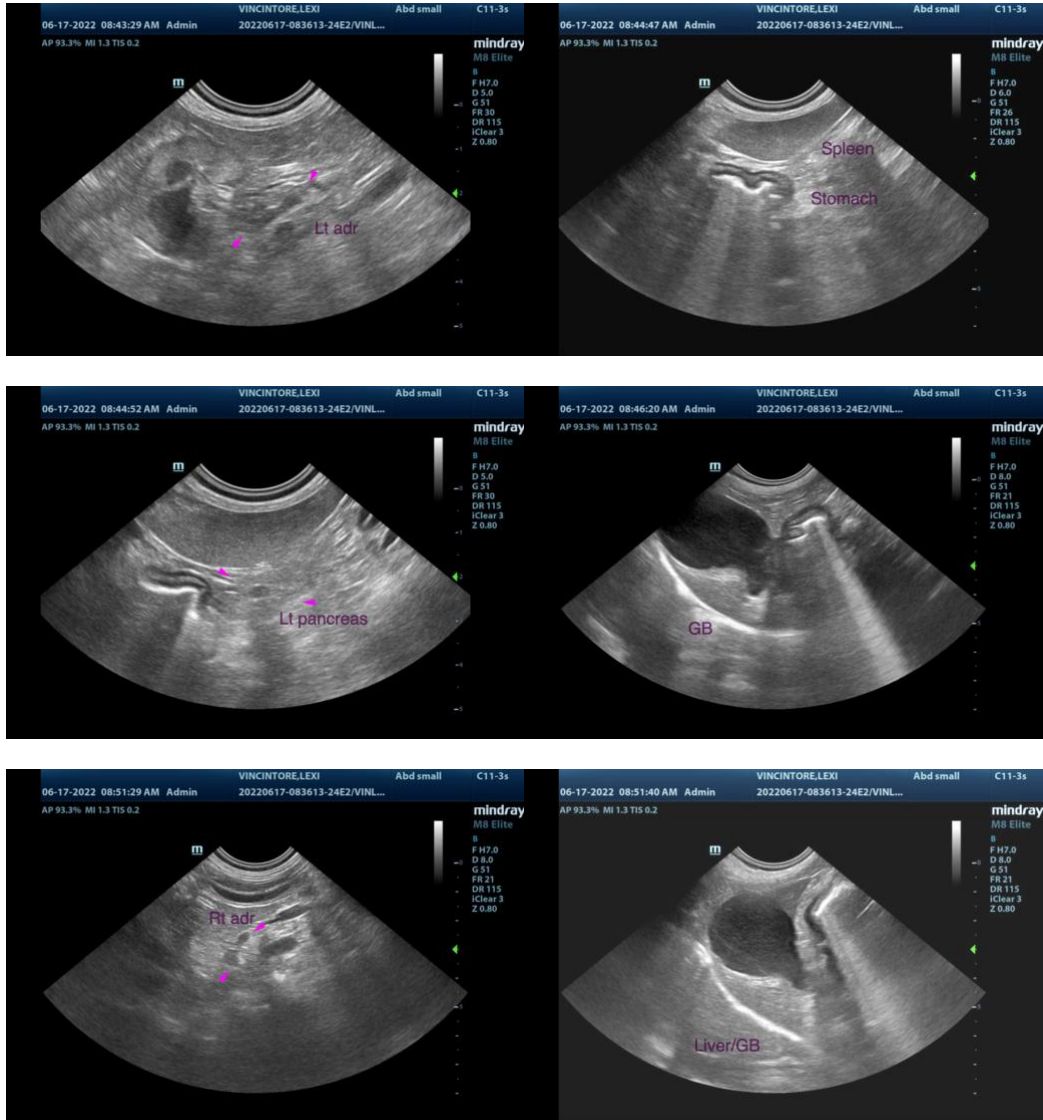
### **Secondary Findings**

- Bilateral, age-related changes with nonobstructive nephrolithiasis.

## **INTERPRETATION OF THE FINDINGS & FURTHER RECOMMENDATIONS**

An abdominal exploratory with assessment of bile duct patency is recommended. If surgery is pursued, liver biopsies are also recommended along with aerobic and anaerobic bile cultures, and acquisition of additional hepatic tissue samples for potential copper quantitation. If surgery is pursued, clotting times and thoracic radiographs should be performed prior to anesthesia. Referral to a board-certified surgeon is also strongly recommended due to the need for a bile duct re-routing procedure and the possibility of perioperative complications.

If surgery is not to be pursued at this time, aggressive supportive care with fluid therapy, broad-spectrum antibiotics, gastric protectants, antiemetics and pain medication is recommended, with daily monitoring of the patient's total bilirubin. If the total bilirubin continues to increase, surgery should be considered.



The information and recommendations provided are based on the images presented by the referring veterinarian/sonographer. No evaluation can be communicated regarding pathology that was not visible in the image/video clips provided.

Thank you for this referral. If the clinical or image interpretation does not parallel your findings or if I can be of any further assistance, please contact me.

**Andrea Nicastro, DVM, Diplomate DACVIM (Small Animal Internal Medicine)**  
[info@SonoPath.com](mailto:info@SonoPath.com)