


PATIENT PRESENTING CLINICAL SIGNS

Lilly Tejadilla
SPECIES
 History: Lilly is doing well overall. She has lost ~4# in the last 2 months, but the O has not noticed any change in appetite. She was recently started on Proin and Incurin to control urinary incontinence and resultant chronic UTI. Doing well with this. This exam is a follow up to previous, as nodules were noted in the spleen and in the liver.

Canine
 Abnormal PE/Chem/CBC/UA Results: Last full labs in 12/21: CBC/Chem/UA are WNL. T4 is low normal. Urine culture from March 2022: no growth

BREED ULTRASONOGRAPHIC EXAMINATION OF THE ABDOMEN

Lab Retriever
Urinary System

SEX
 Spayed Female
 The urinary bladder, trigone, and pelvic urethra are normal in thickness and the mucosal surface is smooth. The bladder lumen is moderately distended with anechoic urine. No masses, inflammatory changes or calculi are observed. Ureteral papillae and visualized portion of the proximal urethra, visible to a depth of 2 cm, are normal.

AGE
 13.5 years
 The left kidney is normal size (6.31 cm in length); normal shape and architecture with smooth peripheral margins. There is a normal 1:3 cortex to medulla ratio with mild to moderate loss of corticomedullary distinction. There is no evidence of pyelectasia, nephroliths, infarcts or hydroureter.

WEIGHT
 59 lbs
 The right kidney is normal size (5.28 cm in length); normal shape and architecture with smooth peripheral margins. There is a normal 1:3 cortex to medulla ratio with mild to moderate loss of corticomedullary distinction. There is no evidence of pyelectasia, nephroliths, infarcts or hydroureter.

Adrenal Glands

INTERPRETED BY
 Andrea Nicastro,
 DVM, Diplomate
 ACVIM (Small Animal
 Internal Medicine)
 The left adrenal gland is normal size (0.68 cm at cranial pole) (0.72 cm at caudal pole) (2.30 cm in length); with a normal shape and smooth peripheral contours. A 0.64 x 0.59 cm hyperechoic nodule is observed at the cranial pole. Glandular echogenicity and detail at the caudal pole appear normal. The phrenicoabdominal vein and surrounding vasculature are normal.

The caudal pole of the right adrenal gland is visualized and is upper limits of normal size (0.86 cm in width) with a normal shape, glandular echogenicity and detail. Surrounding vasculature appears normal.

IMAGING PERFORMED BY

Velasco

Spleen

HOSPITAL NAME
 Bethany Family PC
 The spleen is normal in size (1.83 cm in width at the level of the hilus) with a normal capsular contour. There is appropriate echogenicity and echotexture. No focal lesions are observed. Splenic vasculature is normal.

Liver
REFERRING VET

Dr. Velasco

The liver is subjectively prominent in size with normal curvilinear peripheral contours. The parenchyma is isoechoic relative to the spleen and subtly mottled/heterogenous in appearance. At least one hypoechoic nodule is observed on the left side, measuring 1.83 cm in length. Hepatic vasculature and intrahepatic biliary tracts are of normal volume with no evidence of congestion.

INVOICE

11101

The gall bladder lumen is moderately distended. The wall is thin and smooth. Luminal contents are anechoic. The cystic and common bile ducts are normal/not seen.

DATE

6/16/22

Gastrointestinal

The gastric lumen is mildly distended with ingesta. The gastric wall is normal in thickness with a normal layering pattern. The small intestinal lumen is segmentally dilated with gas and chyme. The small intestinal wall thickness is normal with a normal layering pattern and appropriate mural detail. Discreet masses are not identified. The colonic wall is normal. There is no evidence of an obstructive pattern.

Pancreas

The region of the pancreas is isoechoic relative to surrounding omental fat. No obvious parenchymal abnormalities are observed. There is no evidence of regional inflammation or effusion.

Free Abdomen

The peritoneal cavity is normal. There is no evidence of inflammation or effusion. The abdominal lymph nodes are normal/not visible.

ULTRASONOGRAPHIC FINDINGS

Primary Findings

- The hepatic parenchymal changes are similar to the previous sonogram and are suggestive of a benign process such as regenerative nodular hyperplasia or vacuolar hepatopathy. However, correlation with recent liver values is recommended.

*The previously observed splenic mass is not seen on today's scan.

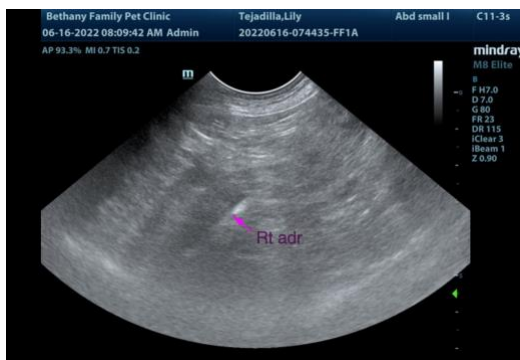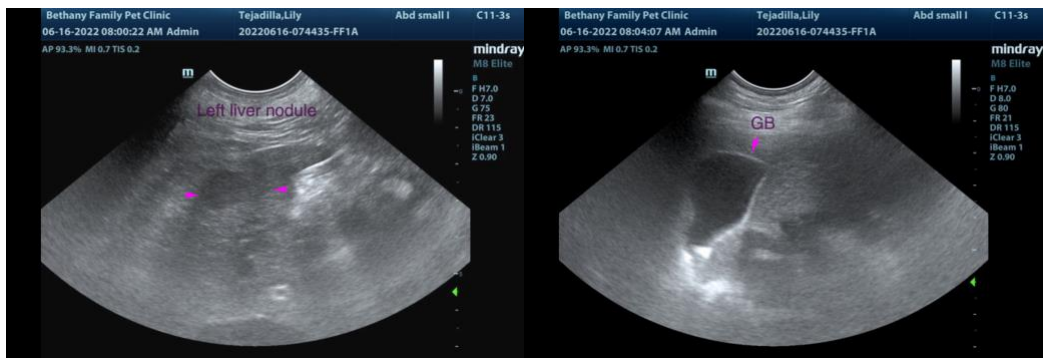
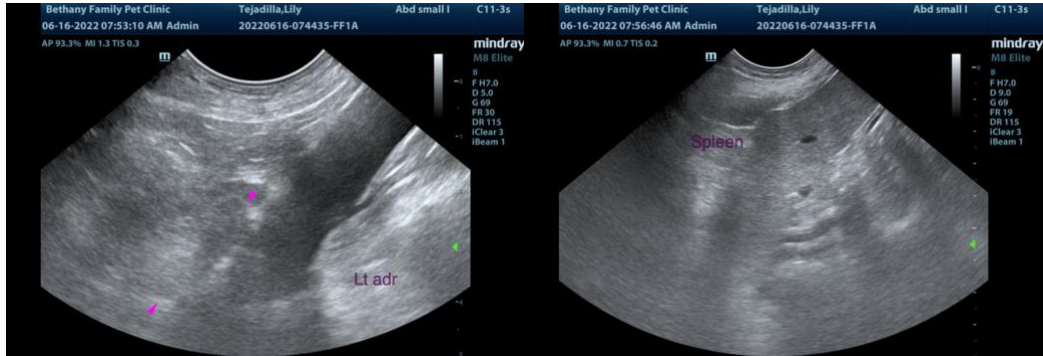
Secondary Findings

- The left adrenal nodule trend toward the benign (i.e., benign nodular hyperplasia). However, an emerging tumor cannot be completely ruled out.
- Minor, bilateral, age-related renal changes

INTERPRETATION OF THE FINDINGS & FURTHER RECOMMENDATIONS

Recheck lab-work, including a CBC chemistry panel, urinalysis and T4 is recommended to assess for changes in metabolic function since the previous lab-work from December 2021.

Given the weight loss, consider thoracic radiographs (to assess for occult neoplasia in the chest) as well as a malabsorption panel, including serum cobalamin and folate, TLI and PLI (to evaluate for low-grade pancreatitis disease and maldigestion/malabsorption).



The information and recommendations provided are based on the images presented by the referring veterinarian/sonographer. No evaluation can be communicated regarding pathology that was not visible in the image/video clips provided.

Thank you for this referral. If the clinical or image interpretation does not parallel your findings or if I can be of any further assistance, please contact me.

Andrea Nicastro, DVM, Diplomate DACVIM (Small Animal Internal Medicine)
info@SonoPath.com