

**DATE PRESENTING CLINICAL SIGNS**

6/16/2022 Pet came in for limping/adr. Swollen RH hock. Pet would not let do x-rays without sedation. Sent out labs and had elevated liver values. Recommended u/s- Pet has arrhythmia.

PATIENT

Chuilu Vandine

Current Medications: Carprofen 50mg BID (started after pulling blood), Gabapentin 200mg BID-TID (started after pulling meds).

Lab Results: AST 116, ALT 269, ALKP 2182, GGT 24.

Date of Previous IntraPet Ultrasound: No previous.

SPECIES

Canine

Sedation: torb/midaz

Stat Report: Not requested.

BREED

Shar Pei

Imaging Performed By: Rachel Brillhart, RDMS.

ULTRASONOGRAPHIC EXAMINATION OF THE ABDOMEN**SEX**

Neutered Male

Urinary System

The urinary bladder, trigone, and pelvic urethra are normal in thickness and the mucosal surface is smooth. The bladder lumen is moderately distended with anechoic urine. No masses, inflammatory changes or calculi are observed. Ureteral papillae and visualized portion of the proximal urethra, visible to a depth of 3-4 cm, are normal.

AGE

12/14/08

The prostate is normal in size (0.90 cm in width) and shape. Parenchyma is homogenous. The prostatic urethra appears normal without evidence of dilation or obstruction.

WEIGHT

51.8 lbs

The left kidney is normal size (5.33 cm in length); normal shape and architecture with smooth peripheral margins. There is a normal 1:3 cortex to medulla ratio with minimal loss of corticomedullary distinction. There is no evidence of pyelectasia, nephroliths, infarcts or hydronephrosis. Renal vasculature is normal.

INTERPRETED BY

Andrea Nicastro, DMV,
Diplomate DACVIM
(Small Animal
Internal Medicine)

The right kidney is normal size (5.49 cm in length); normal shape and architecture with smooth peripheral margins. There is a normal 1:3 cortex to medulla ratio with with minimal to mild loss of corticomedullary distinction. There is no evidence of pyelectasia, nephroliths, infarcts or hydronephrosis. Renal vasculature is normal.

Adrenal Glands**HOSPITAL NAME**

Everhart VH

The left adrenal gland is normal size (0.56 cm at cranial pole) (0.63 cm at caudal pole) (2.29 cm in length); normal shape; homogenous parenchyma. The glandular echogenicity and detail are unremarkable. Capsule, cortex, and medullary definition are normal. The phrenicoabdominal vein and surrounding vasculature are normal.

REFERRING VET

Dr. Key

The right adrenal gland is enlarged at the cranial pole and normal in size at the caudal pole (1.52 cm at cranial pole) (0.50 cm at caudal pole) (2.97 cm in length); with an irregular shape. A 1.85 x 1.32 cm hyperechoic to slightly heterogenous nodule is observed at the cranial pole. The lesion causes capsular expansion. The glandular echogenicity and detail at the caudal pole are normal. The phrenicoabdominal vein and surrounding vasculature appear normal.

INVOICE

11094

Spleen

The spleen is normal in size (1.24 cm in width at the level of the hilus) with a normal capsular contour. There is appropriate echogenicity and echotexture. No focal lesions are observed. Splenic vasculature is normal.

Liver

The liver is subjectively normal in size with normal curvilinear peripheral contours. The parenchyma is slightly mottled in appearance. No distinct focal lesions are observed. Vascular and biliary tracts are of normal volume with no evidence of congestion

The gall bladder lumen is moderately distended. The wall is thin and smooth. A small amount of echogenic to mineralized, gravity dependent debris is observed within the lumen. The cystic and common bile ducts are normal/not seen.

Gastrointestinal

The gastric lumen is distended with ingesta. The gastric wall is normal in thickness with a normal layering pattern. The small intestinal lumen is not dilated. The small intestinal wall thickness is normal with a normal layering pattern and appropriate mural detail. Discreet masses are not identified. The ileocecolic junction and colonic wall are normal. There is no evidence of an obstructive pattern.

Pancreas

A portion of the pancreas is obscured by the gastric distention. In the visualized portions, no obvious pathology is seen.

Free Abdomen

The peritoneal cavity is normal. There is no evidence of inflammation or effusion. The abdominal lymph nodes are normal/not visible.

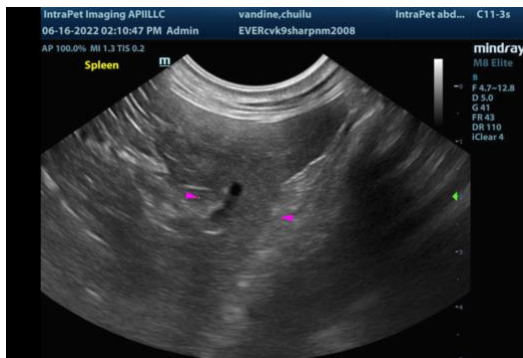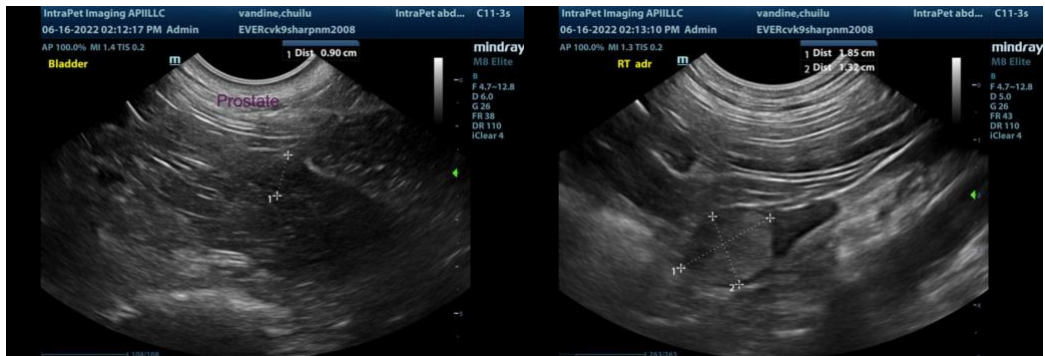
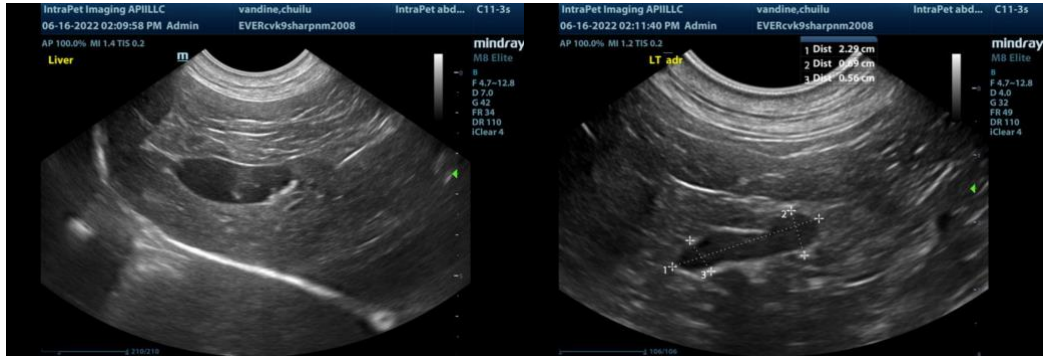
ULTRASONOGRAPHIC FINDINGS

Primary Findings

- Right, adrenal nodule. Differentials include benign nodular hyperplasia and neoplasia (i.e., adenoma, adenoma carcinoma, pheochromocytoma).
- The diffuse hepatic changes are non-specific and could be consistent with vacuolar hepatopathy, regenerative nodular hyperplasia, and/or age-related remodeling. Inflammatory and infiltrative disease are considered less likely.

INTERPRETATION OF THE FINDINGS & FURTHER RECOMMENDATIONS

- To determine if a functional right adrenal tumor is present, consider urine/blood catecholamine levels and a low-dose dexamethasone suppression test. A baseline blood pressure measurement is also recommended to assess for hypertension.
- Given the arrhythmia, an ECG, thoracic radiographs, and echocardiogram are recommended.
- Serial monitoring (i.e., every 3-4 months) of the patient's liver values is recommended. If values continue to increase, a repeat abdomen ultrasound +/- a more advanced hepatic work-up (i.e., tissue sampling) may be warranted.



The information and recommendations provided are based on the images presented by the referring veterinarian/sonographer. No evaluation can be communicated regarding pathology that was not visible in the image/video clips provided.

Thank you for this referral. If the clinical or image interpretation does not parallel your findings or if I can be of any further assistance, please contact me.

Andrea Nicastro, DVM, Diplomate DACVIM (Small Animal Internal Medicine)
info@SonoPath.com