**PATIENT**

April Falcon

**SPECIES**

Canine

**BREED**

Maltipoo

**SEX**

Intact Female

**AGE**

9 years

**WEIGHT**

8 lbs

**INTERPRETED BY**

Andrea Nicastro,  
DVM, Diplomate  
ACVIM (Small Animal  
Internal Medicine)

**IMAGING PERFORMED BY**

Potomac Mobile  
Veterinary Ultrasound

**HOSPITAL NAME**

Vienna AH

**REFERRING VET**

Dr. Cathy Jarrett

**INVOICE**

11081

**DATE**

6.15.22

**PRESENTING CLINICAL SIGNS**

History: Sharply elevated liver enzymes (normal last year), chronic GT signs, weight loss, trembling, and biting. Currently on Cobalamin, nutritionist prescribed diet, and Metronidazole sporadically.

Abnormal PE/Chem/CBC/UA Results: (06/09/2022) CBC: MONO 1.432. CHEM: ALT 830, AST 419, ALP 1048, GGT 32, Albumin 2.6. U/A: USG 1.015 and pH 7.0. (05/04/2021) CBC: WNL. CHEM: BUN 36, Creatine Kinase 305, Cobalamin 160, Folate 2.1.

**ULTRASONOGRAPHIC EXAMINATION OF THE ABDOMEN****Urinary System**

The urinary bladder is mildly distended. The wall in the region of the apex is slightly thickened and irregular. A 0.53 cm aggregation of mineralized sand versus a distinct calculus is observed within the lumen. The remaining luminal contents are anechoic. The region of the trigone is normal.

The left kidney presented normal size (4.25 cm in length); normal shape and architecture with smooth peripheral margins. There is a normal 1:3 cortex to medulla ratio with mild to moderate loss of corticomedullary distinction. There is no evidence of pyelectasia, nephroliths, infarcts or hydroureter. Renal vasculature is normal.

The right kidney presented normal size (4.18 cm in length); normal shape and architecture with smooth peripheral margins. There is a normal 1:3 cortex to medulla ratio with mild loss of corticomedullary distinction. There is no evidence of pyelectasia, nephroliths, infarcts or hydroureter. Renal vasculature is normal.

**Adrenal Glands**

The left adrenal gland is borderline small in size (0.27 cm at cranial pole) (0.37 cm at caudal pole); normal shape and smooth peripheral contours. Glandular echogenicity and detail are unremarkable. Capsule, cortex, and medullary definition are normal. The phrenicoabdominal vein and surrounding vasculature are normal.

The right adrenal gland is small in size (0.62 cm at cranial pole) (0.24 cm at caudal pole); with a normal shape and smooth peripheral contours. Glandular echogenicity and detail are unremarkable. Capsule, cortex, and medullary definition are normal. The phrenicoabdominal vein and surrounding vasculature are normal.

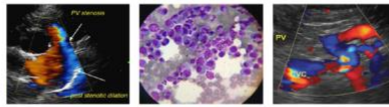
**Spleen**

The spleen is normal in size (1.17 cm in width at the level of the hilus) with a normal capsular contour. There is appropriate echogenicity and echotexture. No focal lesions are observed. Splenic vasculature is normal.

**Liver**

The liver is subjectively normal in size with normal contours and structure. There is appropriate echogenicity and echotexture. No overt structural evidence of inflammatory, infiltrative or regenerative pathology is evident. Vascular and biliary tracts are of normal volume with no evidence of congestion. No pathological hepatic lymphadenopathy observed.

The gall bladder is distended. The wall is normal in thickness. A small to moderate amount of gravity dependent, echogenic debris is observed within the lumen. The proximal cystic duct is dilated, but

**PATIENT**

April Falcon

tapers to a normal diameter as it extends to the common bile duct. The common bile duct measures 0.20 cm in diameter and can be seen entering into the duodenal papilla. There is no obvious evidence of an intraluminal obstruction. However, the common bile duct cannot be seen in its entirety.

**SPECIES**

Canine

**Gastrointestinal**

The stomach and intestine are free of stasis and exhibit normal peristaltic activity. The gastric lumen is not distended. The gastric wall and pylorus are normal in thickness with a normal layering pattern. The small intestinal lumen is not dilated. The small intestinal wall thickness is normal with a normal layering pattern and appropriate mural detail. Discreet masses are not identified. The colonic wall is normal. No obstructive or overt infiltrative disease is noted.

**BREED**

Maltipoo

**SEX**

Intact Female

**Pancreas**

The left limb is prominent in size with slightly irregular peripheral contours. The parenchyma is hypochoic relative to surrounding omental fat. No distinct focal lesions are observed. The pancreatic duct is not overtly dilated.

**AGE**

9 years

**Free Abdomen**

The peritoneal cavity is normal. There is no evidence of inflammation or effusion. The left, medial iliac lymph node is visible, measuring 1.01 x 0.19 cm.

**WEIGHT**

8 lbs

**Other**

The left ovary is subjectively normal in size (1.27 x 0.52 cm) with a normal shape and smooth peripheral contours. A 0.38 cm anechoic structure (follicle versus cyst) is observed at the caudal aspect. The remaining parenchyma is unremarkable. The right ovary is subjectively normal in size (1.08 x 0.56 cm) with homogenous parenchyma.

**INTERPRETED BY**

Andrea Nicastro,  
DVM, Diplomate  
ACVIM (Small Animal  
Internal Medicine)

The left uterine horn is minimally fluid distended.

The right uterine horn is moderately to severely fluid distended (1.54 cm), with aggregated, echogenic debris within the lumen.

**IMAGING PERFORMED BY**

Potomac Mobile  
Veterinary Ultrasound

**ULTRASONOGRAPHIC FINDINGS****Primary Findings**

- An obvious cause for the elevated liver enzymes is not identified in the study. However, a microscopic hepatopathy (i.e., bacterial cholangiohepatitis, Leptospirosis, chronic active hepatitis, copper-associated hepatotoxicity, infiltrative neoplasia (less likely)) cannot be excluded.
- Dilated cystic duct without obvious evidence of intraluminal obstruction
- Cystic calculus versus aggregation of mineralized sand
- The right uterine changes could be consistent with pyometra, mucometra or hydrometra. Correlation with the patient's clinical history is recommended
- The pancreatic changes are suggestive of chronic pancreatitis.

**HOSPITAL NAME**

Vienna AH

**REFERRING VET**

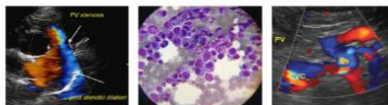
Dr. Cathy Jarrett

**INVOICE**

11081

**DATE**

6.15.22



**PATIENT**

April Falcon

**Secondary Findings**

**SPECIES**

Canine

- Bilateral, nonspecific age-related changes. The bilaterally small adrenal glands may be a normal variant for this patient or may represent early atrophy due to hypoadrenocorticism.

**BREED**

Maltipoo

**INTERPRETATION OF THE FINDINGS & FURTHER RECOMMENDATIONS**

**SEX**

Intact Female

- Consider an abdominal exploratory with liver biopsies, aerobic and anaerobic bile cultures, and acquisition of additional hepatic tissue samples for potential copper quantitation. An ovariohysterectomy should also be performed at the time of surgery, with submission of the uterus for histopathology. Clotting times should be checked prior to any tissue sampling procedure. Thoracic radiographs are recommended prior to any anesthetic event.

**AGE**

9 years

- If a more conservative approach is to be pursued at this time, consider empirical treatment for bacterial cholangiohepatitis (i.e., amoxicillin-clavulanic acid, Denamarin) as well as symptomatic care. If the liver values do not improve within 5-7 days of initiating therapy, hepatic tissue sampling should be reconsidered.

**WEIGHT**

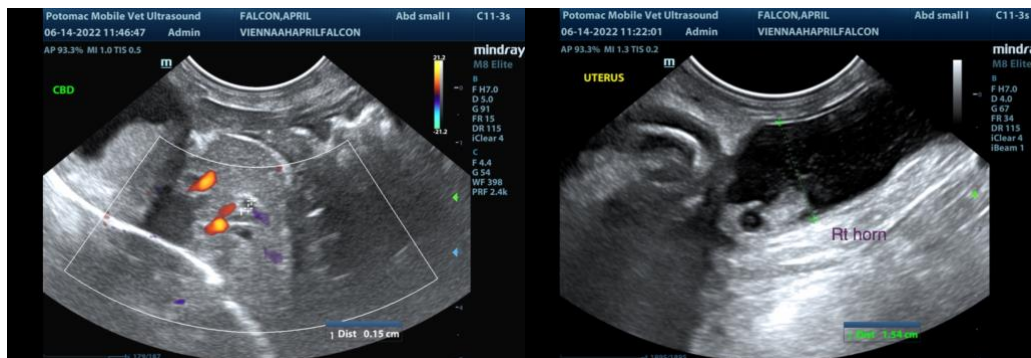
8 lbs

- A vaginal cytology to further assess for the possibility of a pyometra.

- Consider abdominal radiographs to determine if the mineralization within the urinary bladder is distinct calculus versus sand. If a calculus is present and surgery is pursued, a cystotomy with stone removal, analysis and culture should also be considered.

**INTERPRETED BY**

Andrea Nicastro,  
DVM, Diplomate  
ACVIM (Small Animal  
Internal Medicine)

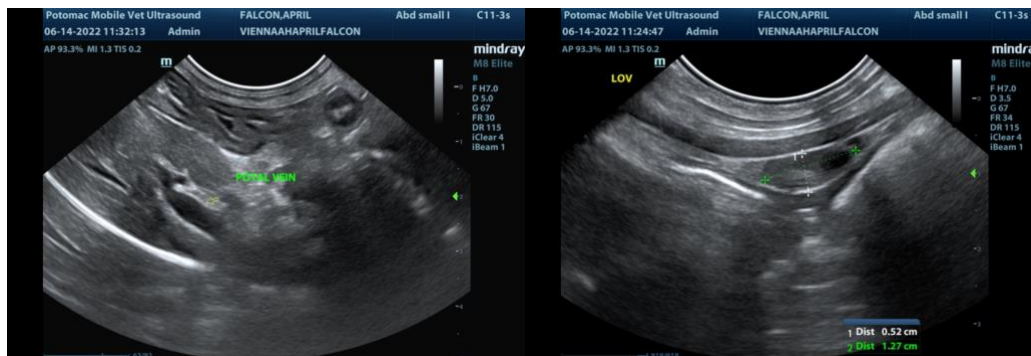


**IMAGING PERFORMED BY**

Potomac Mobile  
Veterinary Ultrasound

**HOSPITAL NAME**

Vienna AH



**REFERRING VET**

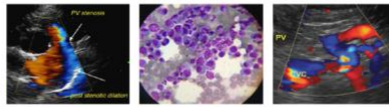
Dr. Cathy Jarrett

**INVOICE**

11081

**DATE**

6.15.22



**PATIENT**

April Falcon

**SPECIES**

Canine

**BREED**

Maltipoo

**SEX**

Intact Female

**AGE**

9 years

**WEIGHT**

8 lbs

**INTERPRETED BY**

Andrea Nicastro,  
DVM, Diplomate  
ACVIM (Small Animal  
Internal Medicine)

**IMAGING  
PERFORMED BY**

Potomac Mobile  
Veterinary Ultrasound

**HOSPITAL NAME**

Vienna AH

**REFERRING VET**

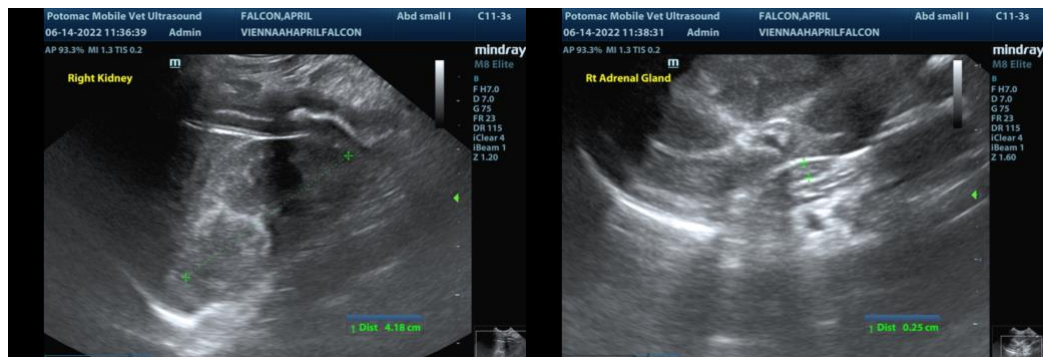
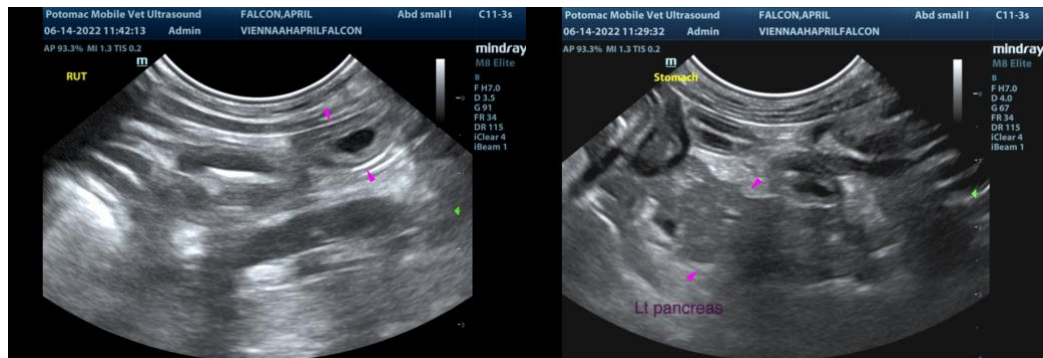
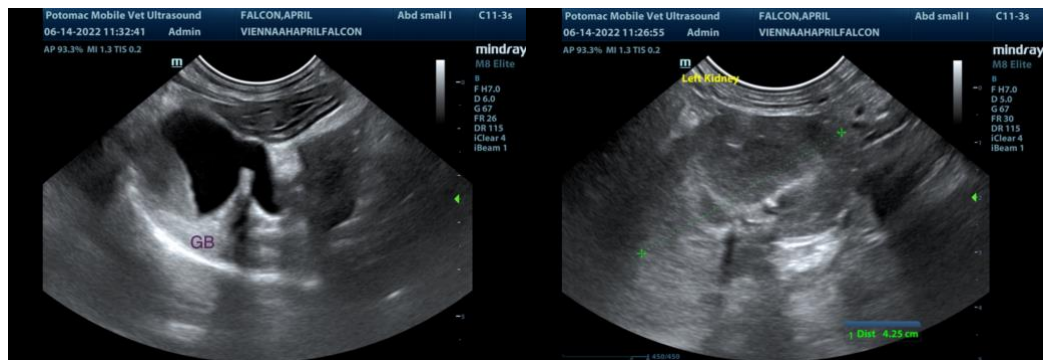
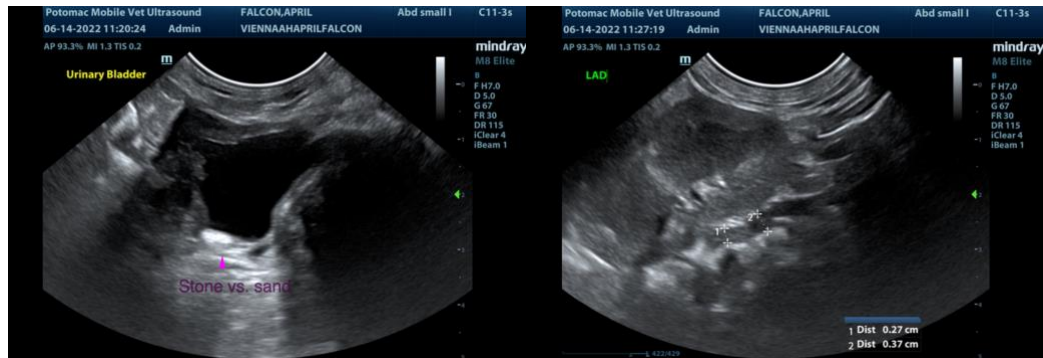
Dr. Cathy Jarrett

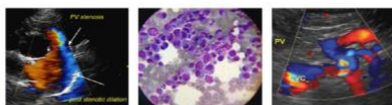
**INVOICE**

11081

**DATE**

6.15.22



**PATIENT**

April Falcon

**SPECIES**

Canine

**BREED**

Maltipoo

**SEX**

Intact Female

**AGE**

9 years

**WEIGHT**

8 lbs

**INTERPRETED BY**

Andrea Nicastro,  
 DVM, Diplomate  
 ACVIM (Small Animal  
 Internal Medicine)

**IMAGING PERFORMED BY**

Potomac Mobile  
 Veterinary Ultrasound

**HOSPITAL NAME**

Vienna AH

**REFERRING VET**

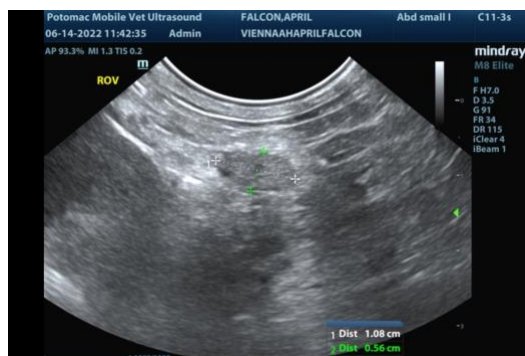
Dr. Cathy Jarrett

**INVOICE**

11081

**DATE**

6.15.22



The information and recommendations provided are based on the images presented by the referring veterinarian/sonographer. No evaluation can be communicated regarding pathology that was not visible in the image/video clips provided.

Thank you for this referral. If the clinical or image interpretation does not parallel your findings or if I can be of any further assistance, please contact me.

**Andrea Nicastro, DVM, Diplomate DACVIM (Small Animal Internal Medicine)**  
 info@SonoPath.com