



PATIENT

Gino Fenech

PRESENTING CLINICAL SIGNS

History: History of new PU/PD Physical exam findings: BARH, patchy alopecia. All teeth have been extracted. Abdomen is comfortable Abnormal CBC values: mild thrombocytosis Abnormal Chemistry Values: mild increase in SDMA. No azotemia. Abnormal UA Values: USG 1016 Radiograph Findings (email radiographs if available): Reason for Ultrasound: look into cause of PU/PD. Urine culture and Lepto testing were also negative.

SPECIES

Canine

BREED

Chihuahua

ULTRASONOGRAPHIC EXAMINATION OF THE ABDOMEN

Urinary System

SEX

Neutered Male

The urinary bladder, trigone, and pelvic urethra are normal in thickness and the mucosal surface is smooth. The bladder lumen is moderately distended with anechoic urine. No masses, inflammatory changes or calculi are observed. The region of the trigone and the visible portion of the proximal urethra are normal.

AGE

15 years

The prostate is normal in size (0.72 cm in width) and shape. Parenchyma is homogenous. The prostatic urethra appears normal without evidence of dilation or obstruction.

WEIGHT

7 lbs

The left kidney is normal size (3.64 cm in length); normal shape and architecture with smooth peripheral margins. There is a normal 1:3 cortex to medulla ratio with minimal loss of corticomedullary distinction. Mild to moderate pyelectasia is present (0.41 cm in the transverse plane). There is no evidence of nephroliths, infarcts or hydroureter.

The right kidney is normal size (3.70 cm in length); normal shape and architecture with smooth peripheral margins. There is a normal 1:3 cortex to medulla ratio with minimal loss of corticomedullary distinction. Mild pyelectasia is present (0.24 cm in the longitudinal plane). There is no evidence of nephroliths, infarcts or hydroureter.

INTERPRETED BY

Andrea Nicastro, DVM,
Diplomate ACVIM (Small
Animal Internal Medicine)

Adrenal Glands

The left adrenal gland mildly enlarged (0.46 cm at cranial pole) (0.61 cm at caudal pole); normal shape; homogenous parenchyma. The glandular echogenicity and detail are unremarkable. Capsule, cortex, and medullary definition are normal. The phrenicoabdominal vein and surrounding vasculature are normal.

IMAGING PERFORMED BY

Loetitia Saint-Jacques,
RVT LVT

HOSPITAL NAME

Alpine AH

The right adrenal gland is borderline enlarged (0.55 cm at caudal pole) (1.36 cm in length); normal shape; homogenous parenchyma. The glandular echogenicity and detail are unremarkable. Capsule, cortex, and medullary definition are normal. The phrenicoabdominal vein and surrounding vasculature are normal.

Spleen

REFERRING VET

Dr Lindsay Sjoloin

The spleen is normal in size (1.03 cm in width at the level of the hilus) with a normal capsular contour. There is appropriate echogenicity and echotexture. No focal lesions are observed. Splenic vasculature is normal.

INVOICE

10173

Liver

DATE

6/14/22

The liver is subjectively normal in size with normal contours and structure. There is appropriate echogenicity and echotexture. No overt structural evidence of inflammatory, infiltrative, or regenerative pathology is evident. Vascular and biliary tracts are of normal volume with no evidence of congestion. No pathological hepatic lymphadenopathy observed.



PATIENT

Gino Fenech

SPECIES

Canine

BREED

Chihuahua

SEX

Neutered Male

AGE

15 years

WEIGHT

7 lbs

INTERPRETED BY

Andrea Nicastro, DVM,
Diplomate ACVIM (Small
Animal Internal Medicine)

IMAGING PERFORMED BY

Loetitia Saint-Jacques,
RVT LVT

HOSPITAL NAME

Alpine AH

REFERRING VET

Dr Lindsay Sjoloin

INVOICE

10173

DATE

6/14/22

The gall bladder lumen is moderately distended. The wall is thin and smooth. A moderate to large amount of aggregated, echogenic, suspended sludge, in a partially stellate pattern is observed within the lumen. The cystic and common bile ducts are normal/not seen.

Gastrointestinal

The gastric lumen is mildly distended with ingesta. The gastric wall and pylorus are normal in thickness with a normal layering pattern. The pyloric outflow tract is patent. The small intestinal lumen is segmentally dilated with chyme. The small intestinal wall thickness is normal with a normal layering pattern and appropriate mural detail. Discreet masses are not identified. The colonic wall is normal. There is no evidence of an obstructive pattern.

Pancreas

The right limb of the pancreas is visible with normal curvilinear peripheral contours. The parenchyma is largely isoechoic relative to surrounding omental fat and slightly mottled in appearance. The pancreatic duct is visible but not overtly dilated. There is no evidence of peripancreatic inflammation or effusion.

Free Abdomen

The peritoneal cavity is normal. There is no evidence of inflammation or effusion. The abdominal lymph nodes are normal/not visible.

ULTRASONOGRAPHIC FINDINGS

Primary Findings

- The gall bladder changes are consistent with a developing mucocele.
- The bilateral, renal pyelectasia could be consistent with occult pyelonephritis, age-related remodeling and/or PU/PD.

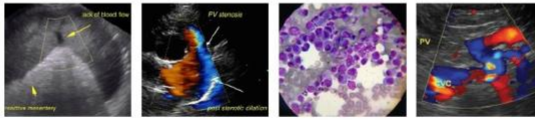
Secondary Findings

- Mild, bilateral adrenomegaly
- Minor, age-related pancreatic remodeling in the right limb

INTERPRETATION OF THE FINDINGS & FURTHER RECOMMENDATIONS

Despite the negative urine culture, consider empirical treatment for occult pyelonephritis (i.e., fluoroquinolone). If no improvement in the PU/PD is seen within 5-7 days of initiating therapy, antibiotics should be discontinued.

Further testing for Cushing's Disease (i.e., low-dose dexamethasone suppression test or ACTH stimulation test) can also be considered. However, Cushing's Disease is rare in patients with a normal ALP.



PATIENT

Gino Fenech

If the above diagnostic/therapeutics are inconclusive, consider the following:

- DDAVP trial to assess for central diabetes insipidus +/- a water deprivation test. It should be noted that water deprivation tests are risky in patients with underlying renal disease. Therefore, the risks may outweigh the benefits for this patient.

SPECIES

Canine

Regarding the gall bladder changes, a prophylactic cholecystectomy can be considered. If a more conservative approach is desired, consider initiation of ursodiol therapy with serial sonographic monitoring (i.e, every 4-6 weeks) of the gall bladder to assess for progression. Gall bladder mucoceles can be infected or rupture. If rupture occurs, bile/septic peritonitis will likely ensue.

BREED

Chihuahua

SEX

Neutered Male

AGE

15 years

WEIGHT

7 lbs

INTERPRETED BY

Andrea Nicastro, DVM,
Diplomate ACVIM (Small
Animal Internal Medicine)

IMAGING PERFORMED BY

Loetitia Saint-Jacques,
RVT LVT

HOSPITAL NAME

Alpine AH

REFERRING VET

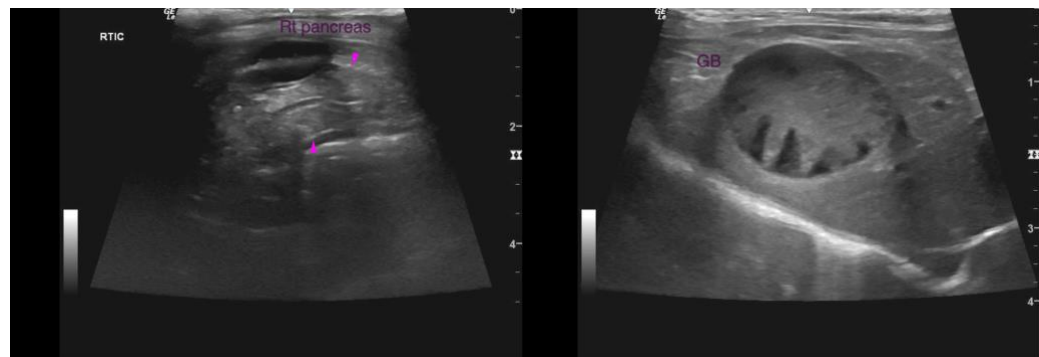
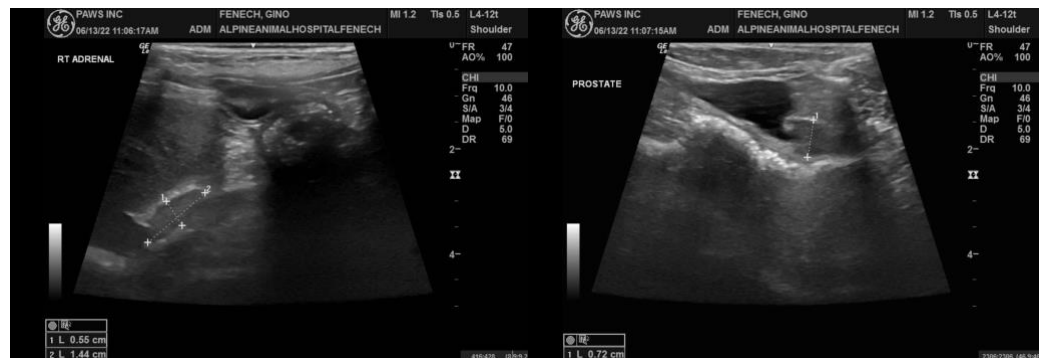
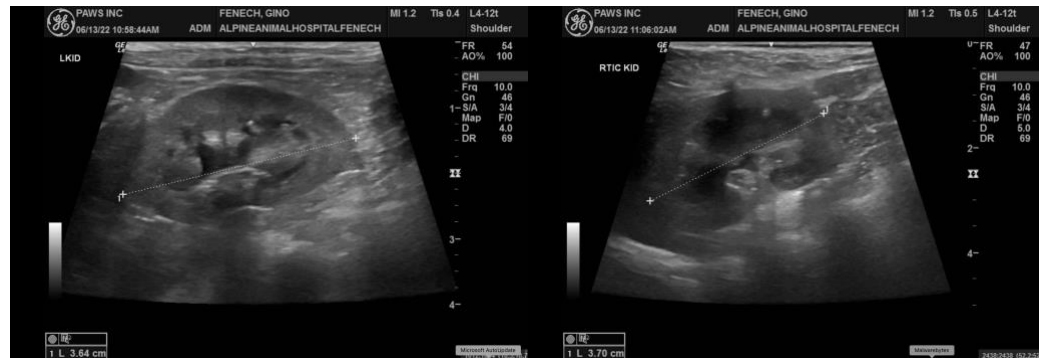Dr Lndsay Sjloin

INVOICE

10173

DATE

6/14/22





PATIENT

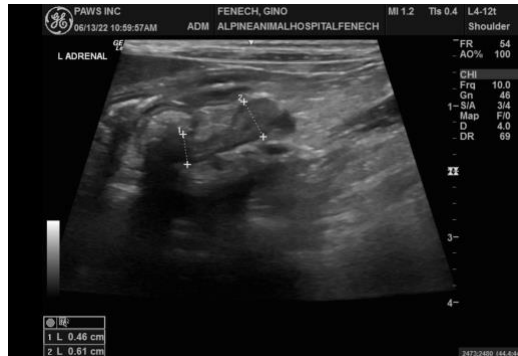Gino Fenech

SPECIES

Canine

BREED

Chihuahua



SEX

Neutered Male

The information and recommendations provided are based on the images presented by the referring veterinarian/sonographer. No evaluation can be communicated regarding pathology that was not visible in the image/video clips provided.

AGE

15 years

Thank you for this referral. If the clinical or image interpretation does not parallel your findings or if I can be of any further assistance, please contact me.

WEIGHT

7 lbs

Andrea Nicastro, DVM, Diplomate DACVIM (Small Animal Internal Medicine)
info@SonoPath.com

INTERPRETED BY

Andrea Nicastro, DVM,
Diplomate ACVIM (Small
Animal Internal Medicine)

IMAGING PERFORMED BY

Loetitia Saint-Jacques,
RVT LVT

HOSPITAL NAME

Alpine AH

REFERRING VET

Dr Lndsay Sjloin

INVOICE

10173

DATE

6/14/22