

**DATE PRESENTING CLINICAL SIGNS**

6/13/22

Recheck US to monitor cystitis and uterine stump changes. Seen 5/5 for chronic/recurrent UTI. Initial AUS revealed marked bladder wall thickening and changes to uterine stump (healing w/suture reaction vs stump pyometra). Has been on antibiotics and NSAID for approximately 4 weeks.

PATIENT

Kitty Sagner

Current Medications: Enrofloxacin 68mg once daily, Carprofen 12.5mg BID.

Date of Previous IntraPet Ultrasound: 5/5/22. See attached.

Sedation: Not required to complete full diagnostic ultrasound.

Stat Report: Not requested.

SPECIES

Canine

Imaging Performed By: Andi Parkinson, BS, RDMS.

BREED

Shih Tzu mix

ULTRASONOGRAPHIC EXAMINATION OF THE ABDOMEN

**This study was limited to the urinary system. There is a potential for pathology in organs that were not visualized.

SEX

Female, spayed

Urinary System

The urinary bladder is mildly to moderately distended. The wall in the region of the apex is moderately thickened (up to 0.74 cm) with a slightly irregular mucosal surface. The wall tapers to a normal thickness as it extends toward the cystourethral junction. A small amount of echogenic to mineralized debris is observed within the lumen. The region of the trigone and the visible portion of the proximal urethra are normal.

AGE

1/20/2015

The left kidney is normal size (4.17 cm in length); normal shape and architecture with smooth peripheral margins. There is a normal 1:3 cortex to medulla ratio with minimal to mild loss of corticomedullary distinction. Several non-obstructive nephroliths are visualized. There is no evidence of pyelectasia, infarcts or hydroureter.

WEIGHT

6.95 kg.

The right kidney is normal size (4.26 cm in length); normal shape and architecture with smooth peripheral margins. There is a normal 1:3 cortex to medulla ratio with normal corticomedullary distinction. There is no evidence of pyelectasia, nephroliths, infarcts or hydroureter. Renal vasculature is normal.

INTERPRETED BY

Andrea Nicastro, DVM,
Diplomate ACVIM
(Small Animal Internal
Medicine)

Adrenal Glands

The left adrenal gland is normal size (xxx cm at cranial pole) (xxx cm at caudal pole) (xxx cm in length); normal shape; homogenous parenchyma. The glandular echogenicity and detail are unremarkable. Capsule, cortex, and medullary definition are normal. The phrenicoabdominal vein and surrounding vasculature are normal.

HOSPITAL NAME

Nexus Veterinary
Specialists

The right adrenal gland is normal size (xxx cm at cranial pole) (xxx cm at caudal pole) (xxx cm in length); normal shape; homogenous parenchyma. The glandular echogenicity and detail are unremarkable. Capsule, cortex, and medullary definition are normal. The phrenicoabdominal vein and surrounding vasculature are normal.

REFERRING VET

Dr. Steele

Other

A 2.39 x 1.50 cm irregular aggregation of tissue, which is of fat opacity, is observed in the left caudal abdomen in the region of the uterine stump.

INVOICE

13471

ULTRASONOGRAPHIC FINDINGS**Primary Findings:**

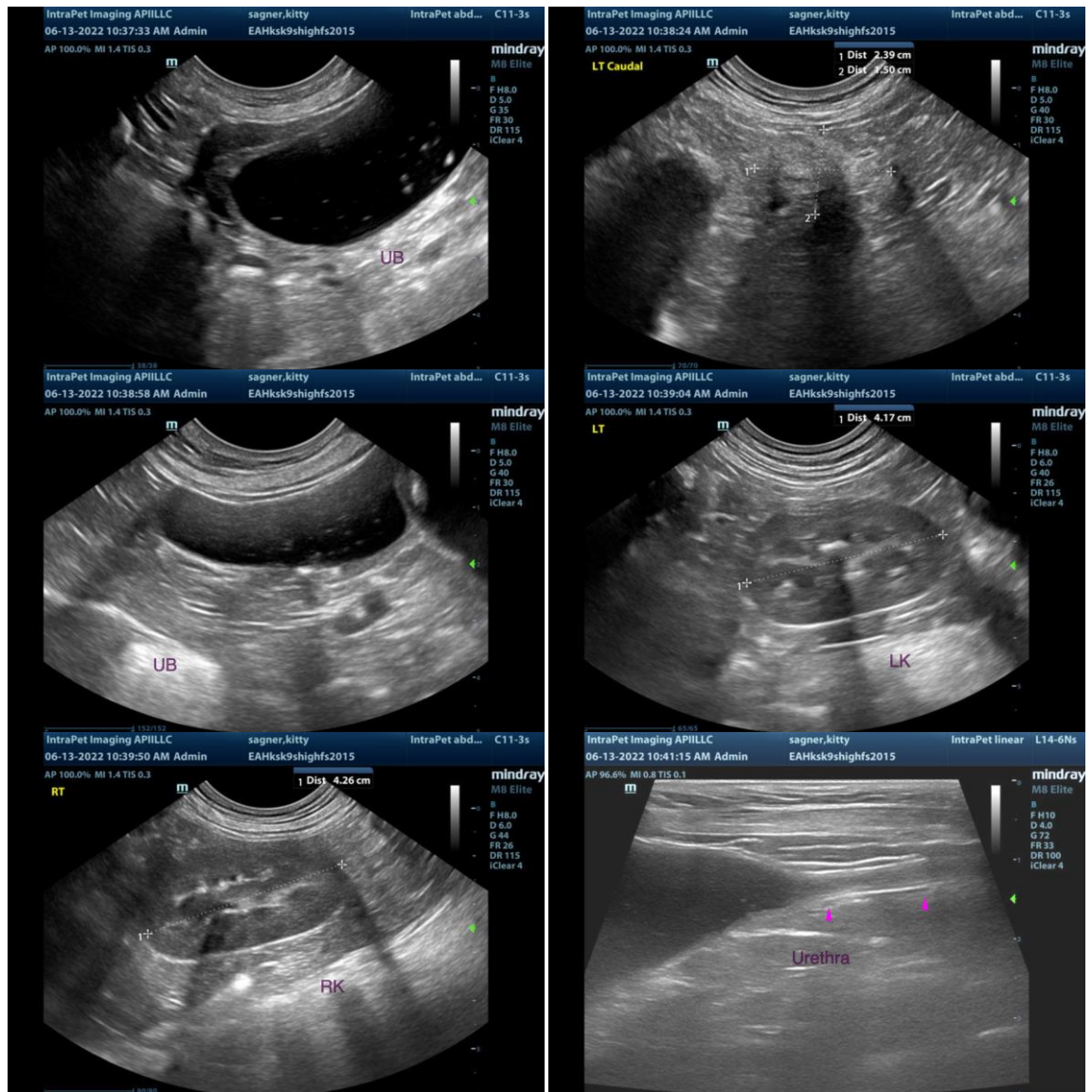
- The aggregation of tissue in the region of the uterine stump appears smaller/more dense compared to the previous sonogram. It may represent residual inflamed tissue, granuloma, other.

Secondary Findings:

- Bilateral, minor age-related renal changes with non-obstructive nephrolithiasis.
- Urinary bladder debris/sand. The urinary bladder wall thickening appears reduced and more confined to the apex (versus the diffuse thickening previously seen) compared to the previous study. However, the bladder is more distended today, making an exact comparison difficult.

INTERPRETATION OF THE FINDINGS & FURTHER RECOMMENDATIONS

Recommendations regarding this exam are to be implemented by Dr. Steele.



The information and recommendations provided are based on the images presented by the referring veterinarian. No evaluation can be communicated regarding pathology that was not visible in the image/video clips provided.

Thank you for this referral. If the clinical or image interpretation does not parallel your findings or if I can be of any further assistance please contact me.

Andrea Nicastro, DVM, Diplomate ACVIM (*Small Animal Internal Medicine*)
Andrea.nicastro@sonopath.com