



**PATIENT**

Shayna Gesualdi

**SPECIES**

Feline

**BREED**

DSH

**SEX**

Spayed Female

**AGE**

15 years

**WEIGHT**

7.1 lbs

**INTERPRETED BY**

Andrea Nicastro, DVM,  
Diplomate ACVIM  
(Small Animal Internal  
Medicine)

**IMAGING  
PERFORMED BY**

Kelly Vazquez

**HOSPITAL NAME**

Animal General Hudson

**REFERRING VET**

Dr. Stefanie Lang

**INVOICE**

10997

**DATE**

6/1/22

**PRESENTING CLINICAL SIGNS**

History: History of elevated PSL, liver values and anemia of chronic disease. No current meds.  
Abnormal PE/Chem/CBC/UA Results: AST 276, ALT 1041, ALP 230, bilirubin 3.1, PSL 28, HCT 28%.

**ULTRASONOGRAPHIC EXAMINATION OF THE ABDOMEN**

**Urinary System**

The urinary bladder, trigone, and pelvic urethra are normal in thickness and the mucosal surface is smooth. The bladder lumen is moderately distended with anechoic urine. No masses, inflammatory changes or calculi are observed. Ureteral papillae and visualized portion of the proximal urethra, visible to a depth of 1-2 cm, are normal.

The left kidney is small in size (2.68 cm in length); with a slightly irregular shape. There is a normal 1:3 cortex to medulla ratio with mild loss of corticomedullary distinction. Trace pyelectasia is present. There is no evidence of nephroliths or hydroureter. Renal vasculature is normal.

The right kidney is borderline small in size (3.05 cm in length); with a normal shape and smooth peripheral contours. A few, small cortical cysts is observed at the cranial pole. There is a normal 1:3 cortex to medulla ratio with mild loss of corticomedullary distinction. There is no evidence of pyelectasia, nephroliths, infarcts or hydroureter. Renal vasculature is normal.

**Adrenal Glands**

The left adrenal gland is normal size (0.71 cm length; 0.43 cm width). Normal shape and glandular echogenicity. The phrenicoabdominal vein and surrounding vasculature are normal.

The right adrenal gland is normal size (0.39 cm length; 0.28 cm width). Normal shape and glandular echogenicity. The phrenicoabdominal vein and surrounding vasculature are normal.

**Spleen**

The spleen is normal in size (0.93 cm in width at the level of the hilus) with a normal capsular contour. There is appropriate echogenicity and echotexture. No focal lesions are observed. Splenic vasculature is normal.

**Liver**

The liver is subjectively normal in size with normal contours and structure. There is appropriate echogenicity and echotexture. No overt structural evidence of inflammatory, infiltrative, or regenerative pathology is evident. Vascular and biliary tracts are of normal volume with no evidence of congestion. No pathological hepatic lymphadenopathy observed. The portal vein to caudal vena cava ratio is approximately 1: 1.

The gall bladder lumen is moderately distended. The wall is thin and smooth. Luminal contents are anechoic. The cystic and common bile ducts are normal. The duodenal papilla is normal in size (0.27 cm in width).

**Gastrointestinal**



## PATIENT

Shayna Gesualdi

## SPECIES

Feline

## BREED

DSH

## SEX

Spayed Female

## AGE

15 years

## WEIGHT

7.1 lbs

## INTERPRETED BY

Andrea Nicastro, DVM,  
Diplomate ACVIM  
(Small Animal Internal  
Medicine)

## IMAGING PERFORMED BY

Kelly Vazquez

## HOSPITAL NAME

Animal General Hudson

## REFERRING VET

Dr. Stefanie Lang

## INVOICE

10997

## DATE

6/1/22

The stomach and intestine are free of stasis and exhibit normal peristaltic activity. The gastric lumen is not distended. The gastric wall and pylorus are normal in thickness with a normal layering pattern. The pyloric outflow tract is patent. The small intestinal lumen is not dilated. The small intestinal wall thickness is normal with a normal layering pattern and appropriate mural detail. Discreet masses are not identified. The ileocecolic junction and colonic wall are normal. The colonic lumen contains shadowing fecal material. There is no evidence of an obstructive pattern.

### Pancreas

The pancreas is visible and normal in size with normal curvilinear peripheral contours. The parenchyma is slightly hypoechoic relative to surrounding omental fat and homogenous in appearance. No distinct focal lesions are observed. The pancreatic duct is not overtly dilated.

### Free Abdomen

The peritoneal cavity is normal. There is no evidence of inflammation or effusion. The abdominal lymph nodes are normal/not visible.

## ULTRASONOGRAPHIC FINDINGS

### Primary Findings

- An obvious cause for the elevated liver enzymes is not identified in the study. However, a microscopic hepatopathy (i.e., bacterial cholangiohepatitis, lymphoplasmacytic hepatitis, hepatic lipidosis, infiltrative neoplasia (less likely)) cannot be excluded.

### Secondary Findings

- Bilateral, chronic renal changes
- The pancreatic changes may be a normal variant for this patient or could be consistent with mild, chronic pancreatitis. Correlation with clinical findings is recommended.

## INTERPRETATION OF THE FINDINGS & FURTHER RECOMMENDATIONS

- To further evaluate for causes of the elevated liver enzymes, hepatic tissue sampling (i.e., fine-needle aspirate or surgical biopsy) would be necessary. Surgical biopsies are preferred in that they are more likely to yield a definitive diagnosis. Cytologic evaluation of the liver is best for identifying hepatic lipidosis and round cell neoplasia, but is less than ideal for diagnosing inflammatory hepatopathies, fibrosis, etc. If surgical biopsies are pursued, aerobic and anaerobic bile cultures are also recommended. Thoracic radiographs are recommended prior to any anesthetic event.
- If a conservative approach is desired, consider empirical treatment for bacterial cholangiohepatitis (amoxicillin-clavulanic acid, +/-metronidazole, Denamarin). If no improvement in the liver values is seen within 7-10 days of initiating therapy, antibiotics should be discontinued, and hepatic tissue sampling reconsidered. If liver values improve, continue therapy for at least 4-6 weeks and 1 week beyond normalization of the liver values.



**PATIENT**

Shayna Gesualdi

- Also consider a malabsorption panel, including serum cobalamin and folate, TLI and PLI, to further assess for concurrent pancreatic and GI disease.

**SPECIES**

Feline

**BREED**

DSH

**SEX**

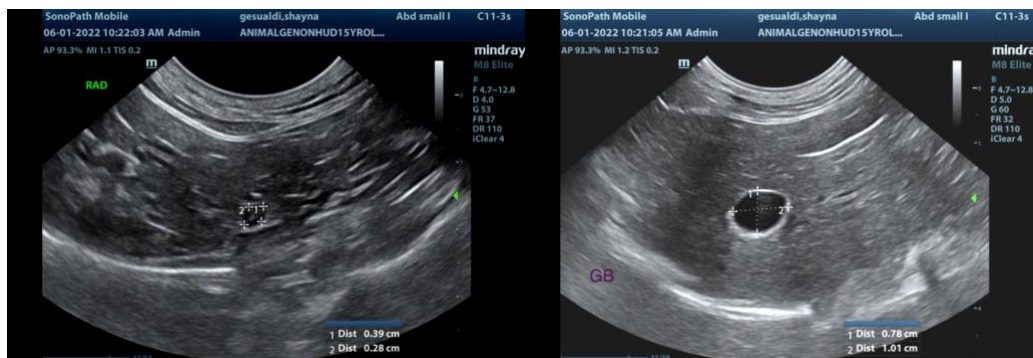
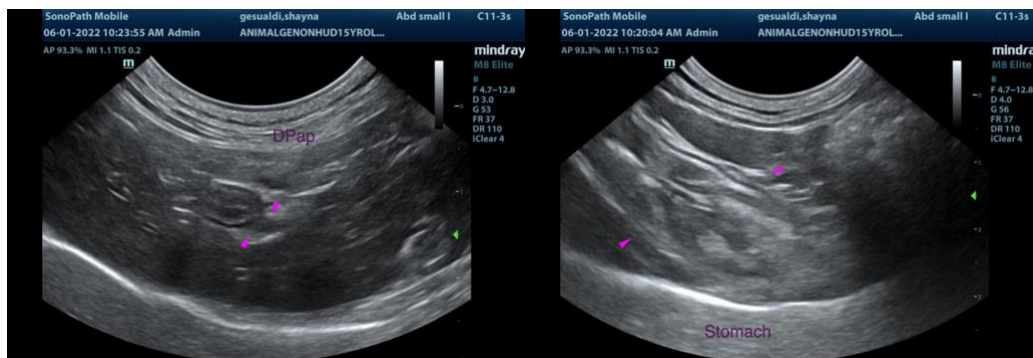
Spayed Female

**AGE**

15 years

**WEIGHT**

7.1 lbs



**INTERPRETED BY**

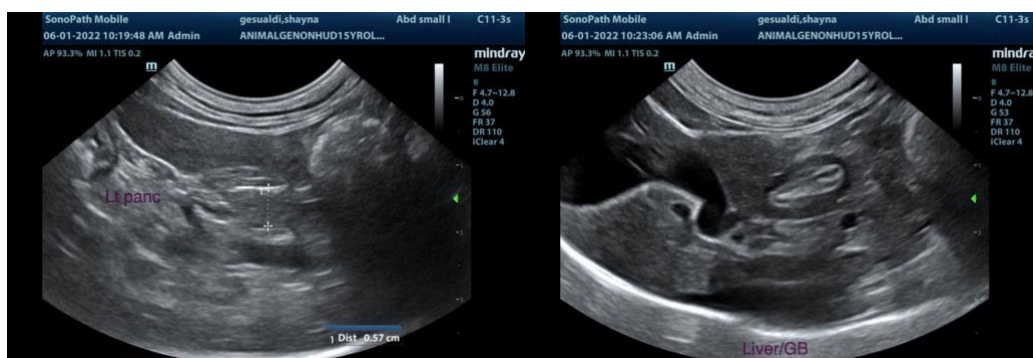
Andrea Nicastro, DVM,  
Diplomate ACVIM  
(Small Animal Internal  
Medicine)

**IMAGING  
PERFORMED BY**

Kelly Vazquez

**HOSPITAL NAME**

Animal General Hudson



**REFERRING VET**

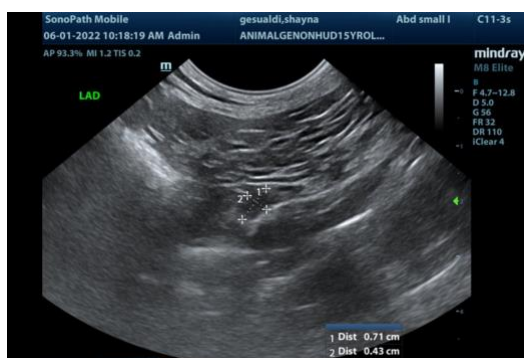Dr. Stefanie Lang

**INVOICE**

10997

**DATE**

6/1/22



The information and recommendations provided are based on the images presented by the referring veterinarian/sonographer. No evaluation can be communicated regarding pathology that was not



**PATIENT**

visible in the image/video clips provided.

Shayna Gesualdi

**SPECIES**

Feline

Thank you for this referral. If the clinical or image interpretation does not parallel your findings or if I can be of any further assistance, please contact me.

**Andrea Nicastro**, DVM, Diplomate DACVIM (Small Animal Internal Medicine)  
info@SonoPath.com

**BREED**

DSH

**SEX**

Spayed Female

**AGE**

15 years

**WEIGHT**

7.1 lbs

**INTERPRETED BY**

Andrea Nicastro, DVM,  
Diplomate ACVIM  
(*Small Animal Internal  
Medicine*)

**IMAGING  
PERFORMED BY**

Kelly Vazquez

**HOSPITAL NAME**

Animal General Hudson

**REFERRING VET**

Dr. Stefanie Lang

**INVOICE**

10997

**DATE**

6/1/22