



**PATIENT**

Widget Elliott

**SPECIES**

Canine

**BREED**

Jack Russell Terrier

**SEX**

Female, spayed

**AGE**

6 Yrs. 9 Months

**WEIGHT**

17.2 lbs.

**INTERPRETED BY**

Andrea Nicastro, DVM,  
Diplomate ACVIM  
(*Small Animal Internal  
Medicine*)

**IMAGING  
PERFORMED BY**

Amanda Lacey-Crook

**HOSPITAL NAME**

Rivers Edge Pet  
Medical Center

**REFERRING VET**

Dr. David Gray

**INVOICE**

13333

**DATE**

5/9/22

**PRESENTING CLINICAL SIGNS**

History: P presented for vomiting, anorexia and decreased water intake. P ate a rat on 4/29. Antifreeze testing was light positive but pet poison control recommended lepto testing due to case history, Lepto ELISA positive, waiting on Lepto PCR. P is icteric and hospitalized at this time. Abnormal PE/Chem/CBC/UA Results: CBC shows a neutrophilia with a possible left shift. Creatinine 2.8, BUN 87, ALP >2,000, ALT is 205, total bilirubin 11.8. The patient is currently getting Doxycycline, Unison, Metronidazole, Cerenia and Sam-E.

**ULTRASONOGRAPHIC EXAMINATION OF THE ABDOMEN**

*Urinary System*

The urinary bladder, trigone, and pelvic urethra are normal in thickness and the mucosal surface is smooth. The bladder lumen is moderately distended. A moderate amount of suspended echogenic debris is observed within the lumen. No masses, inflammatory changes or calculi are observed. The region of the trigone and the proximal urethra, visible to a depth of 1-2 cm, are normal.

The left kidney is normal size (4.59 cm in length); normal shape and architecture with smooth peripheral margins. There is a normal 1:3 cortex to medulla ratio with minimal loss of corticomedullary distinction. There is no evidence of pyelectasia, nephroliths, infarcts or hydroureter. Renal vasculature is normal.

The right kidney is normal size (4.88 cm in length); normal shape and architecture with smooth peripheral margins. There is a normal 1:3 cortex to medulla ratio with minimal loss of corticomedullary distinction. There is no evidence of pyelectasia, nephroliths, infarcts or hydroureter. Renal vasculature is normal.

*Adrenal Glands*

The left adrenal gland is normal size (0.49 cm at cranial pole) (0.54 cm at caudal pole) (2.06 cm in length); normal shape; homogenous parenchyma. The glandular echogenicity and detail are unremarkable. Capsule, cortex, and medullary definition are normal. The phrenicoabdominal vein and surrounding vasculature are normal.

The right adrenal gland is normal size (1.13 cm at cranial pole) (0.59 cm at caudal pole) (1.83 cm in length); normal shape; homogenous parenchyma. The glandular echogenicity and detail are unremarkable. Capsule, cortex, and medullary definition are normal. The phrenicoabdominal vein and surrounding vasculature are normal.

*Spleen*

The spleen is normal in size (1.42 cm in width at the level of the hilus) with a normal capsular contour. There is appropriate echogenicity and echotexture. Several small myelolipomas are visualized. Splenic vasculature is normal.

*Liver*

The liver is subjectively normal in size with normal contours and structure. There is appropriate echogenicity and echotexture. No overt structural evidence of inflammatory, infiltrative or regenerative pathology is evident. Vascular and biliary tracts are of normal volume with no evidence of congestion. No pathological hepatic lymphadenopathy observed. The gall bladder lumen is moderately distended. The wall is normal in thickness. A moderate amount of aggregated echogenic, partially dependent debris/sludge is observed within the lumen. The cystic and common bile ducts are normal.



**PATIENT**

The common bile duct measures 0.19 cm in diameter at the distal aspect and can be seen entering the duodenal papilla, which is also normal, measuring 0.46 cm in width.

Widget Elliott

***Gastrointestinal***

**SPECIES**

The stomach and intestine are free of stasis and exhibit normal peristaltic activity. The gastric lumen is not distended. The gastric wall and pylorus are normal in thickness with a normal layering pattern. The pyloric outflow tract is patent. The small intestinal lumen is not dilated. The small intestinal wall thickness is normal with a normal layering pattern and appropriate mural detail. Discreet masses are not identified. The colonic wall is normal. No obstructive disease is noted.

Canine

**BREED**

Jack Russell Terrier

***Pancreas***

**SEX**

The pancreas is normal in size with normal peripheral contours. The pancreatic duct is normal. The base and limbs of the pancreas are isoechoic to surrounding omental fat. No focal lesions are observed. There is no evidence of peripancreatic inflammation or effusion.

Female, spayed

***Free Abdomen***

**AGE**

The peritoneal cavity is normal. There is no evidence of inflammation or effusion. The abdominal lymph nodes are normal/not visible.

6 Yrs. 9 Months

***Other***

**WEIGHT**

A brief echocardiogram reveals no evidence of pericardial effusion or obvious right atrial/auricular mass.

17.2 lbs.

**INTERPRETED BY**

**ULTRASONOGRAPHIC FINDINGS**

Andrea Nicastro, DVM,  
Diplomate ACVIM  
(*Small Animal Internal  
Medicine*)

- Urinary bladder debris.
- Gallbladder debris/sludge, non-mucocele.

**INTERPRETATION OF THE FINDINGS & FURTHER RECOMMENDATIONS**

**IMAGING  
PERFORMED BY**

Given the patient's clinical history, Leptospirosis infection is the top differential and continuation of the current therapy is recommended while awaiting Lepto PCR results. If results are inconclusive, consider rechecking Leptospirosis serology in 10-14 days. If all testing proves inconclusive, hepatic tissue sampling (i.e., fine needle aspirate or surgical biopsy) may be warranted. Surgical biopsies are preferred in that they are more likely to represent global organ pathology. If pursued, aerobic and anaerobic bile cultures as well as acquisition of additional hepatic tissue samples for potential copper quantitation are recommended.

Amanda Lacey-Crook

**HOSPITAL NAME**

Rivers Edge Pet  
Medical Center

**REFERRING VET**

Dr. David Gray

**INVOICE**

13333

**DATE**

5/9/22



**PATIENT**

Widget Elliott

**SPECIES**

Canine

**BREED**

Jack Russell Terrier

**SEX**

Female, spayed

**AGE**

6 Yrs. 9 Months

**WEIGHT**

17.2 lbs.

**INTERPRETED BY**

Andrea Nicastro, DVM,  
Diplomate ACVIM  
(Small Animal Internal  
Medicine)

**IMAGING  
PERFORMED BY**

Amanda Lacey-Crook

**HOSPITAL NAME**

Rivers Edge Pet  
Medical Center

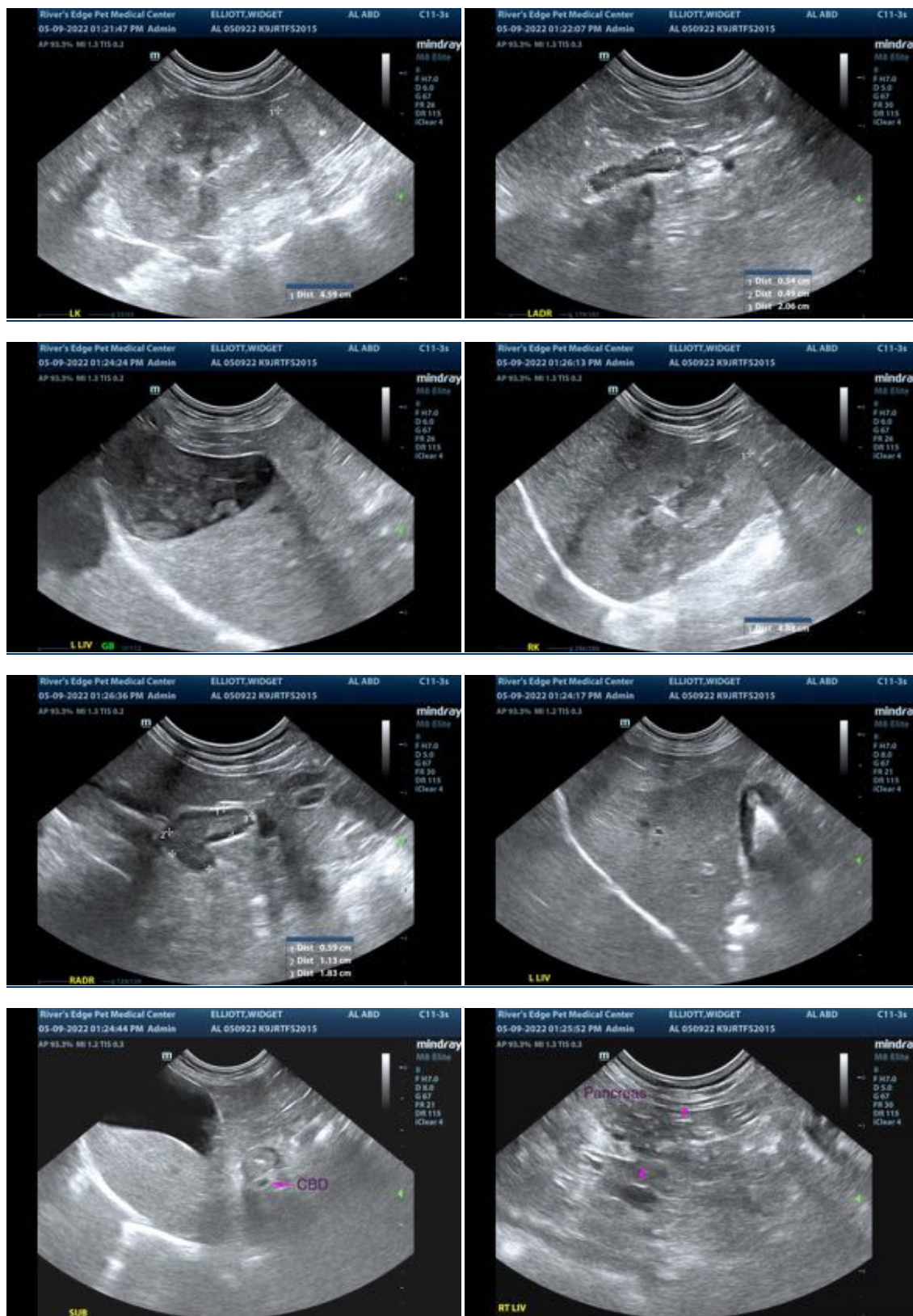
**REFERRING VET**

Dr. David Gray

**INVOICE**

13333

**DATE**  
5/9/22



The information and recommendations provided are based on the images presented by the referring



**PATIENT**

Widget Elliott

veterinarian/sonographer. No evaluation can be communicated regarding pathology that was not visible in the image/video clips provided.

Thank you for this referral. If the clinical or image interpretation does not parallel your findings or if I can be of any further assistance please contact me.

**SPECIES**

Canine

Andrea Nicastro, DVM, Diplomate ACVIM (*Small Animal Internal Medicine*)

**BREED**

Jack Russell Terrier

Andrea.nicastro@sonopath.com

**SEX**

Female, spayed

**AGE**

6 Yrs. 9 Months

**WEIGHT**

17.2 lbs.

**INTERPRETED BY**

Andrea Nicastro, DVM,  
Diplomate ACVIM  
(*Small Animal Internal  
Medicine*)

**IMAGING  
PERFORMED BY**

Amanda Lacey-Crook

**HOSPITAL NAME**

Rivers Edge Pet  
Medical Center

**REFERRING VET**

Dr. David Gray

**INVOICE**

13333

**DATE**

5/9/22