

**DATE PRESENTING CLINICAL SIGNS**

5/9/22

Straining to urinate.

PATIENT

Samson Fee

Current Medications: None.
 Lab Results: Increased liver enzymes 1/10/22.
 Date of Previous IntraPet Ultrasound: No previous.
 Sedation: Not required to complete full diagnostic ultrasound.
 Stat Report: Not requested.
 Imaging Performed By: Rachel Brillhart, RDMS.

SPECIES

Canine

BREED

Golden retriever

SEX

Male, neutered

AGE

4/4/2012

WEIGHT

61 lbs.

ULTRASONOGRAPHIC EXAMINATION OF THE ABDOMEN**Urinary System**

The urinary bladder is moderately distended with anechoic urine. The wall is slightly thickened (up to 0.34 cm) with a subtly irregular mucosal surface. No cystic calculi are observed. The region of the trigone and the visible portion of the proximal urethra are normal.

The prostate is normal in size (1.46 cm in width) and shape. Parenchyma is homogenous. The prostatic urethra appears normal without evidence of dilation or obstruction.

The left kidney is normal size (7.85 cm in length); normal shape and architecture with smooth peripheral margins. There is a normal 1:3 cortex to medulla ratio with minimal loss of corticomedullary distinction. There is no evidence of pyelectasia, nephroliths, infarcts or hydroureter. Renal vasculature is normal.

The right kidney is normal size (8.17 cm in length); normal shape and architecture with smooth peripheral margins. There is a normal 1:3 cortex to medulla ratio with normal corticomedullary distinction. There is no evidence of pyelectasia, nephroliths, infarcts or hydroureter. Renal vasculature is normal.

INTERPRETED BY

Andrea Nicastro, DVM,
 Diplomate ACVIM
 (Small Animal Internal
 Medicine)

Adrenal Glands

The left adrenal gland is mildly enlarged (1.13 cm at cranial pole) (1.09 cm at caudal pole) (3.99 cm in length); normal shape; homogenous parenchyma. The glandular echogenicity and detail are unremarkable. Capsule, cortex, and medullary definition are normal. The phrenicoabdominal vein and surrounding vasculature are normal.

HOSPITAL NAME

Alexander AH

The right adrenal gland is mildly enlarged (1.35 cm at cranial pole) (1.13 cm at caudal pole) (3.29 cm in length) with a normal shape and smooth peripheral contours. A 1.20 x 1.06 cm hyperechoic nodule is observed at the cranial pole. The glandular echogenicity and detail at the caudal pole are unremarkable. The phrenicoabdominal vein and surrounding vasculature are normal.

REFERRING VET

Dr. Alexander

Spleen

The spleen is normal in size (1.09 cm in width at the level of the hilus) with a normal capsular contour. There is appropriate echogenicity and echotexture. A few small myelolipomas are observed in the region of the hilus. Splenic vasculature is normal.

INVOICE

13328

Liver

The liver is enlarged with irregular peripheral contours. Throughout the organ, varying sized heterogeneous, cavitated nodules/masses are observed, the largest measuring >10 cm. One of the masses, which is arising from the left lateral lobe, extends into the caudal abdomen. Hepatic vasculature is of normal volume with no evidence of congestion. The gall bladder lumen is moderately distended. The wall is thin and smooth. A moderate amount of echogenic to mineralized debris is observed within the lumen. The cystic and common bile ducts are normal/not seen.

Gastrointestinal

The gastric lumen is mildly distended with ingesta and soft shadowing material. The gastric wall and pylorus are normal in thickness with a normal layering pattern. The pyloric outflow tract is patent. The small intestinal lumen is not dilated. The small intestinal wall thickness is normal with a normal layering pattern and appropriate mural detail. Discreet masses are not identified. The colonic wall is normal. No obstructive disease is noted.

Pancreas

A portion of the pancreas is obscured by the hepatic pathology. In the visualized portions, no obvious abnormalities are seen.

Free Abdomen

There is no evidence of free fluid. The abdominal lymph nodes are normal/not visible.

Other

A brief echocardiogram reveals no evidence of pericardial effusion or obvious right atrial/auricular mass.

ULTRASONOGRAPHIC FINDINGS

Primary Findings:

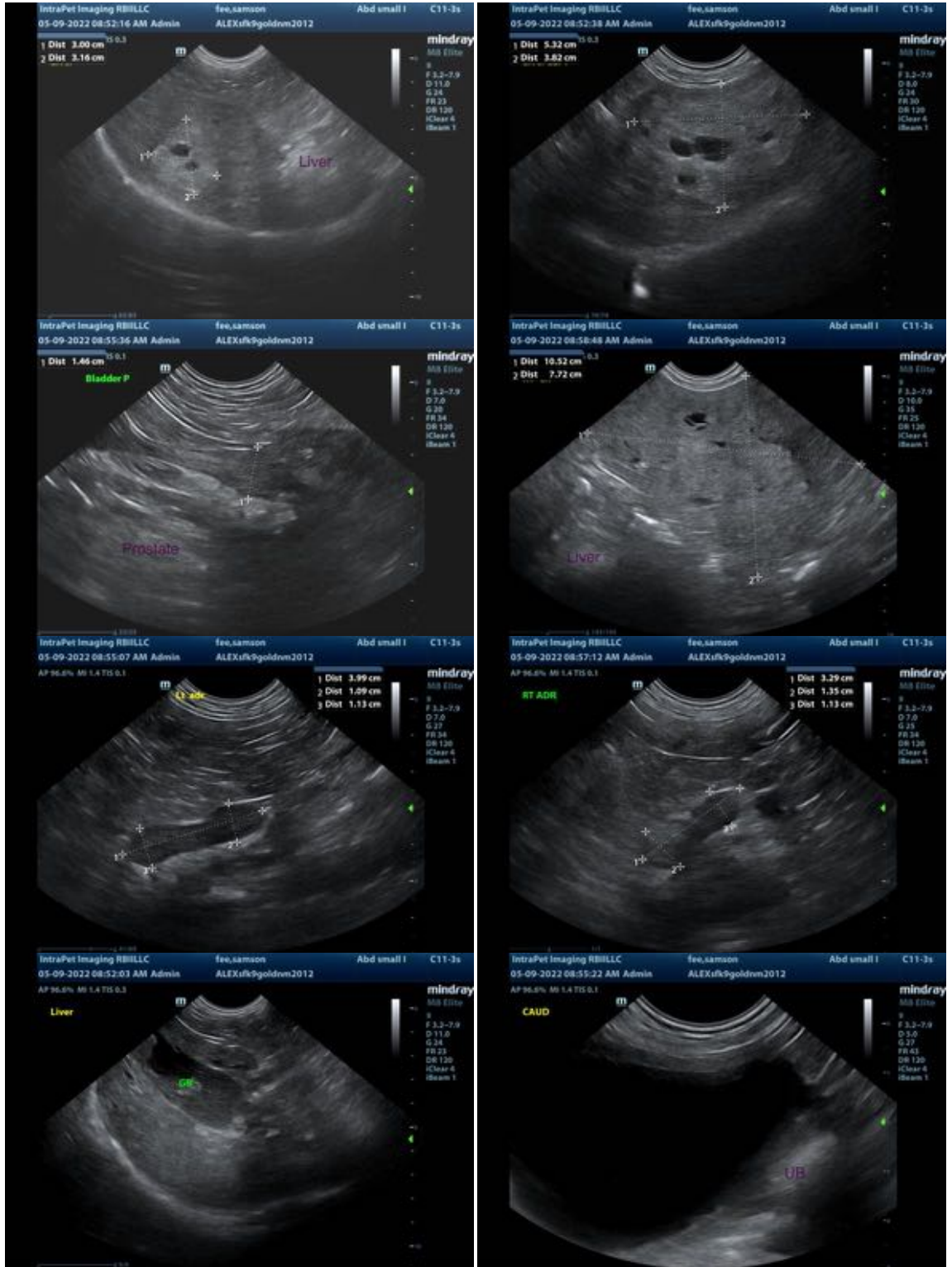
- Diffuse hepatic masses. Neoplasia (i.e., adenocarcinoma, round cell tumor) is considered likely with a low possibility of benign pathology (i.e., multifocal inflammatory disease).

Secondary Findings:

- The mild urinary bladder wall thickening could be consistent with low-grade cystitis.
- Mild left adrenomegaly. The right adrenal nodule trends toward the benign (i.e., nodular hyperplasia). However, an emerging tumor cannot be completely excluded.
- The gastric luminal contents may represent normal ingesta and/or foreign material. There is no obvious evidence of an outflow tract obstruction at the time of the study.

INTERPRETATION OF THE FINDINGS & FURTHER RECOMMENDATIONS

- Three-view thoracic radiographs are recommended to assess for pulmonary metastases.
- Hepatic tissue sampling (i.e., fine needle aspirate or surgical biopsy) can be considered if a definitive diagnosis is desired. Fine needle aspirates may be inconclusive and there is a risk of iatrogenic hemorrhage given the cavitated areas. Therefore, surgical biopsies are preferred if tissue sampling is to take place. Given the diffuse hepatic pathology, however, palliative care should be considered.
- Given the history of stranguria, a urinalysis and urine culture and sensitivity are recommended to assess for infection.



The information and recommendations provided are based on the images presented by the referring

veterinarian. No evaluation can be communicated regarding pathology that was not visible in the image/video clips provided.

Thank you for this referral. If the clinical or image interpretation does not parallel your findings or if I can be of any further assistance please contact me.

Andrea Nicastro, DVM, Diplomate ACVIM (*Small Animal Internal Medicine*)
Andrea.nicastro@sonopath.com