

**PATIENT PRESENTING CLINICAL SIGNS**

**Molly Smith**  
Was given Dexdom/Torb for scan. Was fasted. Owners have noticed increased drinking and has been urinating in the house. Once right in front of owners. Does not seem to be asking to go out more frequently. Owner noticed some shaking in the back legs also. Has been on Metacam. Slightly overweight. Started leaking urine as sedation was given and continued to leak throughout the scan. Significant darkly stained fur around vulva.

**Canine**  
Abnormal PE/Chem/CBC/UA Results: 4DX negative U/A - pH 6.5 sp. Gravity - 1.025 Rest NSF

**BREED ULTRASONOGRAPHIC EXAMINATION OF THE ABDOMEN**

Old English Sheepdog

**Urinary System**

The urinary bladder and pelvic urethra are normal in thickness and the mucosal surface is smooth. The bladder lumen is mildly to moderately distended with anechoic urine. A small amount of suspended echogenic debris is observed within the lumen. Ureteral papillae and visualized portion of the proximal urethra, visible to a depth of 2 cm, are normal. The region of the trigone is normal.

**SEX**

Spayed Female

The left kidney presented normal size (4.71 cm in length); normal shape and architecture with smooth peripheral margins. There is a normal 1:3 cortex to medulla ratio with normal corticomedullary distinction. There is no evidence of pyelectasia, nephroliths, infarcts or hydronephrosis. Renal vasculature is normal.

**AGE**

3 Years

**WEIGHT**

30 kg

The right kidney presented normal size (6.48 cm in length); normal shape and architecture with smooth peripheral margins. There is a normal 1:3 cortex to medulla ratio with normal corticomedullary distinction. There is no evidence of pyelectasia, nephroliths, infarcts or hydronephrosis. Renal vasculature is normal.

**INTERPRETED BY**

Andrea Nicastro, DMV,  
Diplomate DACVIM  
(Small Animal  
Internal Medicine)

**Adrenal Glands**

The left adrenal gland is normal size (0.40 cm at cranial pole) (0.47 cm at caudal pole) (1.81 cm in length); normal shape; homogenous parenchyma. The glandular echogenicity and detail are unremarkable. Capsule, cortex, and medullary definition are normal. The phrenicoabdominal vein and surrounding vasculature are normal.

**IMAGING PERFORMED BY**

Crystal Hill

The right adrenal gland is normal size (1.01 cm at cranial pole) (0.41 cm at caudal pole) (1.59 cm in length); normal shape; homogenous parenchyma. The glandular echogenicity and detail are unremarkable. Capsule, cortex, and medullary definition are normal. The phrenicoabdominal vein and surrounding vasculature are normal.

**HOSPITAL NAME**

Grand River VH

**Spleen**

The spleen is normal in size (1.84 cm) with a normal capsular contour. There is appropriate echogenicity and echotexture. No focal lesions are observed. Splenic vasculature is normal.

**REFERRING VET**

Dr. Day/Robinson

**Liver**

The liver is subjectively normal in size with normal contours and structure. There is appropriate echogenicity and echotexture. No overt structural evidence of inflammatory, infiltrative or regenerative pathology is evident. Vascular and biliary tracts are of normal volume with no evidence of congestion. No pathological hepatic lymphadenopathy observed.

**INVOICE**

37532

**DATE**

5/9/22

The gall bladder lumen is moderately distended. The wall is thin and smooth. Luminal contents are anechoic. The cystic and common bile ducts are normal.



**PATIENT** *Gastrointestinal*

Molly Smith The stomach and intestine are free of stasis and exhibit normal peristaltic activity. The gastric lumen is not distended. The gastric wall and pylorus are normal in thickness with a normal layering pattern. The small intestinal lumen is not dilated. The small intestinal wall thickness is normal (xxx cm) with a normal layering pattern and appropriate mural detail. Discreet masses are not identified. The colonic wall is normal. No obstructive or overt infiltrative disease is noted.

**SPECIES**

Canine

**Pancreas**

The region of the pancreas is isoechoic relative to surrounding omental fat. No obvious parenchymal abnormalities are observed. There is no evidence of regional inflammation or effusion.

**BREED**

Old English Sheepdog

**Free Abdomen**

**SEX**

The peritoneal cavity is normal. There is no evidence of inflammation or effusion.

Spayed Female

**AGE**

A few enlarged, hypoechoic, rounded lymph nodes are observed in the left cranial to mid abdomen, the largest measuring 3.02 cm in length. At least one enlarged lymph node is also observed in the right cranial quadrant, measuring 2.76 cm in length.

3 Years

**ULTRASONOGRAPHIC FINDINGS**

**WEIGHT**

30 kg

- The lymphadenopathy could be consistent with infiltrative neoplasia (i.e., round cell tumor), lymphadenitis, or lymphoid hyperplasia.
- The urinary bladder debris could be consistent with cells, crystals, and/or exfoliated material

**INTERPRETED BY**

Andrea Nicastro, DMV,  
Diplomate DACVIM  
(Small Animal  
Internal Medicine)

**INTERPRETATION OF THE FINDINGS & FURTHER RECOMMENDATIONS**

**IMAGING PERFORMED BY**

Crystal Hill

- Baseline lab work including a CBC and Chemistry panel with electrolytes is recommended, if not already performed.
- Thoracic radiographs should be considered to assess for lymphadenopathy in the chest.
- If accessible, fine needle aspirate of the abdominal lymph nodes is recommended (if clotting status is appropriate).
- Given the clinical signs, consider a urine culture and sensitivity to assess for occult pyelonephritis.

**HOSPITAL NAME**

Grand River VH

**REFERRING VET**

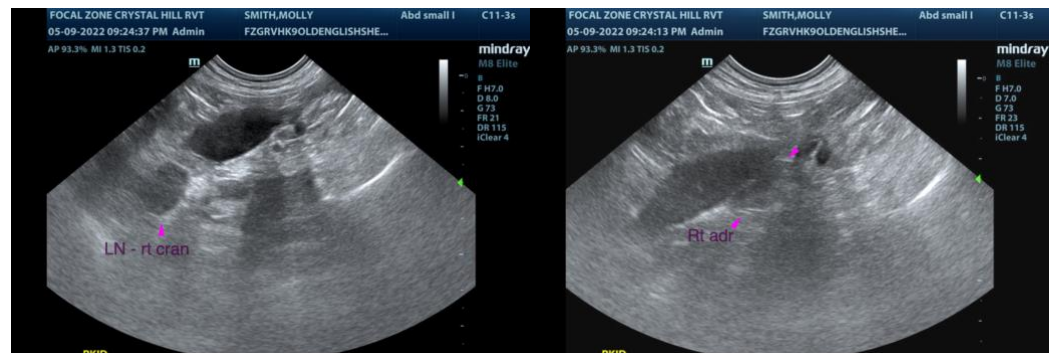
Dr. Day/Robinson

**INVOICE**

37532

**DATE**

5/9/22





**PATIENT**

Molly Smith

**SPECIES**

Canine

**BREED**

Old English Sheepdog

**SEX**

Spayed Female

**AGE**

3 Years

**WEIGHT**

30 kg

**INTERPRETED BY**

Andrea Nicastro, DMV,  
Diplomate DACVIM  
(Small Animal  
Internal Medicine)

**IMAGING  
PERFORMED BY**

Crystal Hill

**HOSPITAL NAME**

Grand River VH

**REFERRING VET**

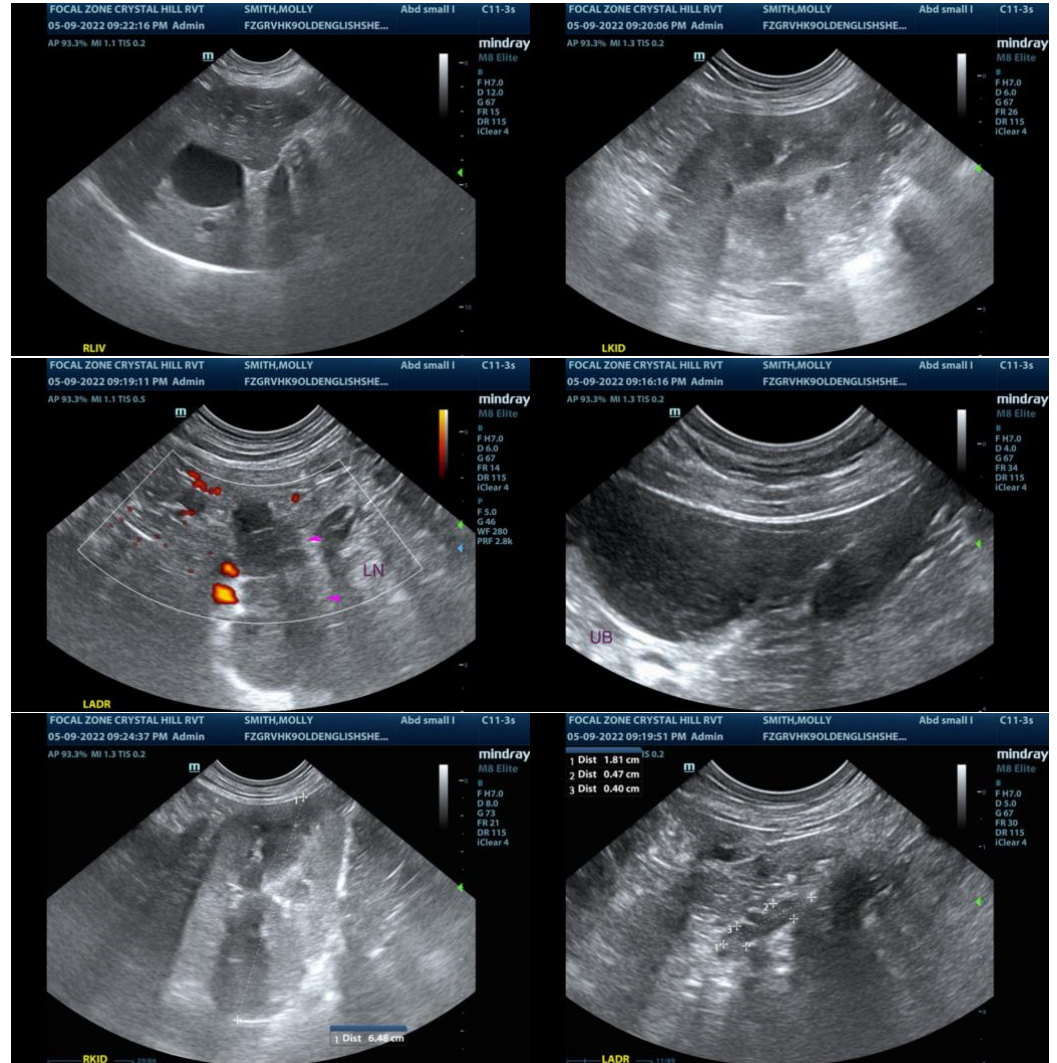
Dr. Day/Robinson

**INVOICE**

37532

**DATE**

5/9/22



The information and recommendations provided are based on the images presented by the referring veterinarian/sonographer. No evaluation can be communicated regarding pathology that was not visible in the image/video clips provided.

Thank you for this referral. If the clinical or image interpretation does not parallel your findings or if I can be of any further assistance please contact me.

**Andrea Nicastro, DVM, Diplomate DACVIM (Small Animal Internal Medicine)**  
info@SonoPath.com