

**DATE**

5/9/22

PRESENTING CLINICAL SIGNS

P presented for PU/PD 5/2/22. p has a previous history of uroliths. Radiograph did not show any uroliths. BW showed elevated liver enzymes. UA showed 2+ protein, no other significant findings.

PATIENT

Bella Piscotty

Current Medications: None listed.

Lab Results: Urine protein: creatinine 1 (<0.5), AST 96 (15-66), ALT 316 (12-118), ALP 756 (5-131), chol 404 (92-324), TG 1012 (29-291).

Date of Previous IntraPet Ultrasound: No previous.

Sedation: Not required to complete full diagnostic ultrasound.

Stat Report: Not requested.

SPECIES

Canine

Imaging Performed By: Andi Parkinson, RDMS.

BREED

Schnauzer

ULTRASONOGRAPHIC EXAMINATION OF THE ABDOMEN**Urinary System**

The urinary bladder, trigone, and pelvic urethra are normal in thickness and the mucosal surface is smooth.

The bladder lumen is mildly to moderately distended. A small amount of gravity dependent mineralized sand is observed along with a small amount of suspended echogenic debris. No distinct calculi are observed. The region of the trigone and the visible portion of the proximal urethra are normal.

AGE

7/30/2010

The left kidney is normal size (4.77 cm in length); normal shape and architecture with smooth peripheral margins. There is a normal 1:3 cortex to medulla ratio with moderate loss of corticomedullary distinction. Several non-obstructive nephroliths are visualized. There is no evidence of pyelectasia, nephroliths, infarcts or hydroureter.

WEIGHT

22.8 lbs.

The right kidney is normal size (5.34 cm in length); normal shape and architecture with smooth peripheral margins. There is a normal 1:3 cortex to medulla ratio with moderate loss of corticomedullary distinction. Several non-obstructive nephroliths are visualized. There is no evidence of pyelectasia, nephroliths, infarcts or hydroureter.

INTERPRETED BY

Andrea Nicastro, DVM,
 Diplomate ACVIM
 (Small Animal Internal
 Medicine)

Adrenal Glands

The left adrenal gland is normal size (0.41 cm at cranial pole) (0.58 cm at caudal pole) (2.34 cm in length); normal shape; homogenous parenchyma. The glandular echogenicity and detail are unremarkable. Capsule, cortex, and medullary definition are normal. The phrenicoabdominal vein and surrounding vasculature are normal.

HOSPITAL NAME

Charm City VH

The right adrenal gland is normal size (0.51 cm at cranial pole) (0.53 cm at caudal pole) (2.31 cm in length); normal shape; homogenous parenchyma. The glandular echogenicity and detail are unremarkable. Capsule, cortex, and medullary definition are normal. The phrenicoabdominal vein and surrounding vasculature are normal.

REFERRING VET

Dr. Karbonik

Spleen

The spleen is normal in size (1.93 cm in width at the level of the hilus) with a normal capsular contour. There is appropriate echogenicity and echotexture. No focal lesions are observed. Splenic vasculature is normal.

INVOICE

13324

Liver

The liver is subjectively enlarged with slightly swollen peripheral contours. The parenchyma is isoechoic relative to the spleen and diffusely homogeneous in appearance. No distinct focal lesions are observed. Vascular and biliary tracts are of normal volume with no evidence of congestion. The gall bladder lumen is moderately distended. The wall is thin and smooth. A small amount of aggregated echogenic partially dependent debris is observed within the lumen. The cystic and common bile ducts are normal/not seen. The portal vein: caudal vena cava ratio is approximately 1:1. The gall bladder lumen is moderately

distended. The wall is thin and smooth. A small amount of suspended echogenic debris is observed within the lumen. The cystic and common bile ducts are normal/not seen.

Gastrointestinal

The gastric lumen is moderately distended with ingesta. The gastric wall and pylorus are normal in thickness with a normal layering pattern. The pyloric outflow tract is patent. The small intestinal lumen is not dilated. The small intestinal wall thickness is normal with a normal layering pattern and appropriate mural detail. Discreet masses are not identified. The colonic wall is normal. No obstructive disease is noted.

Pancreas

The base and right limb of the pancreas are visible with normal curvilinear peripheral contours. The parenchyma is largely isoechoic relative to surrounding omental fat and slightly mottled in appearance. The pancreatic duct is visible but not overtly dilated. There is no evidence of peripancreatic inflammation or effusion.

Free Abdomen

The peritoneal cavity is normal. There is no evidence of inflammation or effusion. The abdominal lymph nodes are normal/not visible.

ULTRASONOGRAPHIC FINDINGS

Primary Findings:

- The hepatic parenchymal changes are non-specific and may be secondary to a benign process (i.e., vacuolar hepatopathy, regenerative nodular hyperplasia and/or age-related remodeling). Inflammatory disease cannot be completely excluded, particularly given the elevated ALT. Infiltrative neoplasia is possible but considered less likely.

Secondary Findings:

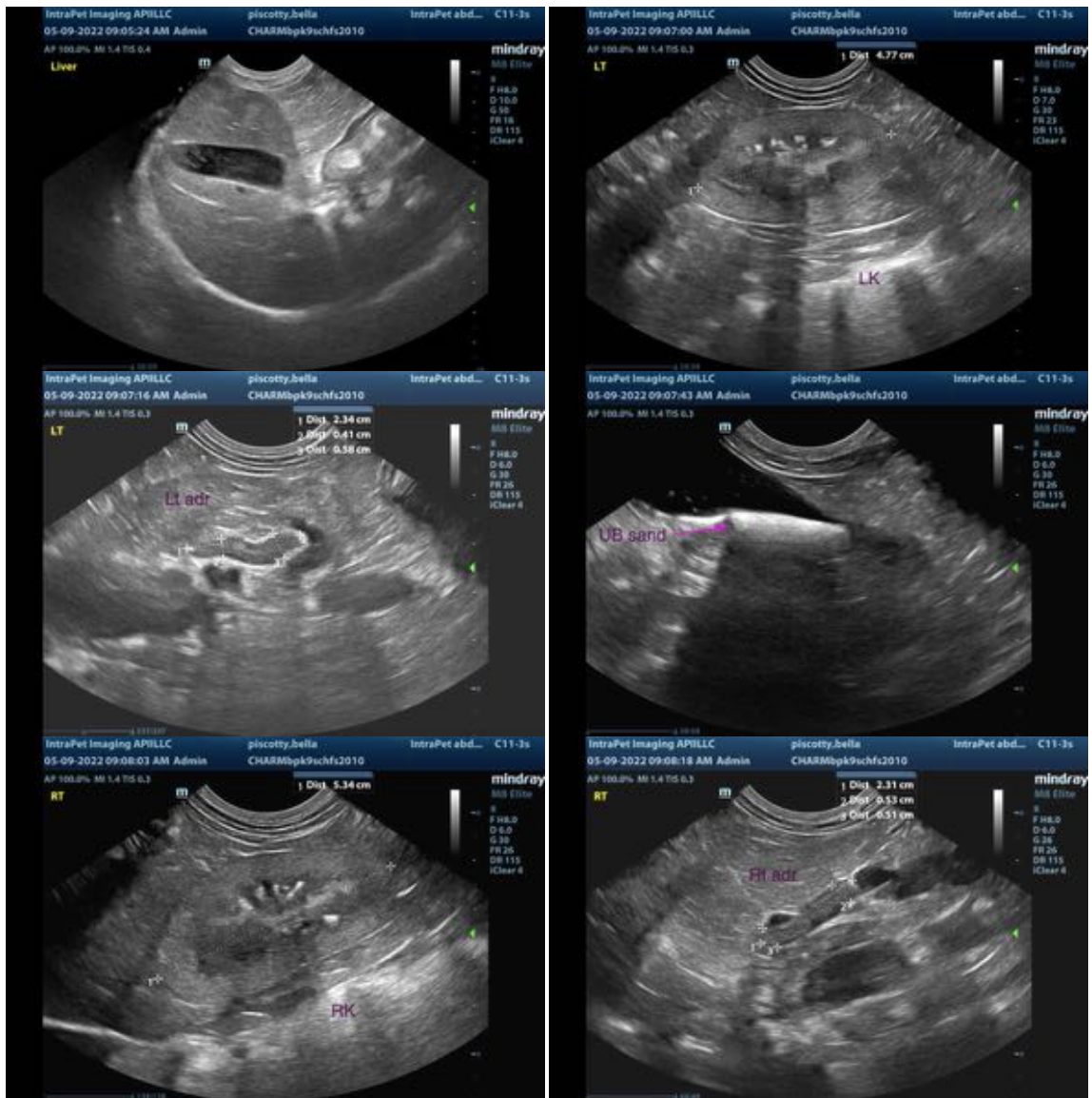
- Bilateral chronic renal changes with non-obstructive nephrolithiasis.
- Urinary bladder sand and debris.
- Age-related pancreatic remodeling.

*An obvious cause for the patient's clinical signs is not identified in this study. Considerations include primary hepatic disease, Cushing's disease, occult pyelonephritis, diabetes insipidus, other.

INTERPRETATION OF THE FINDINGS & FURTHER RECOMMENDATIONS

- A urinalysis/urine specific gravity is recommended to confirm isosthenuria, if not already performed.
- Other diagnostic considerations include the following:
 1. Urine culture and sensitivity
 2. Pre- and post-prandial serum bile acids to assess hepatic function
 3. Leptospirosis testing (i.e., blood and urine PCR, serology)

4. Depending on the results of the above diagnostics, further testing for Cushing's disease (i.e., low-dose dexamethasone suppression test) may be warranted. If all tests are inconclusive and the patient is hyposthenuric or isosthenuric, consider a DDAVP trial +/- a modified water deprivation test.
- Given the elevated UPC, consider a baseline blood pressure measurement and initiation of an angiotensin receptor blocker and omega 3 fatty acids.
 - Given the patient's age, thoracic radiographs (three-view) are recommended to evaluate cardiopulmonary status.



The information and recommendations provided are based on the images presented by the referring

veterinarian. No evaluation can be communicated regarding pathology that was not visible in the image/video clips provided.

Thank you for this referral. If the clinical or image interpretation does not parallel your findings or if I can be of any further assistance please contact me.

Andrea Nicastro, DVM, Diplomate ACVIM (*Small Animal Internal Medicine*)
Andrea.nicastro@sonopath.com