



**PATIENT**

Oliver Helfrick

**SPECIES**

Feline

**BREED**

DSH

**SEX**

Neutered Male

**AGE**

15 years

**WEIGHT**

3.2 kg

**INTERPRETED BY**

Andrea Nicastro, DVM,  
Diplomate ACVIM (*Small  
Animal Internal Medicine*)

**IMAGING  
PERFORMED BY**

Erin Wicks

**HOSPITAL NAME**

Shores Veterinary  
Emerg Ctr

**REFERRING VET**

Dr Law

**INVOICE**

12932

**DATE**

5.4.23

**PRESENTING CLINICAL SIGNS**

History: Presented at our hospital for AUS. Started in March with vomiting and losing weight. Seen here and T4 was high, started thyroid medicine, started doing much better. Now last Friday started vomiting, took to rdvm and gave Cerenia and SQF, backed down the thyroid meds, has since been eating but vomits every time. Rec AUS. Previous Health Concerns: Hyperthyroid Current Medications: Methimazole Appetite/When did they eat last: 430am

Abnormal PE/Chem/CBC/UA Results: 3/20/23 cbc: mono 0.04; epoc: po2 83.4 O2 94.6 tcO2 14.5 chl 130 bun 37; chem: bun 36.6 ip 6.6 alt 164; T4 >8 high; Abdominal x-rays: mixed gas, fluid filled intestine; colon displaced to right side of abdomen on VD (possible mass effect cranial left abdomen); no obvious masses visible but less detail visible of cranial abdomen structures Rdvm Rad notes: enlarged wide heart on V/D view, abnormal positioning of colon on V/D RT side vs LF side - gas filled, decreased detail of stomach - obscured with liver or thickened wall? Rec AUS to see more detail of stomach/liver.

**ULTRASONOGRAPHIC EXAMINATION OF THE ABDOMEN**

**Urinary System**

The urinary bladder wall is normal in thickness and the mucosal surface is smooth. The bladder is moderately distended. Luminal contents are anechoic. No cystic calculi are observed. The region of the trigone is normal.

The left kidney is normal in size (3.69 cm in length) with a normal shape and smooth peripheral contours. The cortex is thickened and isoechoic relative to the spleen with mild to moderate loss of corticomedullary distinction. A hyperechoic medullary band is observed at the corticomedullary junction. Hyperechoic shadowing diverticular foci are visualized. Trace pyelectasia is present. There is no evidence of infarcts or hydroureter. Renal vasculature is normal.

The right kidney is normal in size (3.58 cm in length) with a normal shape and smooth peripheral contours. The cortex is thickened and isoechoic relative to the spleen with mild to moderate loss of corticomedullary distinction. A hyperechoic medullary band is observed at the corticomedullary junction. A 0.39 cm cortical cyst is observed at the medial aspect. Hyperechoic shadowing diverticular foci are visualized. Mild pyelectasia (0.22 cm in the longitudinal plane) is present. There is no evidence of infarcts or hydroureter. Renal vasculature is normal.

**Adrenal Glands**

The region of the adrenal glands is evaluated. No obvious pathology is observed in this region.

**Spleen**

The spleen is normal in size (0.77 cm in width at the level of the hilus) with a normal capsular contour. There is appropriate echogenicity and echotexture. No focal lesions are observed. Splenic vasculature is normal.

**Liver**

The liver is subjectively normal in size with normal curvilinear peripheral contours. The parenchyma is hypoechoic relative to the spleen. A 1.00 cm cystic structure containing echogenic debris is observed near the diaphragm. The remaining parenchyma is homogenous. Hepatic vasculature and intrahepatic biliary tracts are of normal volume with no evidence of congestion. The portal vein to caudal vena cava ratio is approximately 1: 1.

The gall bladder is of normal contours and contains some dependent echogenic debris. The wall is normal in thickness. No choleliths are observed. The cystic and common bile ducts are normal.



**PATIENT**

Oliver Helfrick

**SPECIES**

Feline

**BREED**

DSH

**SEX**

Neutered Male

**AGE**

15 years

**WEIGHT**

3.2 kg

**INTERPRETED BY**

Andrea Nicastro, DVM,  
Diplomate ACVIM (*Small  
Animal Internal Medicine*)

**IMAGING  
PERFORMED BY**

Erin Wicks

**HOSPITAL NAME**

Shores Veterinary  
Emerg Ctr

**REFERRING VET**

Dr Law

**INVOICE**

12932

**DATE**

5.4.23

**Gastrointestinal**

The gastric lumen is not distended. The gastric wall and pylorus are normal in thickness with a normal layering pattern. The pyloric outflow tract is patent. The small intestinal lumen is not dilated. The small intestinal wall is diffusely thickened (up to 0.41 cm) with apparent retention of the normal layering pattern. There is disruption in the normal 1:3 muscularis: mucosal ratio with a > 1:1 ratio in several segments. The submucosal layer also appears thickened. Discreet masses are not identified. The ileocecolic junction and colonic wall are normal. There is no obvious evidence of an obstructive pattern.

**Pancreas**

The pancreas is diffusely prominent in size with minimal deviation from the normal peripheral contours. The parenchyma is slightly hypoechoic relative to surrounding omental fat. No focal lesions are observed. The pancreatic duct is mildly dilated (0.28 cm in diameter).

**Free Abdomen**

The peritoneal cavity is normal. There is no evidence of inflammation or effusion. The abdominal lymph nodes are normal/not visible.

**ULTRASONOGRAPHIC FINDINGS**

**Primary Findings**

- Bowel pattern consistent with inflammatory bowel disease with some potential for emerging lymphoma.
- The pancreatic changes are suggestive of mild chronic pancreatitis.

**Secondary Findings**

- Bilateral chronic nephropathy with subtle dystrophic mineralization and pyelectasia
- The hepatic cyst trends toward the benign, with a low possibility an emerging vascular tumor.

**INTERPRETATION OF THE FINDINGS & FURTHER RECOMMENDATIONS**

- Regarding the bowel changes, consider the following:
  1. Fecal evaluation for ova and Giardia
  2. GI panel including serum cobalamin and folate, TLI and PLI
  3. Initiation of a probiotic may prove beneficial.
  4. Also consider transitioning to a hydrolyzed protein or limited antigen diet.
  5. Ultimately, Gi biopsies (i.e., endoscopic or surgical) may be necessary to get a definitive diagnosis.
  6. Regulation of the patient's hyperthyroidism is also recommended, as this may help to reduce the frequency of vomiting.
- Given the suspicion for cardiomegaly, consider an echogenic with a baseline blood pressure measurement +/- ECG.



**PATIENT**

Oliver Helfrick

**SPECIES**

Feline

**BREED**

DSH

**SEX**

Neutered Male

**AGE**

15 years

**WEIGHT**

3.2 kg

**INTERPRETED BY**

Andrea Nicastro, DVM,  
Diplomate ACVIM (*Small Animal Internal Medicine*)

**IMAGING PERFORMED BY**

Erin Wicks

**HOSPITAL NAME**

Shores Veterinary  
Emerg Ctr

**REFERRING VET**

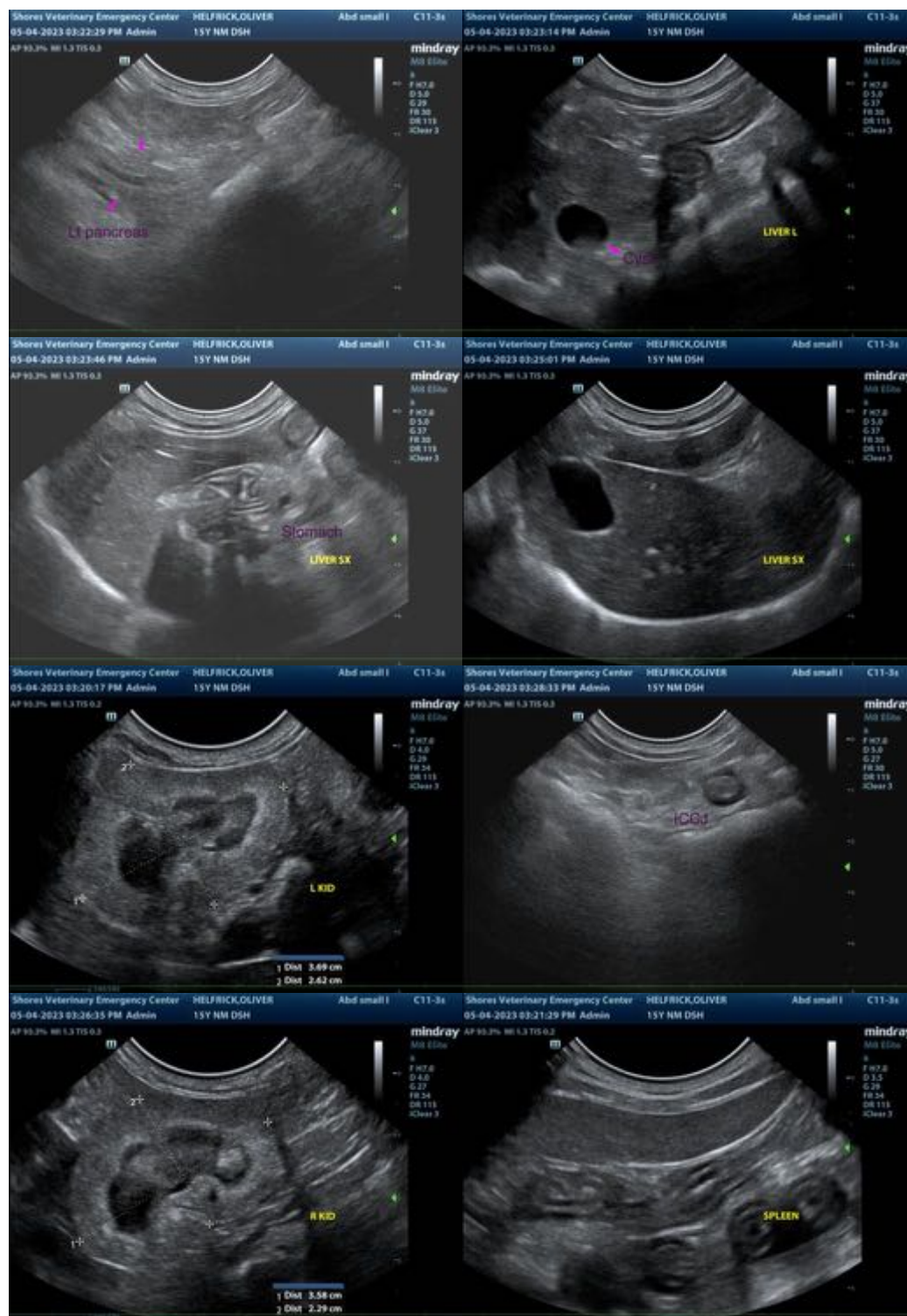
Dr Law

**INVOICE**

12932

**DATE**

5.4.23



The information and recommendations provided are based on the images presented by the referring veterinarian/sonographer. No evaluation can be communicated regarding pathology that was not visible in the image/video clips provided.



**PATIENT**

Oliver Helfrick

Thank you for this referral. If the clinical or image interpretation does not parallel your findings or if I can be of any further assistance, please contact me.

**SPECIES**

Feline

**Andrea Nicastro, MPH, DVM, Diplomate DACVIM (Small Animal Internal Medicine)**  
[info@SonoPath.com](mailto:info@SonoPath.com)

**BREED**

DSH

**SEX**

Neutered Male

**AGE**

15 years

**WEIGHT**

3.2 kg

**INTERPRETED BY**

Andrea Nicastro, DVM,  
Diplomate ACVIM (*Small  
Animal Internal Medicine*)

**IMAGING  
PERFORMED BY**

Erin Wicks

**HOSPITAL NAME**

Shores Veterinary  
Emerg Ctr

**REFERRING VET**

Dr Law

**INVOICE**

12932

**DATE**

5.4.23