**DATE PRESENTING CLINICAL SIGNS**

5/3/22

Patient presented for evaluation of suspect Cushing disease. He presented to another hospital on 4/4/22 with PU/PD. Bloodwork at that time then lead to doing an ACTH stim which suggested doing a low dose dexamethasone suppression test and ultimately a high dose dexamethasone suppression test- both of which were inconclusive (bloodwork summarized below). On presentation here on 4/26/22, patient was potbellied in appearance, was still PU/PD at home and is now panting and having some nasal sounds occasionally when breathing. No abnormalities on thoracic exam or elsewhere on physical exam other than a few fatty masses and being over conditioned. Up to date on vaccines. UA done at his most recent appointment revealed suspect bacteria and he is currently being treated with clavamox- 125mg PO BID.

**SPECIES**

Canine

Current Medications: Clavamox 125mg- 1 PO BID x2 weeks (beginning 4/26/22) for UTI.

**BREED**

Bichon Frise mix

Lab Results: 4/4/22: CBC- WNL. CHEM- elevated ALT (202) and ALKP (494), hypochloremia (102), elevated cholesterol (868) and triglycerides (759), T4/Free T4- WNL, HW Ag- WNL. 4/7/22: ACTH stim- post 25.8 (HIGH- >20 suggestive of HAC). 4/13/22: Low Dose Dexamethasone Suppression Test- 830am-3.1, 430pm-2.1 (HIGH)- non conclusive. 4/21/22: High Dose Dexamethasone Suppression Test- 9:30am- 4.7, 3:30pm-15.5 (HIGH), 5:30pm- 16.7 (HIGH)- does not differentiate between pituitary vs adrenal dependent. 4/26/22: UA: vetlab sedivue free catch, usg 1.009, pH 8.0, +leukocytes, +protein, +blood, 7wbc/hfp, 5rbc/hpf, suspect rods and cocci present- confirmed with images

**SEX**

Male, neutered

Date of Previous IntraPet Ultrasound: No previous.

Sedation: Not required to complete full diagnostic ultrasound.

Stat Report: Not requested.

**AGE**

1/23/2014

Imaging Performed By: Andi Parkinson, RDMS.

**WEIGHT**

21 lbs.

**ULTRASONOGRAPHIC EXAMINATION OF THE ABDOMEN****Urinary System**

The urinary bladder, trigone, and pelvic urethra are normal in thickness and the mucosal surface is smooth. The bladder lumen is mildly distended with anechoic urine. No masses, inflammatory changes or calculi are observed. Ureteral papillae and visualized portion of the proximal urethra, visible to a depth of 1-2 cm, are normal.

**INTERPRETED BY**

Andrea Nicastro, DVM,  
Diplomate ACVIM  
(Small Animal Internal  
Medicine)

The prostate is normal in size (0.88 cm in width) and shape. Parenchyma is homogenous. The prostatic urethra appears normal without evidence of dilation or obstruction.

**HOSPITAL NAME**

Perry Hall AH

One still image and one partial video clip of the left kidney are available for interpretation. The left kidney is normal in size (4.93 cm in length) with a normal shape, smooth peripheral margins and normal internal architecture. There is mild loss of corticomedullary distinction. Several hyperechoic shadowing diverticular foci are observed. There is no evidence of pyelectasia, infarcts or hydronephrosis. Renal vasculature is normal.

**REFERRING VET**

Dr. Breidenbaugh

The right kidney is normal size (5.05 cm in length); normal shape and architecture with smooth peripheral margins. There is a normal 1:3 cortex to medulla ratio with mild loss of corticomedullary distinction. There is no evidence of pyelectasia, nephroliths, infarcts or hydronephrosis.

**INVOICE**

13306

**Adrenal Glands**

The left adrenal gland is borderline enlarged (0.62 cm at cranial pole) (0.74 cm at caudal pole) (2.50 cm in length); normal shape; homogenous parenchyma. The glandular echogenicity and detail are unremarkable. Capsule, cortex, and medullary definition are normal. The phrenicoabdominal vein and surrounding vasculature are normal.

The right adrenal gland is borderline enlarged (0.47 cm at cranial pole) (0.75 cm at caudal pole) (2.24 cm in length); normal shape; homogenous parenchyma. The glandular echogenicity and detail are unremarkable.

Capsule, cortex, and medullary definition are normal. The phrenicoabdominal vein and surrounding vasculature are normal.

### *Spleen*

The spleen is normal in size (xxx cm in width at the level of the hilus) with a normal capsular contour. There is appropriate echogenicity and echotexture. A 1.29 x 0.81 cm irregular hypoechoic to slightly heterogeneous nodule is observed approximately mid-spleen. The nodule contains a few tiny ill-defined anechoic areas. Splenic vasculature is normal.

### *Liver*

The liver is subjectively enlarged with slightly swollen peripheral contours. The parenchyma is hyperechoic relative to the spleen and slightly heterogeneous in appearance. No distinct focal lesions are observed. Vascular and biliary tracts are of normal volume with no evidence of congestion. The gall bladder lumen is moderately distended. The wall is thin and smooth. The gall bladder lumen is moderately distended. The wall is thin and smooth. A moderate amount of echogenic debris is observed within the lumen, some of which is partially dependent and some of which is suspended. The cystic and common bile ducts are normal/not seen.

### *Gastrointestinal*

The stomach and intestine are free of stasis and exhibit normal peristaltic activity. The gastric lumen is mildly distended with ingesta. The gastric wall and pylorus are normal in thickness with a normal layering pattern. The pyloric outflow tract is patent. The small intestinal lumen is not dilated. The small intestinal wall thickness is normal with a normal layering pattern and appropriate mural detail. Discreet masses are not identified. The colonic wall is normal. No obstructive disease is noted.

### *Pancreas*

The right limb and base of the pancreas are prominent to enlarged with slightly irregular peripheral contours. The parenchyma is hyperechoic relative to surrounding omental fat and mottled in appearance. No distinct focal lesions are observed. The pancreatic duct is not overtly dilated. There is no evidence of peripancreatic effusion.

### *Free Abdomen*

No free fluid is observed. 1-2 prominent cystic lymph nodes are observed in the right cranial quadrant, the largest measuring 1.96 cm in length. Surrounding mesentery is hyperechoic.

### *Other*

A brief echocardiogram reveals no obvious evidence of pericardial effusion.

## **ULTRASONOGRAPHIC FINDINGS**

### **Primary Findings:**

- Borderline bilateral adrenomegaly. This finding may be secondary to hyperplastic change (i.e., due to pituitary dependent hyperadrenocorticism). Alternatively, this may be a normal variant for this patient.
- The hepatic parenchymal changes could be consistent with vacuolar hepatopathy, regenerative nodular hyperplasia, inflammatory disease or less likely, infiltrative neoplasia (i.e., lymphoma).

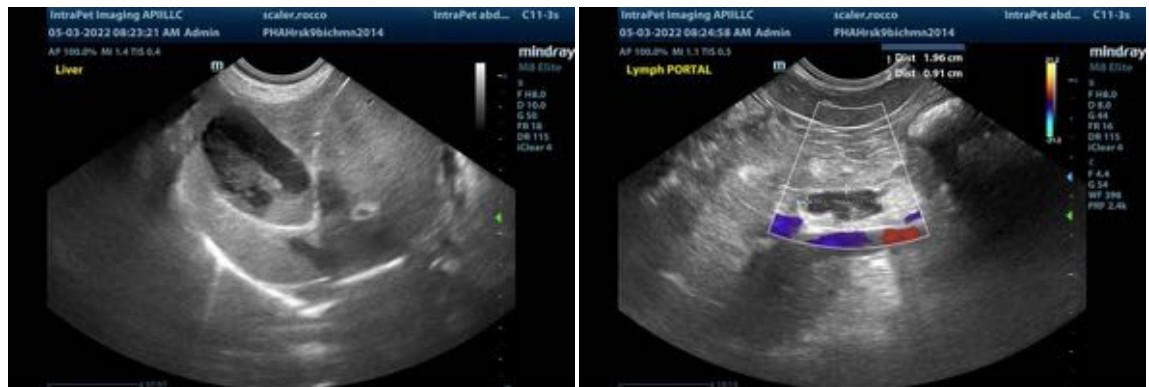
### **Secondary Findings:**

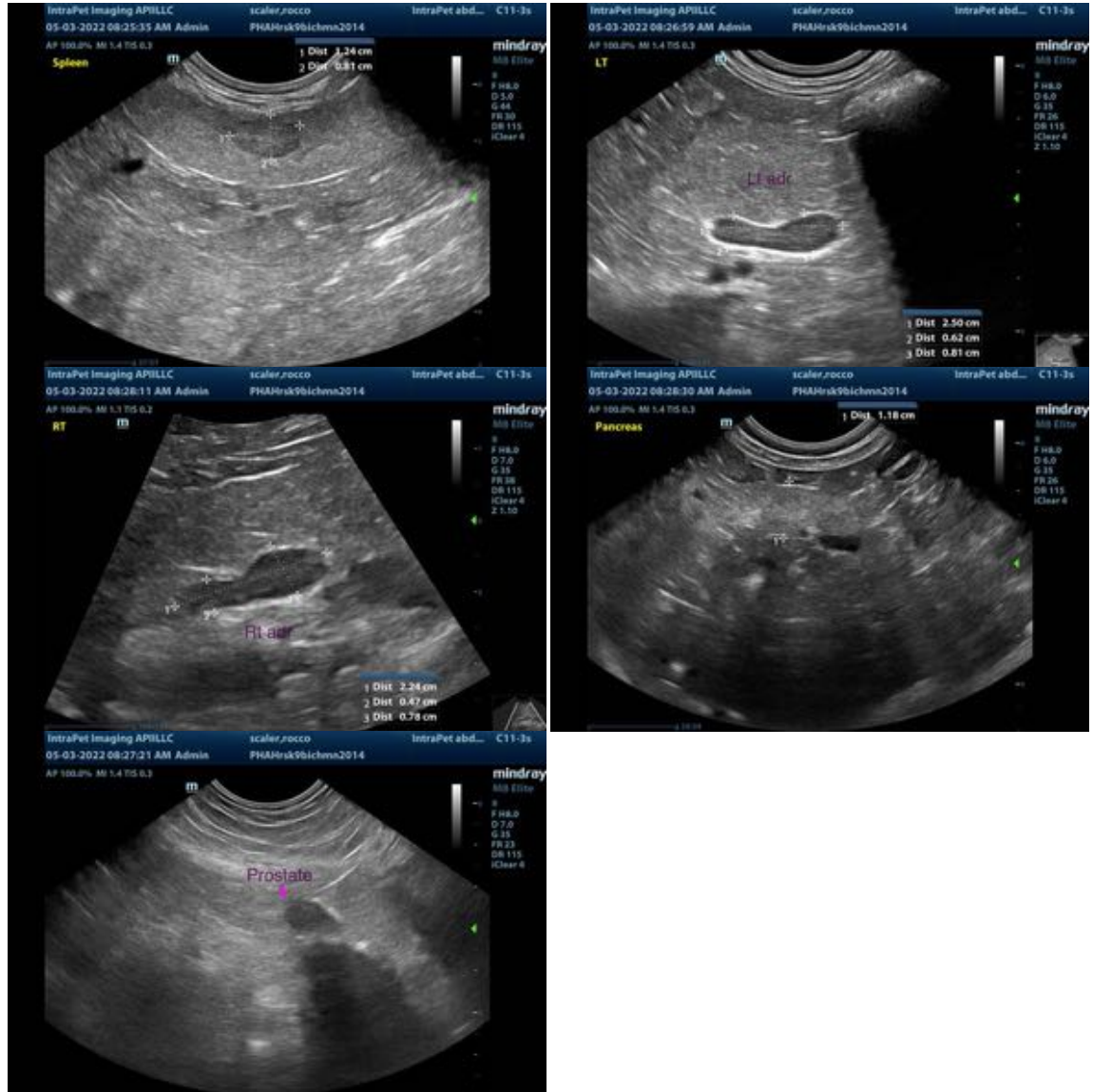
- Bilateral, chronic age-related renal changes.

- The splenic nodule could be consistent with a benign process (i.e., focus of lymphoid hyperplasia or extramedullary hematopoiesis). However, an emerging neoplastic process cannot be completely excluded.
- The pancreatic changes are most consistent with age-related parenchymal remodeling, potentially secondary to a prior inflammatory episode, early fibrosis or chronic pancreatitis.
- The significance of the cystic lymph nodes in the right cranial quadrant is unclear. However, they are likely benign and/or reactive with a low possibility of infiltrative neoplasia.

### INTERPRETATION OF THE FINDINGS & FURTHER RECOMMENDATIONS

- Given that it is unclear whether this patient has Cushing's disease or primary hepatic disease, consider pre- and post-prandial serum bile acids. If significantly elevated, a primary hepatopathy would be favored. A fine needle aspirate of the liver can also be considered, if clotting status is appropriate. However, cytologic evaluation of the liver is sometimes non-diagnostic. If the above results do not support primary hepatic disease, consider initiation of Trilostane for pituitary dependent hyperadrenocorticism.
- Given the proteinuria, a UPC is recommended.
- A baseline blood pressure measurement should also be considered.
- Given the presence of a urinary tract infection, a urine culture and sensitivity is recommended 5-7 days following the last dose of antibiotics.
- Consider a recheck abdominal ultrasound in 4-6 weeks to assess the splenic nodule for growth.





The information and recommendations provided are based on the images presented by the referring veterinarian. No evaluation can be communicated regarding pathology that was not visible in the image/video clips provided.

Thank you for this referral. If the clinical or image interpretation does not parallel your findings or if I can be of any further assistance please contact me.

Andrea Nicastro, DVM, Diplomate ACVIM (*Small Animal Internal Medicine*)  
 Andrea.nicastro@sonopath.com