



## PATIENT

Lyla Howard

## PRESENTING CLINICAL SIGNS

## SPECIES

Canine

History: increase in alt and alp noted in the last 8 months~ Relevant Medical History ~ no overt clinical signs of disease: Relevant Laboratory Results / Abnormalities: ~ alt 168 (125) alp 380 (212) bun 33 ua pending~ Current medications (include full name, dosage and frequency): ~ started Denamarin 5/12/2022 hg and ng~

## BREED

Mixed

## ULTRASONOGRAPHIC EXAMINATION OF THE ABDOMEN

## SEX

Spayed Female

### Urinary System

The urinary bladder, trigone, and pelvic urethra are normal in thickness and the mucosal surface is smooth. The bladder lumen is moderately distended with anechoic urine. No masses, inflammatory changes or calculi are observed. Ureteral papillae and visualized portion of the proximal urethra, visible to a depth of 2 cm, are normal.

## AGE

12 years, 4 mos

The left kidney presented normal size (6.06 cm in length); normal shape and architecture with smooth peripheral margins. There is a normal 1:3 cortex to medulla ratio with mild loss of corticomedullary distinction. There is no evidence of pyelectasia, nephroliths, infarcts or hydronephrosis.

## WEIGHT

49 lbs

The right kidney presented normal size (5.70 cm in length); normal shape and architecture with smooth peripheral margins. There is a normal 1:3 cortex to medulla ratio with mild loss of corticomedullary distinction. There is no evidence of pyelectasia, nephroliths, infarcts or hydronephrosis.

## INTERPRETED BY

Andrea Nicastro, DVM,  
Diplomate ACVIM (Small  
Animal Internal Medicine)

### Adrenal Glands

The left adrenal gland is normal size (0.53 cm at cranial pole) (0.54 cm at caudal pole) (2.58 cm in length); normal shape; homogenous parenchyma. The glandular echogenicity and detail are unremarkable. Capsule, cortex, and medullary definition are normal. The phrenicoabdominal vein and surrounding vasculature are normal.

## IMAGING PERFORMED BY

Loetitia Saint-Jacques,  
RVT LVT

The right adrenal gland is normal size (0.67 cm at cranial pole) (0.52 cm at caudal pole) (3.17 cm in length); normal shape; homogenous parenchyma. The glandular echogenicity and detail are unremarkable. Capsule, cortex, and medullary definition are normal. The phrenicoabdominal vein and surrounding vasculature are normal.

## HOSPITAL NAME

MountainView AH

### Spleen

The spleen is normal in size (1.67 cm in width at the level of the hilus) with a normal capsular contour. The parenchyma is subtly mottled in appearance. A 0.80 cm hypoechoic nodule/area is observed at the cranial aspect. Splenic vasculature is normal.

## REFERRING VET

Dr. Bridget Landon

### Liver

The liver is subjectively normal in size with normal peripheral contours. The parenchyma is hypoechoic relative to the spleen. A 3.14 x 1.86 cm slightly hyperechoic to heterogenous nodule/mass is observed in the region of the right medial lobe. In addition, a 2.67 x 2.20 cm heterogenous, cavitated nodule/mass is observed at the caudal aspect. The remaining parenchyma is subtly heterogenous. Hepatic vasculature and intrahepatic biliary tracts are of normal volume with no evidence of congestion.

## INVOICE

10994

## DATE

5/27/22



## PATIENT

Lyla Howard The gall bladder lumen is moderately distended. The wall is thin and smooth. A moderate amount of mostly gravity dependent, echogenic to mineralized debris is observed within the lumen. The cystic and common bile ducts are normal.

## SPECIES

Canine

### *Gastrointestinal*

The stomach and intestine are free of stasis and exhibit normal peristaltic activity. The gastric lumen is not distended. The gastric wall and pylorus are normal in thickness with a normal layering pattern. The small intestinal lumen is not dilated. The small intestinal wall thickness is normal with a normal layering pattern and appropriate mural detail. Discreet masses are not identified. The colonic wall is normal. No obstructive or overt infiltrative disease is noted.

## BREED

Mixed

## SEX

Spayed Female

### *Pancreas*

The region of the pancreas is isoechoic relative to surrounding omental fat. No obvious parenchymal abnormalities are observed. There is no evidence of regional inflammation or effusion.

## AGE

12 years, 4 mos

### *Free Abdomen*

There is no evidence of free fluid. A 1.83 cm left medial iliac lymph node is visualized. The node is normal in shape and echogenicity. A 1.07 cm jejunal lymph node is also seen.

## WEIGHT

49 lbs

## ULTRASONOGRAPHIC FINDINGS

### Primary Findings

- The cystic hepatic nodule could be consistent with an emerging tumor (i.e., hemangioma, hemangiosarcoma). Alternatively, a benign cystic lesion may be present. The hypoechoic nodule could be consistent with a benign regenerative nodule or an emerging tumor. The diffuse hepatic parenchymal changes are nonspecific and most consistent with benign hepatopathy.

### Secondary Findings

- The splenic parenchymal changes are most consistent with a benign process such as lymphoid hyperplasia, extramedullary hematopoiesis or splenitis with a low possibility of infiltrative neoplasia (i.e., lymphoma, mast cell neoplasia).
- Bilateral, chronic age-related renal changes

## INTERPRETED BY

Andrea Nicastro, DVM,  
Diplomate ACVIM (Small  
Animal Internal Medicine)

## IMAGING PERFORMED BY

Loetitia Saint-Jacques,  
RVT LVT

## HOSPITAL NAME

MountainView AH

## REFERRING VET

Dr. Bridget Landon

## INVOICE

10994

## DATE

5/27/22

## INTERPRETATION OF THE FINDINGS & FURTHER RECOMMENDATIONS

- If an aggressive approach is desired, consider surgical liver biopsies with particular attention to the previously mentioned lesions. Thoracic radiographs should be performed prior to anesthesia, given the patient's age.
- If a more conservative approach is desired, consider serial monitoring (i.e., every 2-3 months) of the patient's liver values, along with a repeat abdominal ultrasound in 4-6 weeks to assess for progression of the lesions.



**PATIENT**

Lyla Howard

**SPECIES**

Canine

**BREED**

Mixed

**SEX**

Spayed Female

**AGE**

12 years, 4 mos

**WEIGHT**

49 lbs

**INTERPRETED BY**

Andrea Nicastro, DVM,  
Diplomate ACVIM (Small  
Animal Internal Medicine)

**IMAGING  
PERFORMED BY**

Loetitia Saint-Jacques,  
RVT LVT

**HOSPITAL NAME**

MountainView AH

**REFERRING VET**

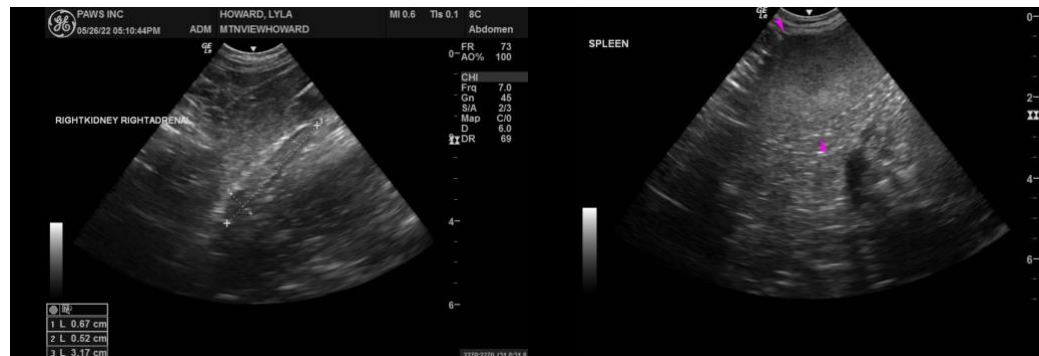
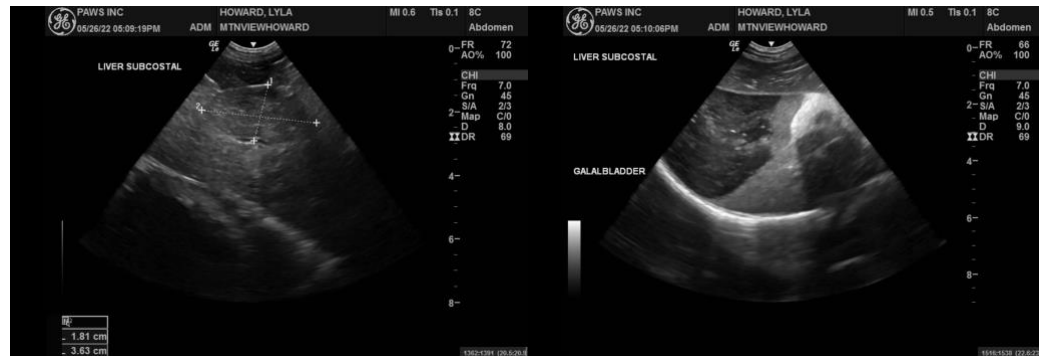
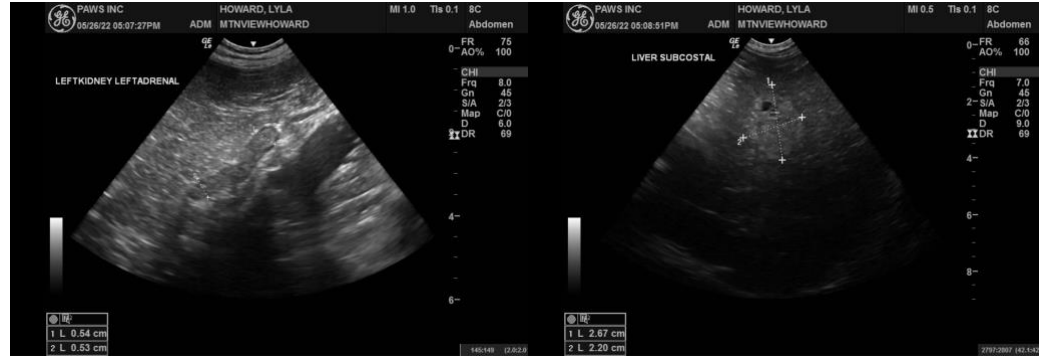
Dr. Bridget Landon

**INVOICE**

10994

**DATE**

5/27/22



The information and recommendations provided are based on the images presented by the referring veterinarian/sonographer. No evaluation can be communicated regarding pathology that was not visible in the image/video clips provided.

Thank you for this referral. If the clinical or image interpretation does not parallel your findings or if I can be of any further assistance, please contact me.

Andrea Nicastro, DVM, Diplomate DACVIM (Small Animal Internal Medicine)  
info@SonoPath.com