



PATIENT PRESENTING CLINICAL SIGNS

Roxy Koster

History: ALT slowly increasing since March 2022. Recommend AUS exam to evaluate for potential underlying issues. Patient is clinically normal.

SPECIES

Abnormal PE/Chem/CBC/UA Results: 3/24 - ALT 151, ALP 166 5/7 - ALT - 140, ALP 166

Canine

ULTRASONOGRAPHIC EXAMINATION OF THE ABDOMEN

BREED

Urinary System

Cockapoo

The urinary bladder, trigone, and pelvic urethra are normal in thickness and the mucosal surface is smooth. The bladder lumen is moderately distended with anechoic urine. No masses, inflammatory changes or calculi are observed. Ureteral papillae and visualized portion of the proximal urethra, visible to a depth of 2 cm, are normal.

SEX

Spayed Female

The left kidney is normal in size (4.12 cm in length) with a normal shape, smooth peripheral margins, and normal internal architecture. There is mild loss of corticomedullary distinction. Several hyperechoic shadowing diverticular foci are observed. Tiny, nonobstructive nephrolith are visualized. There is no evidence of pyelectasia, infarcts or hydroureter. Renal vasculature is normal.

AGE

11 years

The right kidney is normal size (4.37 cm in length); with a normal shape, smooth peripheral margins, and normal internal architecture. There is mild loss of corticomedullary distinction. Several hyperechoic shadowing diverticular foci are observed. Tiny, nonobstructive nephrolith are visualized. There is no evidence of pyelectasia, infarcts or hydroureter. Renal vasculature is normal.

WEIGHT

8.19 kg

Adrenal Glands

INTERPRETED BY

Andrea Nicastro,
DVM, Diplomate
ACVIM (Small Animal
Internal Medicine)

The left adrenal gland is normal size (0.45 cm at cranial pole) (0.48 cm at caudal pole) (1.62 cm in length); normal shape; homogenous parenchyma. The glandular echogenicity and detail are unremarkable. Capsule, cortex, and medullary definition are normal. The phrenicoabdominal vein and surrounding vasculature are normal.

IMAGING PERFORMED BY

Dr. Jolee Stegemoller

The right adrenal gland is normal size (0.40 cm at cranial pole) (0.50 cm at caudal pole) (1.65 cm in length); normal shape; homogenous parenchyma. The glandular echogenicity and detail are unremarkable. Capsule, cortex, and medullary definition are normal. The phrenicoabdominal vein and surrounding vasculature are normal.

HOSPITAL NAME

North ID AH (VCA)

Spleen

The spleen is normal in size (1.29 cm in width at the level of the hilus) with a normal capsular contour. There is appropriate echogenicity and echotexture. No focal lesions are observed. Splenic vasculature is normal.

REFERRING VET

Dr. Jolee Stegemoller

Liver

The liver is subjectively normal in size with normal contours and structure. There is appropriate echogenicity and echotexture. No overt structural evidence of inflammatory, infiltrative, or regenerative pathology is evident. Vascular and biliary tracts are of normal volume with no evidence of congestion. No pathological hepatic lymphadenopathy observed.

INVOICE

10985

The gall bladder lumen is moderately distended. The wall is thin and smooth. Luminal contents are anechoic. The cystic and common bile ducts are normal/not seen.

DATE

5/26/22

Gastrointestinal

The gastric lumen is not distended. The gastric wall is normal in thickness with a normal layering pattern. The small intestinal lumen is not dilated. The small intestinal wall thickness is normal with a normal layering pattern and appropriate mural detail. Discreet masses are not identified. The colonic wall is normal. No obstructive disease is noted.

Pancreas

The region of the pancreas is isoechoic relative to surrounding omental fat. No obvious parenchymal abnormalities are observed. There is no evidence of regional inflammation or effusion.

Free Abdomen

The peritoneal cavity is normal. There is no evidence of inflammation or effusion. The abdominal lymph nodes are normal/not visible.

ULTRASONOGRAPHIC FINDINGS

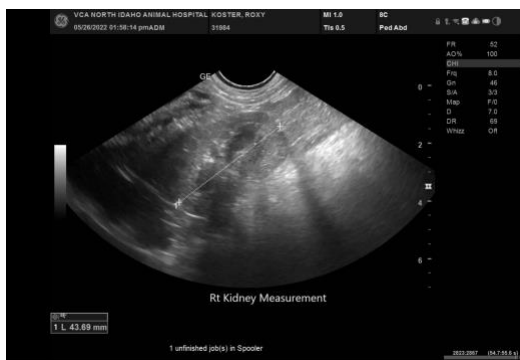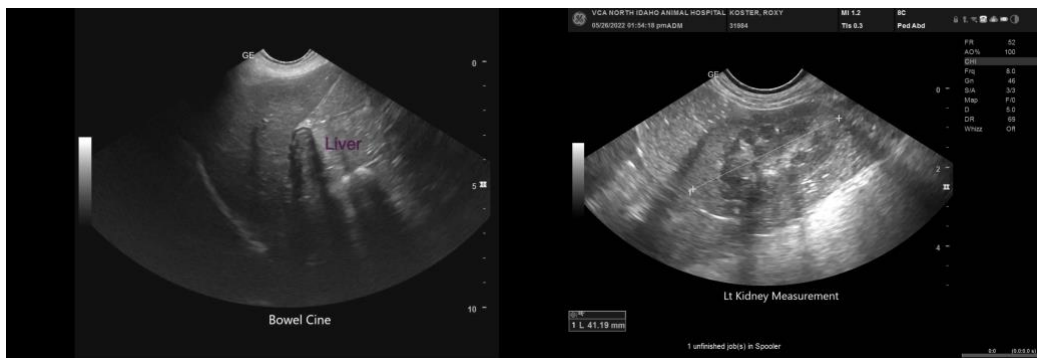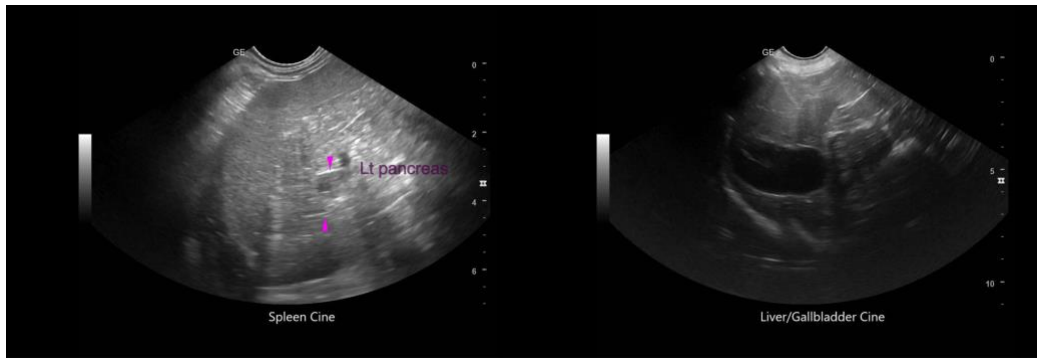
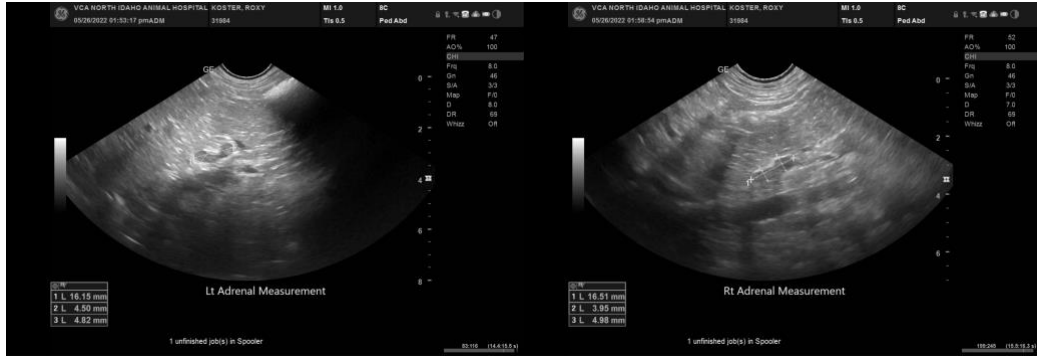
Primary Findings

- Minor, bilateral, chronic renal changes with nonobstructive nephrocalcinosis.

*An obvious cause for the elevated liver enzymes is not identified in the study. However, a microscopic hepatopathy (i.e., bacterial cholangiohepatitis, Leptospirosis, chronic active hepatitis, reactive hepatopathy, copper-associated hepatotoxicity, infiltrative neoplasia (less likely)) cannot be excluded.

INTERPRETATION OF THE FINDINGS & FURTHER RECOMMENDATIONS

- If hepatic cytology is inconclusive and an aggressive approach is desired, consider surgical liver biopsies with aerobic and anaerobic bile cultures and acquisition of additional hepatic tissue samples for potential copper quantitation.
- If a conservative approach is desired, consider empirical treatment for bacterial cholangiohepatitis (amoxicillin-clavulanic acid, +/-metronidazole, Denamarin). If no improvement in the liver values is seen within 7-10 days of initiating therapy, antibiotics should be discontinued, and hepatic tissue sampling reconsidered. If liver values improve, continue therapy for at least 4-6 weeks and 1 week beyond normalization of the liver values.
- Also consider pre-and postprandial serum bile acids to evaluate hepatic function.
- Leptospirosis testing can be considered. However, given the chronicity of liver enzyme elevations, this differential is considered less likely.



The information and recommendations provided are based on the images presented by the referring veterinarian/sonographer. No evaluation can be communicated regarding pathology that was not visible in the image/video clips provided.

Thank you for this referral. If the clinical or image interpretation does not parallel your findings or if I can be of any further assistance, please contact me.

Andrea Nicastro, DVM, Diplomate DACVIM (Small Animal Internal Medicine)
info@SonoPath.com