


PATIENT PRESENTING CLINICAL SIGNS

Charlie Pearson

History: Frank bloody diarrhea started last night. Has not eaten anything since yesterday morning. Lethargic. Today having explosive bloody liquid diarrhea. Hx of carrying around socks but does not think he eats them Had heartworms years ago. Was treated and now tests negative.

SPECIES

Canine

Abnormal PE/Chem/CBC/UA Results: Chem WNL RBC 8.6, HGB 20.4, HCT 57.6%

BREED

Goldendoodle

ULTRASONOGRAPHIC EXAMINATION OF THE ABDOMEN
Urinary System
SEX

Neutered Male

The urinary bladder, trigone, and pelvic urethra are normal in thickness and the mucosal surface is smooth. The bladder lumen is moderately distended with anechoic urine. No masses, inflammatory changes or calculi are observed. Ureteral papillae and visualized portion of the proximal urethra, visible to a depth of 2 cm, are normal.

AGE

9 years

The prostate is normal in size (0.98cm in width) and shape. Parenchyma is homogenous. The prostatic urethra appears normal without evidence of dilation or obstruction.

WEIGHT

104 lbs

The left kidney is normal size (7.19 cm in length); normal shape and architecture with smooth peripheral margins. There is a normal 1:3 cortex to medulla ratio with normal corticomedullary distinction. There is no evidence of pyelectasia, nephroliths, infarcts or hydroureter.

The right kidney is normal size (6.99 cm in length); normal shape and architecture with smooth peripheral margins. There is a normal 1:3 cortex to medulla ratio with minimal loss of corticomedullary distinction. There is no evidence of pyelectasia, nephroliths, infarcts or hydroureter.

INTERPRETED BY

Andrea Nicastro,
 DVM, Diplomate
 ACVIM (Small Animal
 Internal Medicine)

IMAGING PERFORMED BY

Sarah Pender, CVT

HOSPITAL NAME

SVS Imaging QC

Adrenal Glands

The left adrenal gland is normal size (0.42 cm at cranial pole) (0.62 cm at caudal pole) (2.02 cm in length); normal shape; homogenous parenchyma. The glandular echogenicity and detail are unremarkable. Capsule, cortex, and medullary definition are normal. The phrenicoabdominal vein and surrounding vasculature are normal.

The right adrenal gland is normal size (0.79 cm at cranial pole) (0.56 cm at caudal pole) (3.18 cm in length); normal shape; homogenous parenchyma. The glandular echogenicity and detail are unremarkable. Capsule, cortex, and medullary definition are normal. The phrenicoabdominal vein and surrounding vasculature are normal.

REFERRING VET

Dr. Haenni

Spleen

The spleen is subjectively normal in size (2.34 cm in width at the level of the hilus) with normal curvilinear peripheral contours. The parenchyma is subtly mottled in appearance. A few, small, ill-defined hyperechoic nodules/areas are observed. Splenic vasculature appears normal with no evidence of thrombosis.

INVOICE

10962

Liver
DATE

5/26/22

The liver is subjectively normal in size with normal contours and structure. There is appropriate echogenicity and echotexture. No overt structural evidence of inflammatory, infiltrative, or regenerative pathology is evident. Vascular and biliary tracts are of normal volume with no evidence of congestion. No pathological hepatic lymphadenopathy observed.

The gall bladder lumen is moderately distended. The wall is thin and smooth. Luminal contents are anechoic. The cystic and common bile ducts are normal/not seen.

Gastrointestinal

The gastric lumen is minimally fluid-distended. The gastric wall and pylorus are normal in thickness with a normal layering pattern. The pyloric outflow tract is patent. The small intestinal lumen is segmentally distended with gas (mild). The small intestinal wall is normal in thickness with a normal layering pattern and appropriate mural detail. Discreet masses are not identified. The colonic wall is normal. The colonic lumen is fluid-distended and hypomotile. There is no obvious evidence of an obstructive pattern.

Pancreas

The region of the pancreas is isoechoic relative to surrounding omental fat. No obvious parenchymal abnormalities are observed. There is no evidence of regional inflammation or effusion.

Free Abdomen

The peritoneal cavity is normal. There is no evidence of inflammation or effusion. The abdominal lymph nodes are normal/not visible.

ULTRASONOGRAPHIC FINDINGS

Primary Findings

- The gastrointestinal changes are most consistent with gastroenteritis/colitis. There is no obvious evidence of a foreign body/obstruction. However, a partial obstruction cannot be completely excluded.

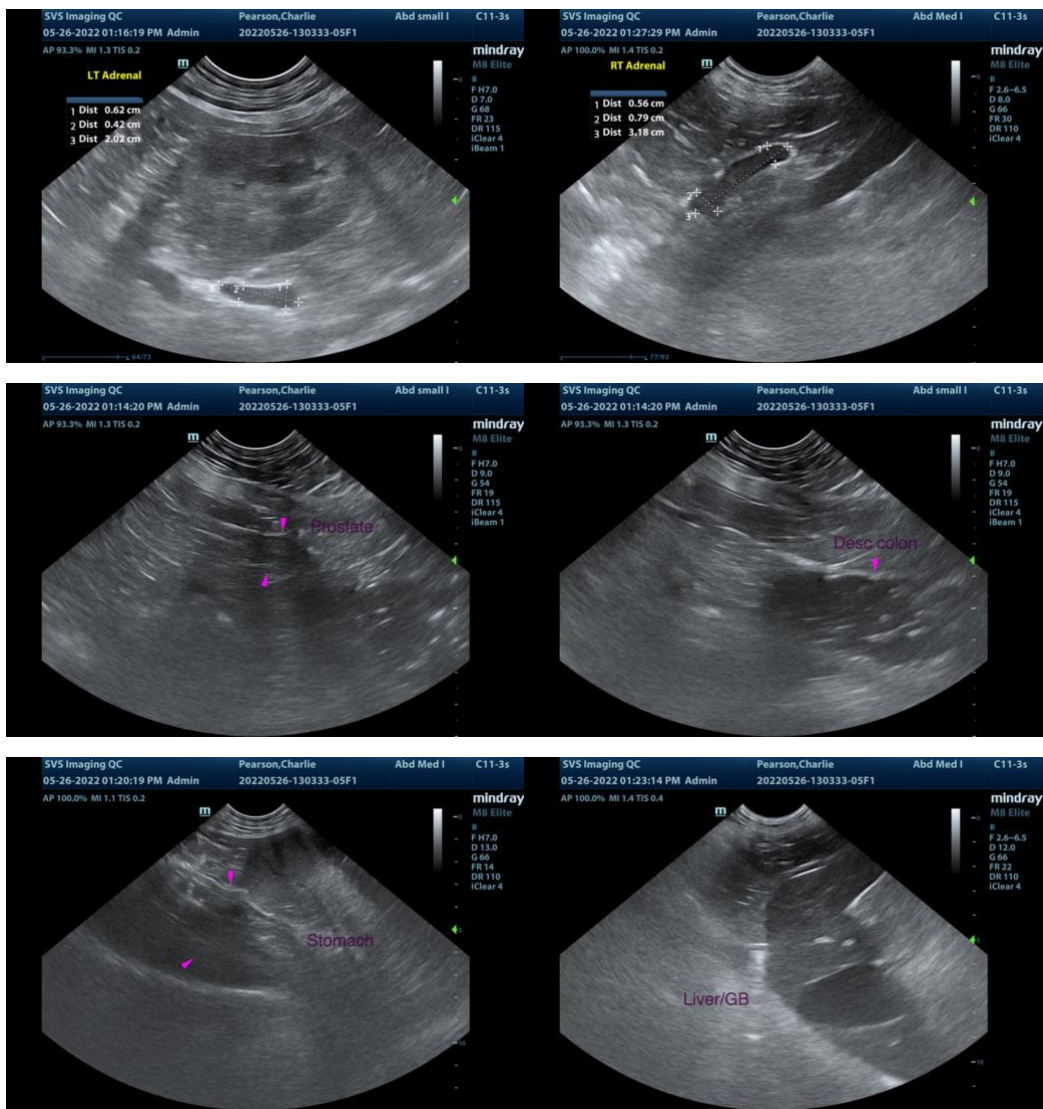
Secondary Findings

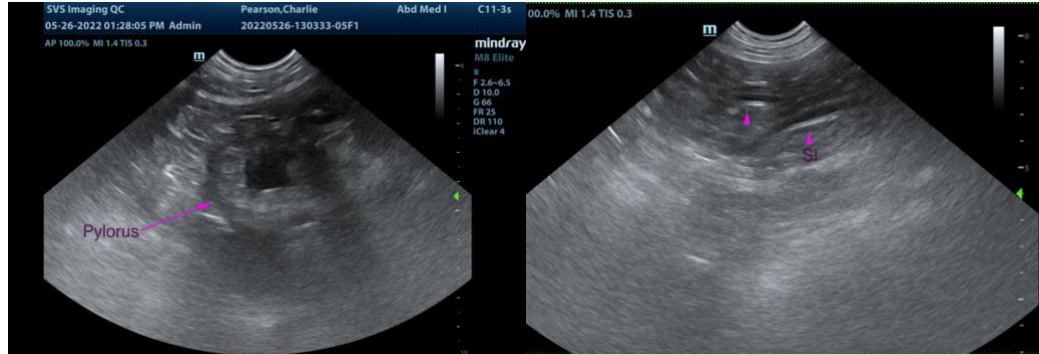
- The splenic parenchyma changes are most consistent with a benign process such as lymphoid hyperplasia, extramedullary hematopoiesis or splenitis with a low possibility of infiltrative neoplasia (i.e., lymphoma, mast cell neoplasia). The hyperechoic nodules are most consistent with a benign process (i.e., myelolipomas).

INTERPRETATION OF THE FINDINGS & FURTHER RECOMMENDATIONS

- Fecal evaluation for ova and Giardia
- Prophylactic deworming with Fenbendazole at 50 mg/kg once a day for 5 days is recommended. Repeat above protocol in 3 weeks.

- Supportive care for acute hemorrhagic gastroenteritis is recommended.
- Also consider initiation of a probiotic with a high colony count (i.e., Visbiome or Provable Forte).
- If the patient's clinical signs do not improve within 48-72 hours of medical management, a more advance GI work-up (i.e., malabsorption panel, resting cortisol level, +/- GI biopsies) may be warranted.





The information and recommendations provided are based on the images presented by the referring veterinarian/sonographer. No evaluation can be communicated regarding pathology that was not visible in the image/video clips provided.

Thank you for this referral. If the clinical or image interpretation does not parallel your findings or if I can be of any further assistance, please contact me.

Andrea Nicastro, DVM, Diplomate DACVIM (Small Animal Internal Medicine)
info@SonoPath.com