

PATIENT

Charlie Edwards

PRESENTING CLINICAL SIGNS

History: Hx of splenomegaly w/ possible splenic mass noted on sedated radiographs when assessing patient for CCLR.

SPECIES

Canine

Abnormal PE/Chem/CBC/UA Results: Splenomegaly, limping RR leg, otherwise NSF on PE BW unremarkable.

BREED

English Bulldog X

ULTRASONOGRAPHIC EXAMINATION OF THE ABDOMEN

Urinary System

SEX

Spayed Female

The urinary bladder, trigone, and pelvic urethra are normal in thickness and the mucosal surface in the region of the apex is slightly irregular. The bladder lumen is moderately distended with anechoic urine. No masses, inflammatory changes or calculi are observed. Ureteral papillae and visualized portion of the proximal urethra, visible to a depth of 2 cm, are normal.

AGE

8 years

The left kidney is normal size (6.18 cm in length); normal shape and architecture with smooth peripheral margins. There is a normal 1:3 cortex to medulla ratio with minimal loss of corticomedullary distinction. There is no evidence of pyelectasia, nephroliths, infarcts or hydroureter.

The right kidney is normal size (5.40 cm in length); normal shape and architecture with smooth peripheral margins. There is a normal 1:3 cortex to medulla ratio with minimal loss of corticomedullary distinction. There is no evidence of pyelectasia, nephroliths, infarcts or hydroureter.

WEIGHT

53.5 lbs

Adrenal Glands

INTERPRETED BY

Andrea Nicastro,
DVM, Diplomate
ACVIM (*Small Animal
Internal Medicine*)

The left adrenal gland is normal size (0.47 cm at cranial pole) (0.51 cm at caudal pole) (2.31 cm in length); normal shape; homogenous parenchyma. The glandular echogenicity and detail are unremarkable. Capsule, cortex, and medullary definition are normal. The phrenicoabdominal vein and surrounding vasculature are normal.

The right adrenal gland is normal size (0.98 cm at cranial pole) (0.42 cm at caudal pole) (2.89 cm in length); normal shape; homogenous parenchyma. The glandular echogenicity and detail are unremarkable. Capsule, cortex, and medullary definition are normal. The phrenicoabdominal vein and surrounding vasculature are normal.

IMAGING PERFORMED BY

Jessica Bailes

HOSPITAL NAME

All Creatures Great &
Sm. VC, Corvallis, OR

Spleen

The spleen is normal subjectively enlarged (2.62 cm in width at the level of the hilus) with an elongated, curled contour. The parenchyma is subtly mottled in appearance. No distinct focal lesions are observed. Splenic vasculature appears normal with no evidence of thrombosis.

REFERRING VET

Dr.Chantal Litalien

Liver

The liver is subjectively normal in size with normal contours and structure. There is appropriate echogenicity and echotexture. No overt structural evidence of inflammatory, infiltrative, or regenerative pathology is evident. Vascular and biliary tracts are of normal volume with no evidence of congestion. No pathological hepatic lymphadenopathy observed.

INVOICE

10979

The gall bladder is of normal contours and contains some dependent echogenic debris. The wall is normal in thickness. No choleliths are observed. The cystic and common bile ducts are normal/not seen.

DATE

5/26/22

Gastrointestinal

The stomach and intestine are free of stasis and exhibit normal peristaltic activity. The gastric lumen is not distended. The gastric wall and pylorus are normal in thickness with a normal layering pattern. The pyloric outflow tract is patent. The small intestinal lumen is not dilated. The small intestinal wall thickness is normal with a normal layering pattern and appropriate mural detail. Discreet masses are not identified. The colonic wall is normal. No obstructive disease is noted.

Pancreas

A portion of the pancreas is obscured by the splenomegaly. In the visualized portion, no obvious pathology is seen.

Free Abdomen

The peritoneal cavity is normal. There is no evidence of inflammation or effusion. A 1.80 cm medial iliac lymph node is seen.

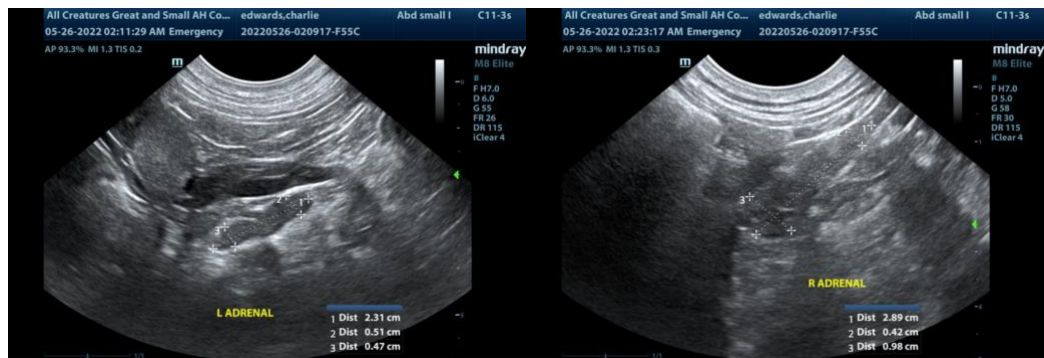
ULTRASONOGRAPHIC FINDINGS

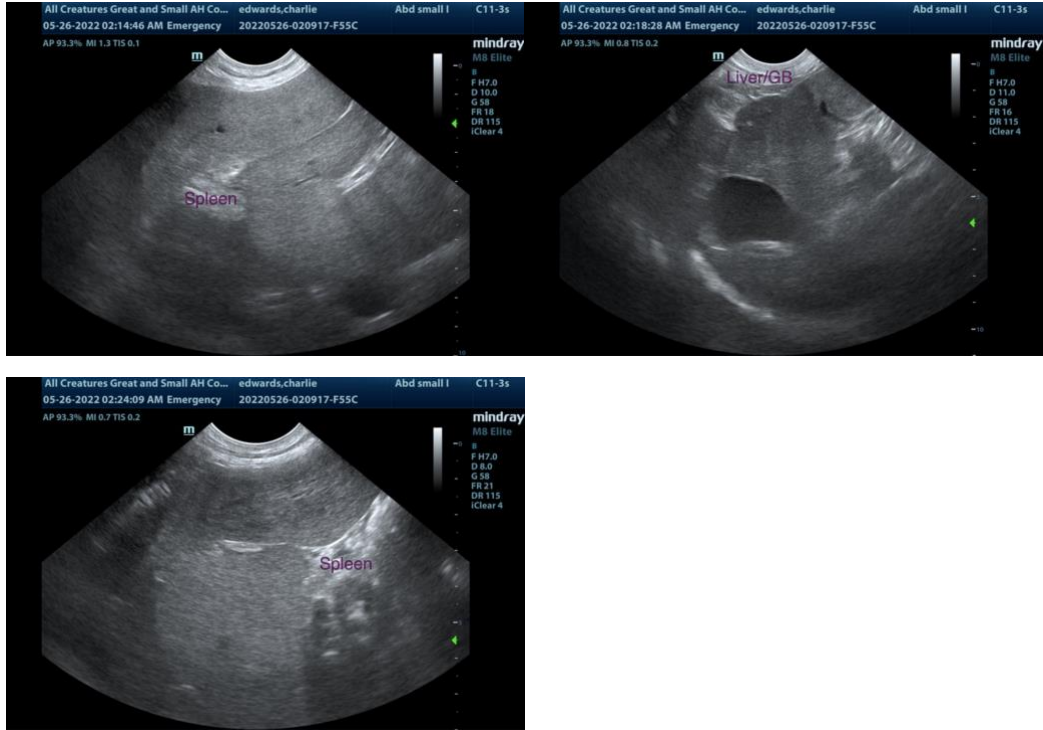
Primary Findings

- The splenic changes could be consistent with infiltrative neoplasia (i.e., round cell tumor), splenitis, antigenic stimulation, lymphoid hyperplasia, extramedullary hematopoiesis, other.

INTERPRETATION OF THE FINDINGS & FURTHER RECOMMENDATIONS

- A fine-needle aspirate of the spleen is recommended if clotting status is appropriate. A 25-gauge needle should be used. Further recommendations should be based on cytology results.





The information and recommendations provided are based on the images presented by the referring veterinarian/sonographer. No evaluation can be communicated regarding pathology that was not visible in the image/video clips provided.

Thank you for this referral. If the clinical or image interpretation does not parallel your findings or if I can be of any further assistance, please contact me.

Andrea Nicastro, DVM, Diplomate DACVIM (Small Animal Internal Medicine)
info@SonoPath.com