

PATIENT

Buster Ba

SPECIES

Canine

BREED

Corgi

SEX

Neutered Male

AGE

8/6/2012

WEIGHT

17.4 kg

INTERPRETED BY

Andrea Nicastro,
DVM, Diplomate
ACVIM (Small Animal
Internal Medicine)

**IMAGING
PERFORMED BY**

Andrea Nicastro,
DVM, Diplomate
ACVIM (Small Animal
Internal Medicine)

HOSPITAL NAME

Blue Pearl - Mt
Pleaseant

REFERRING VET

Dr. Michelle Wall

INVOICE

10958

DATE

5/26/22

PRESENTING CLINICAL SIGNS

Clinical Exam Findings: History of metastatic seminoma. Had radiation for caudal lymphadenopathy.

ULTRASONOGRAPHIC EXAMINATION OF THE ABDOMEN

Urinary System

The urinary bladder, trigone, and pelvic urethra are normal in thickness and the mucosal surface is smooth. The bladder lumen is moderately distended with anechoic urine. No masses, inflammatory changes or calculi are observed. Ureteral papillae and visualized portion of the proximal urethra, visible to a depth of 2 cm, are normal.

The prostate is mildly enlarged (1.67 cm in width) with a normal shape and smooth peripheral contours. The parenchyma is heterogenous. The prostatic urethra is not overtly dilated.

The left kidney is normal size (6.09 cm in length); normal shape and architecture with smooth peripheral margins. There is a normal 1:3 cortex to medulla ratio with minimal to mild loss of corticomedullary distinction. There is no evidence of pyelectasia, nephroliths, infarcts or hydronephrosis. Renal vasculature is normal.

The right kidney is normal size (7.11 cm in length); normal shape and architecture with smooth peripheral margins. There is a normal 1:3 cortex to medulla ratio with minimal to mild loss of corticomedullary distinction. There is no evidence of pyelectasia, nephroliths, infarcts or hydronephrosis. Renal vasculature is normal.

Adrenal Glands

The left adrenal gland is normal size (0.49 cm at cranial pole) (0.56 cm at caudal pole) (1.99 cm in length); normal shape; homogenous parenchyma. The glandular echogenicity and detail are unremarkable. Capsule, cortex, and medullary definition are normal. The phrenicoabdominal vein and surrounding vasculature are normal.

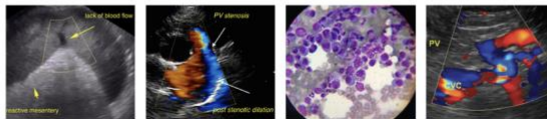
The right adrenal gland is normal size (1.02 cm at cranial pole) (0.52 cm at caudal pole) (1.91 cm in length); normal shape; homogenous parenchyma. The glandular echogenicity and detail are unremarkable. Capsule, cortex, and medullary definition are normal. The phrenicoabdominal vein and surrounding vasculature are normal.

Spleen

The spleen is normal in size (1.56 cm in width at the level of the hilus) with a normal capsular contour. There is appropriate echogenicity and echotexture. No focal lesions are observed. Splenic vasculature is normal.

Liver

The liver is subjectively normal in size with normal curvilinear peripheral contours. The parenchyma is hypoechoic relative to the spleen with minor changes consistent with age-related remodeling. No



PATIENT

Buster Ba

SPECIES

Canine

BREED

Corgi

SEX

Neutered Male

AGE

8/6/2012

WEIGHT

17.4 kg

INTERPRETED BY

Andrea Nicastro,
DVM, Diplomate
ACVIM (Small Animal
Internal Medicine)

IMAGING PERFORMED BY

Andrea Nicastro,
DVM, Diplomate
ACVIM (Small Animal
Internal Medicine)

HOSPITAL NAME

Blue Pearl - Mt
Pleaseant

REFERRING VET

Dr. Michelle Wall

INVOICE

10958

DATE

5/26/22

focal lesions are observed. Hepatic vasculature and biliary tracts are of normal volume with no evidence of congestion. The portal vein to caudal vena cava ratio is approximately 1: 1.

The gall bladder is of normal contours and contains some dependent echogenic debris. The wall is normal in thickness. No choleliths are observed. The cystic and common bile ducts are normal/not seen.

Gastrointestinal

The stomach and intestine are free of stasis and exhibit normal peristaltic activity. The gastric lumen is mildly distended with ingesta. The gastric wall and pylorus are normal in thickness with a normal layering pattern. The pyloric outflow tract is patent. The small intestinal lumen is segmentally dilated with chyme. The small intestinal wall thickness is normal with a normal layering pattern and appropriate mural detail. Discreet masses are not identified. The colonic wall is normal. No obstructive disease is noted.

Pancreas

The region of the pancreas is isoechoic relative to surrounding omental fat. No obvious parenchymal abnormalities are observed. There is no evidence of regional inflammation or effusion.

Free Abdomen

The peritoneal cavity is normal. There is no evidence of inflammation or effusion. a 2.73 x 1.27 left medial iliac lymph node is visualized. The nodule is slightly rounded to irregular and mildly hypoechoic.

Other

A brief echocardiogram reveals no evidence of pericardial effusion or obvious right atrial/auricular mass.

ULTRASONOGRAPHIC FINDINGS

Primary Findings

- The medial iliac lymphadenopathy has dramatically improved compared the previous sonogram.

Secondary Findings

- The prostate changes are most consistent with resolving benign prostatic hyperplasia due to late-in-life neutering.
- Minor age-related hepatic and renal changes

INTERPRETATION OF THE FINDINGS & FURTHER RECOMMENDATIONS

- Further diagnostic/treatment recommendations will be provided by the overseeing oncologist.



PATIENT

Buster Ba

SPECIES

Canine

BREED

Corgi

SEX

Neutered Male

AGE

8/6/2012

WEIGHT

17.4 kg

INTERPRETED BY

Andrea Nicastro,
DVM, Diplomate
ACVIM (Small Animal
Internal Medicine)

IMAGING PERFORMED BY

Andrea Nicastro,
DVM, Diplomate
ACVIM (Small Animal
Internal Medicine)

HOSPITAL NAME

Blue Pearl - Mt
Pleasant

REFERRING VET

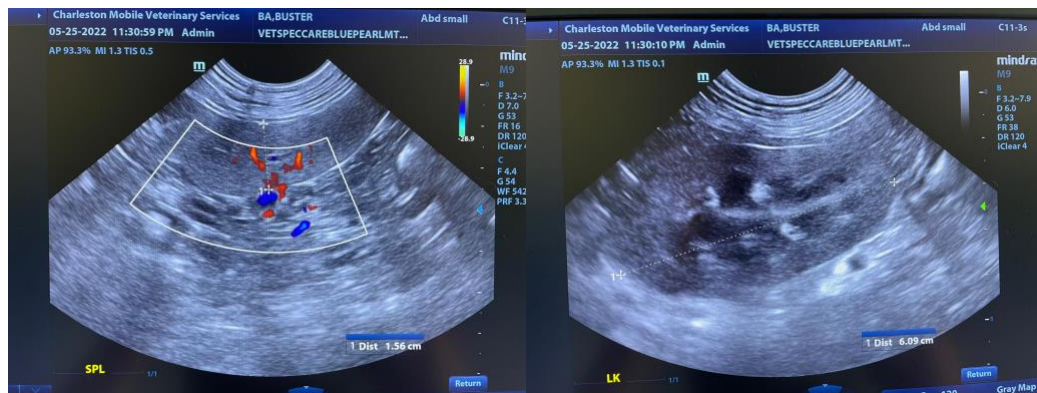
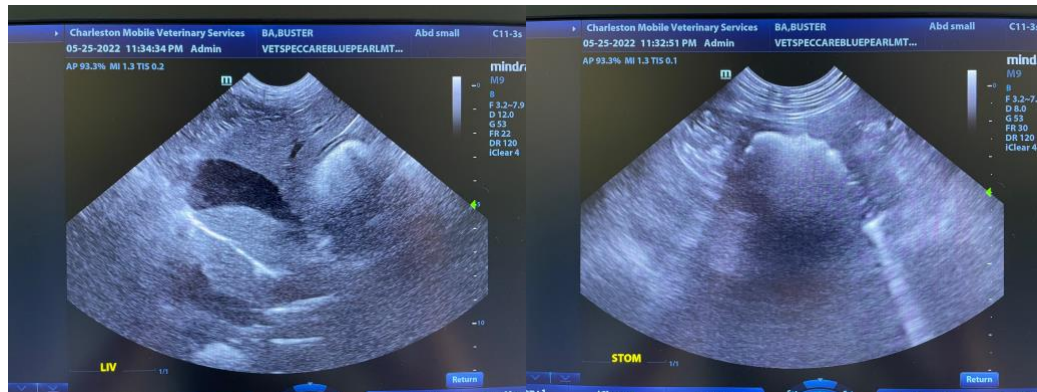
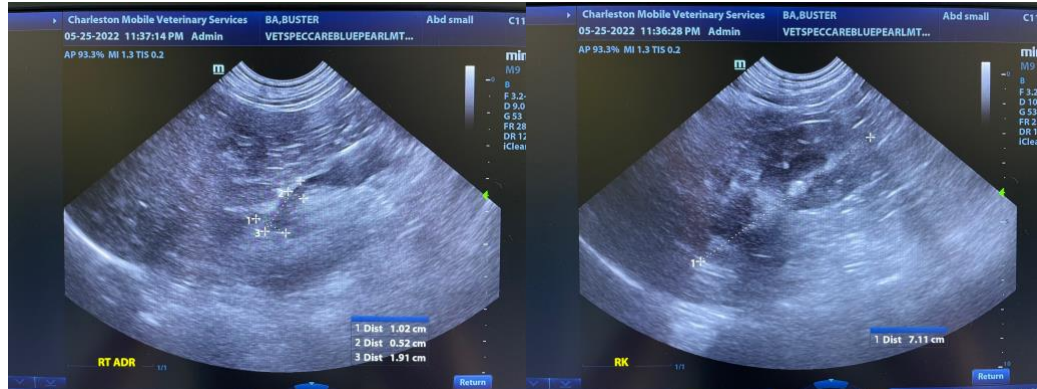Dr. Michelle Wall

INVOICE

10958

DATE

5/26/22





PATIENT

Buster Ba

SPECIES

Canine

BREED

Corgi

SEX

Neutered Male

AGE

8/6/2012

WEIGHT

17.4 kg

INTERPRETED BY

Andrea Nicastro,
DVM, Diplomate
ACVIM (Small Animal
Internal Medicine)

IMAGING PERFORMED BY

Andrea Nicastro,
DVM, Diplomate
ACVIM (Small Animal
Internal Medicine)

HOSPITAL NAME

Blue Pearl - Mt
Pleaseant

REFERRING VET

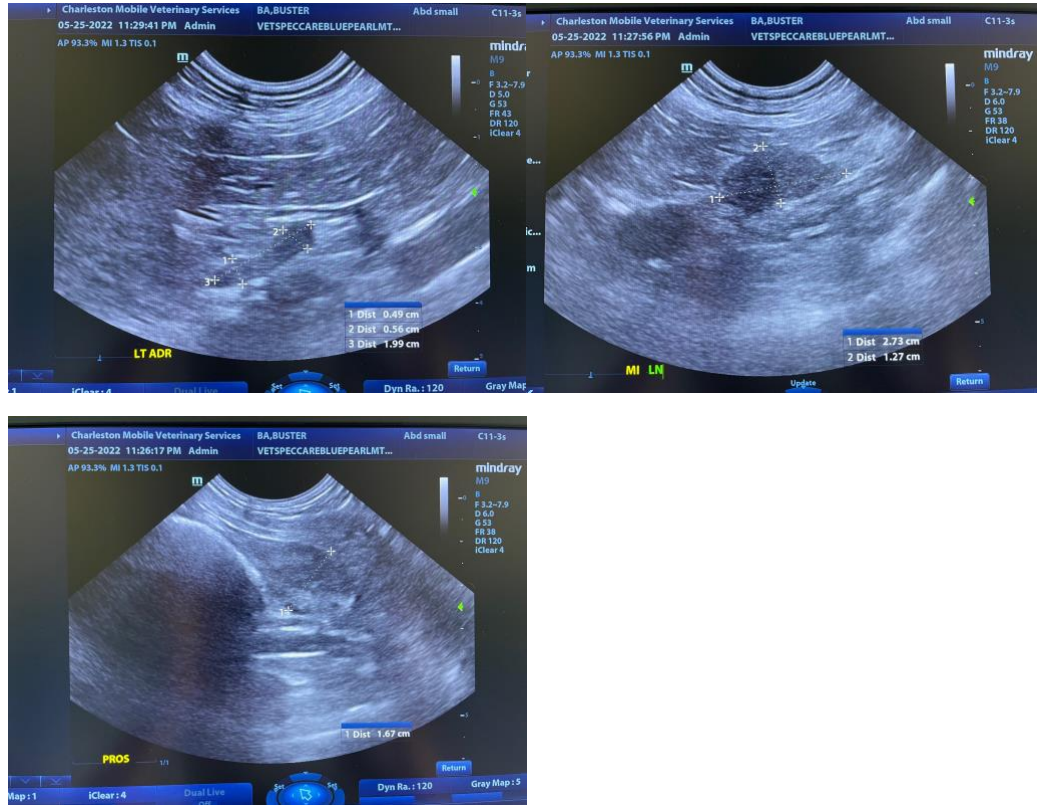
Dr. Michelle Wall

INVOICE

10958

DATE

5/26/22



The information and recommendations provided are based on the images presented by the referring veterinarian/sonographer. No evaluation can be communicated regarding pathology that was not visible in the image/video clips provided.

Thank you for this referral. If the clinical or image interpretation does not parallel your findings or if I can be of any further assistance, please contact me.

Andrea Nicastro, DVM, Diplomate DACVIM (Small Animal Internal Medicine)
info@SonoPath.com