



PATIENT PRESENTING CLINICAL SIGNS

Banjo Brown History: Waxing and waning anorexia with vomiting Since Feb 2022. Has been eating HA exclusively since February. Does have tendency to get into things and chew up things. Started Pred 10mg SID a couple days ago. Patient had 12-hour fast before scan but got into crackers just before.

SPECIES

Canine Abnormal PE/Chem/CBC/UA Results: NO abnormal exam findings, labs unremarkable. Radiographs were unremarkable except a full colon in Feb. Recent blood work (2 days ago) wnl, Na/K+ wnl (>30)

BREED

Pitbull Mix

ULTRASONOGRAPHIC EXAMINATION OF THE ABDOMEN

Urinary System

SEX

Neutered Male

The urinary bladder, trigone, and pelvic urethra are normal in thickness and the mucosal surface is smooth. The bladder lumen is mildly distended with anechoic urine. No masses, inflammatory changes or calculi are observed. The region of the trigone and the visible portion of the proximal urethra are normal.

The prostate is not definitively visualized due to its pelvic location.

AGE

2 years

The left kidney is normal size (5.59 cm in length); normal shape and architecture with smooth peripheral margins. There is a normal 1:3 cortex to medulla ratio with normal corticomedullary distinction. There is no evidence of pyelectasia, nephroliths, infarcts or hydroureter.

WEIGHT

61 lbs

The right kidney is normal size (7.20 cm in length); normal shape and architecture with smooth peripheral margins. There is a normal 1:3 cortex to medulla ratio with normal corticomedullary distinction. There is no evidence of pyelectasia, nephroliths, infarcts or hydroureter. Renal vasculature is normal.

INTERPRETED BY

Andrea Nicastro,
DVM, Diplomate
ACVIM (*Small Animal
Internal Medicine*)

Adrenal Glands

The left adrenal gland is normal size (0.47 cm at cranial pole) (0.47 cm at caudal pole) (x2.98xx cm in length); normal shape; homogenous parenchyma. The glandular echogenicity and detail are unremarkable. Capsule, cortex, and medullary definition are normal. The phrenicoabdominal vein and surrounding vasculature are normal.

IMAGING PERFORMED BY

Sarah Pender, CVT

The right adrenal gland is normal size (0.54 cm at cranial pole) (0.58 cm at caudal pole) (2.75 cm in length); normal shape; homogenous parenchyma. The glandular echogenicity and detail are unremarkable. Capsule, cortex, and medullary definition are normal. The phrenicoabdominal vein and surrounding vasculature are normal.

HOSPITAL NAME

SVS Imaging QC

Spleen

The spleen is normal in size (1.64 cm in width at the level of the hilus) with a normal capsular contour. There is appropriate echogenicity and echotexture. No focal lesions are observed. Splenic vasculature is normal.

REFERRING VET

Dr. Hook

INVOICE

10970

Liver

The liver is subjectively normal in size with normal contours and structure. There is appropriate echogenicity and echotexture. No overt structural evidence of inflammatory, infiltrative, or regenerative

DATE

5/26/22

pathology is evident. Vascular and biliary tracts are of normal volume with no evidence of congestion. No pathological hepatic lymphadenopathy observed.

The gall bladder lumen is moderately distended. The wall is thin and smooth. Luminal contents are anechoic. The cystic and common bile ducts are normal/not seen.

Gastrointestinal

The gastric lumen is not distended. The gastric wall is normal in thickness with a normal layering pattern. The small intestinal lumen is segmentally dilated with chyme. The small intestinal wall thickness is normal with a normal layering pattern and appropriate mural detail. Discreet masses are not identified. The colonic wall is normal. No obstructive disease is noted.

Pancreas

A portion of the pancreas is obscured by the gastric distention. In the visualized portions, no obvious pathology is seen.

Free Abdomen

The peritoneal cavity is normal. There is no evidence of inflammation or effusion. The abdominal lymph nodes are normal/not visible.

ULTRASONOGRAPHIC FINDINGS

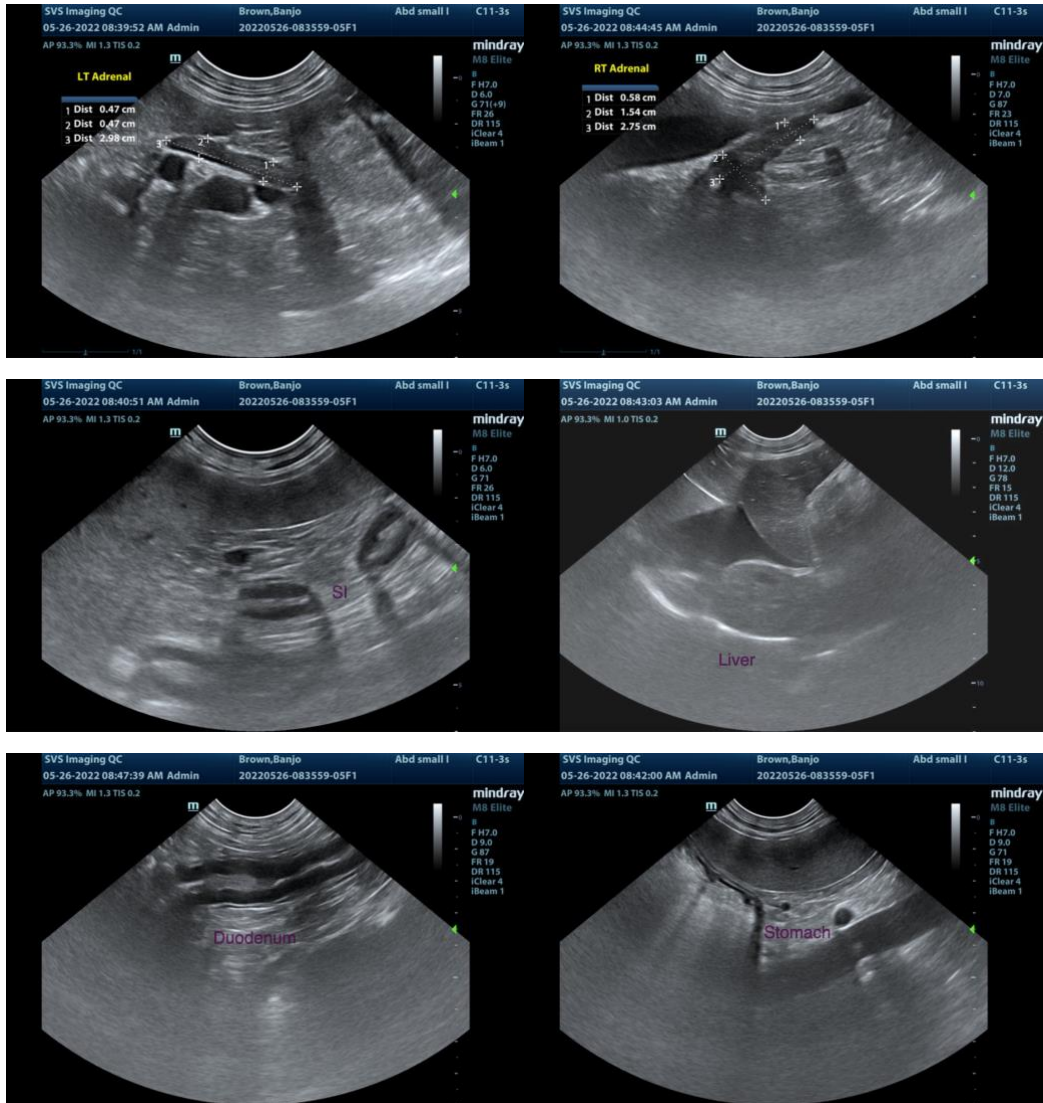
Primary Findings

- Unremarkable abdomen. An obvious cause for the patient's clinical signs is not identified in this study. Differentials include primary gastrointestinal disease (i.e., inflammatory bowel disease, intestinal dysbiosis), underlying metabolic issue, low-grade pancreatitis, other.

INTERPRETATION OF THE FINDINGS & FURTHER RECOMMENDATIONS

- Thoracic radiographs are recommended to assess for occult esophageal disease
- GI panel (Send to TX A&M)
- A resting cortisol level is recommended to screen for atypical hypoadrenocorticism
- Fecal evaluation for ova and Giardia, if not already performed

If the above diagnostics are inconclusive, GI biopsies (i.e., endoscopic, or surgical) may be necessary to get a definitive diagnosis. If biopsies are pursued, the patient should be weaned off prednisone, as corticosteroids can mask underlying GI pathology.



The information and recommendations provided are based on the images presented by the referring veterinarian/sonographer. No evaluation can be communicated regarding pathology that was not visible in the image/video clips provided.

Thank you for this referral. If the clinical or image interpretation does not parallel your findings or if I can be of any further assistance, please contact me.

Andrea Nicastro, DVM, Diplomate DACVIM (Small Animal Internal Medicine)
info@SonoPath.com