

**DATE**

5/24/22

PRESENTING CLINICAL SIGNS

Enlarged popliteal LN, lethargy, malaise, non-healing mass on neck, new murmur.

PATIENT

Riley Wasserman

Current Medications: None listed.

Lab Results: mild ALT 285/ALK PHOS 241 elevation.

Date of Previous IntraPet Ultrasound: No previous.

Sedation: Not required to complete full diagnostic ultrasound.

Stat Report: Not requested.

SPECIES

Canine

Imaging Performed By: Andi Parkinson, BS, RDMS.

BREED

Labrador

ULTRASONOGRAPHIC EXAMINATION OF THE ABDOMEN**Urinary System**

The urinary bladder, trigone, and pelvic urethra are normal in thickness and the mucosal surface is smooth.

The bladder lumen is moderately distended with mostly anechoic urine. No masses, inflammatory changes or calculi are observed. Ureteral papillae and visualized portion of the proximal urethra, visible to a depth of 1-2 cm, are normal.

SEX

Male, neutered

The prostate is normal in size (0.97 cm in width) and shape. Parenchyma is homogenous. The prostatic urethra appears normal without evidence of dilation or obstruction.

AGE

9/2/2009

The left kidney is normal size (6.09 cm in length) with a normal shape, smooth peripheral margins and normal internal architecture. There is mild loss of corticomedullary distinction. Several hyperechoic shadowing diverticular foci are observed. A few small, non-obstructive nephroliths are visualized. There is no evidence of pyelectasia, infarcts or hydronephrosis. Renal vasculature is normal.

WEIGHT

56.6 lbs.

The right kidney is normal in size (6.35 cm in length) with a normal shape, smooth peripheral margins and normal internal architecture. There is mild loss of corticomedullary distinction. Several hyperechoic shadowing diverticular foci are observed. A few small, non-obstructive nephroliths are visualized. There is no evidence of pyelectasia, infarcts or hydronephrosis. Renal vasculature is normal.

INTERPRETED BYAndrea Nicastro, DVM,
Diplomate ACVIM
(Small Animal Internal
Medicine)**Adrenal Glands**

The left adrenal gland is normal size (0.92 cm at cranial pole) (0.84 cm at caudal pole) (2.45 cm in length); normal shape; homogenous parenchyma. The glandular echogenicity and detail are unremarkable. Capsule, cortex, and medullary definition are normal. The phrenicoabdominal vein and surrounding vasculature are normal.

HOSPITAL NAME

Banfield Towson

REFERRING VET

Dr. Mike

The right adrenal gland is normal size (0.85 cm at cranial pole) (0.71 cm at caudal pole) (2.20 cm in length); normal shape; homogenous parenchyma. The glandular echogenicity and detail are unremarkable. Capsule, cortex, and medullary definition are normal. The phrenicoabdominal vein and surrounding vasculature are normal.

INVOICE

13429

Spleen

The spleen is normal in size (2.23 cm in width at the level of the hilus) with a normal capsular contour. The parenchyma is subtly mottled in appearance. A 0.96 cm, irregular hyperechoic nodule is observed near the lateral aspect. Splenic vasculature is normal.

Liver

The liver is subjectively normal in size with normal contours and structure. The parenchyma is hypoechoic relative to the spleen and subtly heterogeneous in appearance with a few ill-defined hyperechoic nodules, the largest measuring 2.86 cm in its longest dimension. Vascular and biliary tracts are of normal volume with

no evidence of congestion. The gallbladder is of normal contours and contains some dependent echogenic debris. The wall is normal in thickness. No choleliths are observed. The cystic and common bile ducts are normal.

Gastrointestinal

The stomach and intestine are free of stasis and exhibit normal peristaltic activity. The gastric lumen is not distended. The gastric wall and pylorus are normal in thickness with a normal layering pattern. The pyloric outflow tract is patent. The small intestinal lumen is not dilated. The small intestinal wall thickness is normal with a normal layering pattern. There is disruption in the normal 1:3 muscularis: mucosal ratio in some segments. At the ileocecal colic junction there is a focal thickening (1.01 x 0.76 cm) of the cecal wall. There is questionable loss of the normal layering pattern within this region. The colonic wall is normal. No obstructive disease is noted.

Pancreas

The region of the pancreas is isoechoic relative to surrounding omental fat. No obvious parenchymal abnormalities are observed. There is no evidence of regional inflammation or effusion.

Free Abdomen

The peritoneal cavity is normal. There is no evidence of inflammation or effusion. The abdominal lymph nodes are normal/not visible.

ULTRASONOGRAPHIC FINDINGS

Primary Findings:

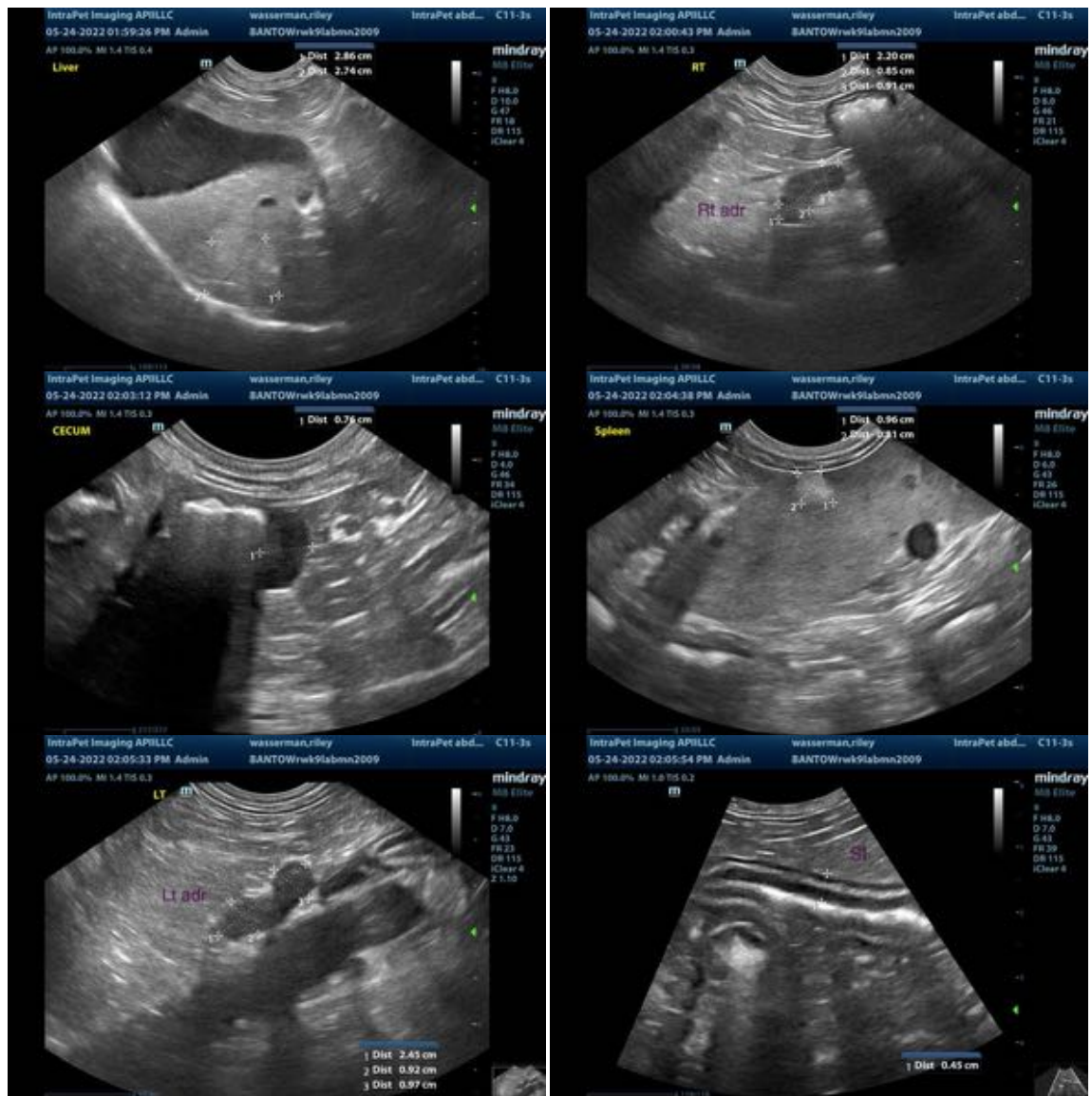
- Focal cecal wall thickening. This may represent emerging neoplasia (i.e., adenocarcinoma, lymphoma) or a focal inflammatory process (i.e., typhlitis).
- The diffuse small intestinal wall changes are suggestive of inflammatory bowel disease. However, correlation with the patient's clinical history is recommended.
- The hepatic parenchymal changes are non-specific and could be secondary to an inflammatory hepatopathy (i.e., chronic active hepatitis, bacterial cholangiohepatitis), hepatotoxicosis, Leptospirosis +/- concurrent age-related change, (i.e., regenerative nodular hyperplasia, vacuolar hepatopathy).

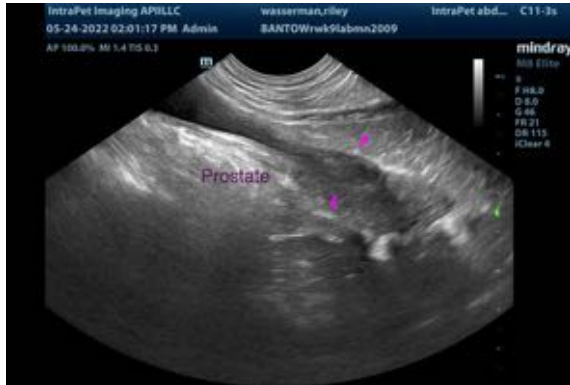Secondary Findings:

- The splenic parenchyma changes are most consistent with a benign process such as lymphoid hyperplasia, extramedullary hematopoiesis or splenitis with a low possibility of infiltrative neoplasia (i.e., lymphoma, mast cell neoplasia).
- The hyperechoic splenic nodule trends toward the benign (i.e., focus of lymphoid hyperplasia, myelolipoma or similar) with a lower possibility of emerging neoplasia.
- Bilateral mild age-related renal changes with non-obstructive nephrocalcinosis.

INTERPRETATION OF THE FINDINGS & FURTHER RECOMMENDATIONS

- Fine needle aspirate of the enlarged popliteal lymph node is recommended (if not already performed) along with three-view thoracic radiographs.
- Regarding the hepatic and cecal changes, consider tissue sampling (i.e., fine needle aspirates or surgical biopsies). Surgical biopsies are more likely to yield a definitive diagnosis. If pursued, aerobic and anaerobic bile cultures and samples for acquisition of hepatic tissue samples for potential copper quantitation are recommended.
- Given the small intestinal wall changes, a malabsorption panel including serum cobalamin, folate, TLI and PLI is also recommended.





The information and recommendations provided are based on the images presented by the referring veterinarian. No evaluation can be communicated regarding pathology that was not visible in the image/video clips provided.

Thank you for this referral. If the clinical or image interpretation does not parallel your findings or if I can be of any further assistance please contact me.

Andrea Nicastro, DVM, Diplomate ACVIM (*Small Animal Internal Medicine*)
Andrea.nicastro@sonopath.com